HISTOLOGICAL & HISTOCHEMICAL STUDIES ON THE LACRIMAL GLANDS OF INDIAN BUFFALO (BOS-BUBALIS)

By

Chandra Mohan Gupta
B. V. Sc. & A. H
R. A. U. Research Fellow in Anatomy.

A THESIS

submitted to the faculty of Veterinary Science,
Rajendra Agricultural University, Bihar, Patna
in partial fulfilment of the requirements
for the degree of

MASTER OF SCIENCE (*Veterinary*).

POST-GRADUATE DEPARTMENT OF
ANATOMY

BIHAR VETERINARY COLLEGE, PATNA

1971

HISTOLOGICAL & HISTOCHEMICAL STUDIES ON THE LACRIMAL GLANDS OF INDIAN BUFFALO (BOS-BUBALIS)

By

Chandra Mohan Gupta
B. V. Sc. & A. H
R. A. U. Research Fellow in Anatomy.

A THESIS

submitted to the faculty of Veterinary Science,
Rajendra Agricultural University, Bihar, Patna
in partial fulfilment of the requirements
for the degree of

MASTER OF SCIENCE (Veterinary).

BIHAR VETERINARY COLLEGE
PATNA
6112
15.5.72

POST_GRADUATE DEPARTMENT OF
ANATOMY

BIHAR VETERINARY COLLEGE, PATNA

1971

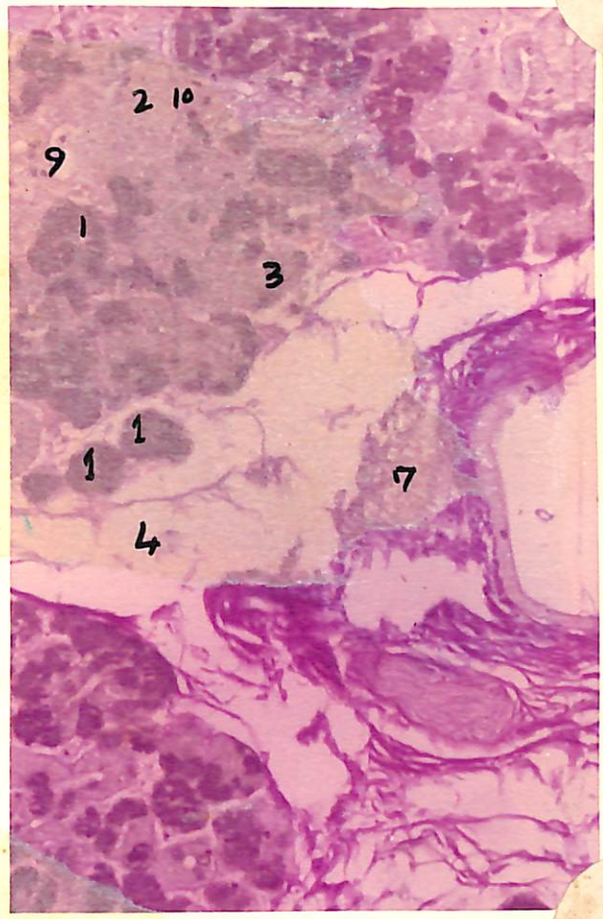

FRONTISPIECE

Dr. R.C.P.Yadava,
G.B.V.C. (Pat.), M.S., Ph.D. (Michigan, U.S.A.),
Director,
Livestock Research Station,
Rajendra Agricultural University,
Bihar, Patna.

a n d

Principal and Head of the Post-graduate
Department of Anatomy,
Bihar Veterinary College,
P a t n a.

P A T N A,

Dated the 25th March, 1972.

Certified that this thesis entitled " HISTOLOGICAL AND HISTOCHEMICAL STUDIES ON THE LACRIMAL GLANDS OF INDIAN BUFFALO (*Bos bubalis*) " has been prepared under my supervision and guidance by Dr. Chandra Mohan Gupta, a Rajendra Agricultural University Research Fellow in Anatomy. I have checked his observations and results from time to time during the period of this study. The thesis has been submitted to the Rajendra Agricultural University, Bihar, Patna for the degree of MASTER OF SCIENCE (VETERINARY) and it incorporates the results of his independent studies.

25/3/72

(R.C.P.YADAVA)

Rajendra Agricultural University, Bihar, M. Sc. (Vet.) Thesis, 1971

Dr. R.C.P.Yadava,
G.B.V.C. (Pat.), M.S., Ph.D. (Michigan, U.S.A.),
Director,
Livestock Research Station,
Rajendra Agricultural University,
Bihar, Patna.

a n d

Principal and Head of the Post-graduate
Department of Anatomy,
Bihar Veterinary College,
P a t n a.

P A T N A,

Dated the 25th March, 1972.

Certified that this thesis entitled " HISTOLOGICAL AND HISTOCHEMICAL STUDIES ON THE LACRIMAL GLANDS OF INDIAN BUFFALO (*Bos bubalis*) " has been prepared under my supervision and guidance by Dr. Chandra Mohan Gupta, a Rajendra Agricultural University Research Fellow in Anatomy. I have checked his observations and results from time to time during the period of this study. The thesis has been submitted to the Rajendra Agricultural University, Bihar, Patna for the degree of MASTER OF SCIENCE (VETERINARY) and it incorporates the results of his independent studies.

R.C.P. Yadava 25/3/72

(R.C.P.YADAVA)

Rajendra Agricultural University, Bihar, M. Sc. (Vet.) Thesis, 1971

Rajendra Agricultural University, Bihar, M. Sc. (Vet.) Thesis, 1971

D E D I C A T E D

To my revered Professor Dr.R.C.P.Yadava, G.B.V.C. (Pat.), M.S., Ph.D. (Michigan, U.S.A.) , Director, Livestock Research Station,Rajendra Agricultural University, Bihar, Patna, Principal and Head of the Department of Anatomy, Bihar Veterinary College, Patna whose deep devotion to teaching, insight in research and undaunted efforts for scientific advancements in the field of Veterinary Anatomy have been a constant source of inspiration and incentive.

Rajendra Agricultural University, Bihar, M. Sc. (Vet.) Thesis, 1971

I am extremely grateful to my parents who have constantly encouraged me during my academic pursuits and to Rajendra Agricultural University, Bihar, Patna for awarding fellowship in shape of financial assistance during the course of the present study.

(Author)

Rajendra Agricultural University, Bihar, M. Sc. (Vet.) Thesis, 1971

ABSTRACT

The present study included histological and histochemical details on the lacrimal glands of Indian buffalo with a brief account of its gross anatomy to provide an up-to-date description about it. Studies were made on left and right glands from twentyfour animals out of which eleven were adult females between nine to fourteen years of age while the rest thirteen were male calves varying from one to three years of age.

The gland was flattened, oval, lobulated mass, having deeply notched cranial border and some-what rounded medial angle, located within the periorbita between the dorso-lateral aspect of the eyeball and the supraorbital process of the frontal bone. The right gland was mostly heavier, more voluminous and had bigger dimensions as compared to the left in both young and old animals.

The average length, breadth, thickness, volume and weight of right gland of young animals were 7.09, 2.90, 0.66 cms, 5.50 cc and 5.46 gms respectively while the left were 6.68, 2.73, 0.67 cms, 4.91 cc and 5.01 gms respectively. The average length, breadth, thickness, volume and weight of the right gland of adult buffalo were 8.33, 4.19, 0.80 cms, 15.68 cc and 15.72 gms respectively while the left was 7.77, 3.85, 0.75 cms, 13.86 cc and 14.01 gms respectively.

It was a sero-mucous, compound tubulo-alveolar gland encapsulated by a thick connective tissue capsule (316 μ and 642 μ in young and adult) which was richly innervated and

vascularised.

The gland consisted of stroma and parenchyma. Stroma was composed of collagenous fibres, elastic fibres and some smooth muscle cells. Interlobular septa originated from the capsule and ramified into the parenchyma dividing the gland into numerous lobules. Intralobular septa was devoid of elastic fibres but contained reticular fibres besides fine collagenous fibres. Fat cells and lymphoid cells were noticed in the stroma. Presence of plasma cells in the interalveolar spaces and myoepithelial elements in the parenchyma were recorded.

Parenchyma was an agglomeration of alveoli and ducts which were of different shapes and sizes. Serous and mucous alveoli were noticed in different phases of secretion. Sometimes single alveolus was lined by serous and mucous epithelioid cells. The alveoli were lined by pyramidal, columnar or polyhedral cells having round, oval or flattened nuclei. Mitotic figures were noticed.

The granules of the secreting cells were of two types - coarse and fine. The concentration of these granules determined the shape and size of cells. Sometimes granules were found to be localised in the apical portion of the alveolar cells.

Interlobular and intralobular ducts were of different diameters, composed of single layer of cuboidal low columnar cells with indistinct border.

Micromeasurments of the thickness of the capsule, diameters of round and oval alveoli, height of the pyramidal cells, length and breadth of columnar cells of alveoli,

Rajendra Agricultural University, Bihar, M. Sc. (Vet.) Thesis, 1971

diameters of round nuclei and dimension of oval or flattened nuclei, average diameters of interlobular and intralobular ducts were recorded separately in young and adult animals. No goblet cells were observed in intralobular and interlobular duct except in one case when the excretory duct was completely lined by goblet cells.

The lacrimal gland of Indian buffalo was found to resemble the sub-maxillary salivary gland in most of the histological and histochemical details.

Histochemical observations were made by using special fixatives and applying different techniques for demonstration of PAS reaction, glycogen, acid mucopolysaccharides, proteins, protein-bound NH_2 group, tyrosin, lipids and fat, DNA, mucin, calcium and alkaline phosphatase. Obsvertation were made in respect of reactivity of the different tissues of the gland. Besides other components, the gland contained simple polysaccharides and complexes of carbohydrate in the form of mucopolysaccharides besides other complexes.

****

Rajendra Agricultural University, Bihar, M. Sc. (Vet.) Thesis, 1971

Rajendra Agricultural University, Bihar, M. Sc. (Vet.) Thesis, 1971

A C K N O W L E D G E M E N T S

The author feels immense pleasure and happiness to express extreme indebtedness and gratitude to his Professor, Dr. R.C.P.Yadava, G.B.V.C. (Pat.), M.S., Ph.D. (Michigan, U.S.A.), head of the Post-graduate Department of Anatomy and Principal, Bihar Veterinary College, Patna and Director, Livestock Research Station, Rajendra Agricultural University, Bihar, Patna for his erudite guidance, invaluable suggestions timely instructions and constant encouragements throughout the entire period of this investigation and for interpretations of the histological studies and for the correction of the manuscript untiringly.

Constant interest and help graciously extended by Dr. L.P.Singh, M.Sc.(Vet), Asstt. Professor of Anatomy, Bihar Veterinary College, Patna is acknowledged gratefully.

The author is thankful to Dr. A.K.Burnwal,M.Sc. (Vet), Dr. J.Prasad, B.V.Sc.&A.H., Asstt. Lecturers, Department of Anatomy, Bihar Veterinary College, Patna and to my colleagues Dr. K.S.Roy and Dr. P.K.Samanta for their constant help and encouragement throughout the course of the present study.

The author takes this opportunity to express his sincere thanks to Shri J.N.Prasad, Research Officer (Statistics), Livestock Research Station, Bihar, Patna and Shri Vijaya Kumar Sinha for their help in statistically evaluating the results.

Thanks are also due to my colleagues of Biological Products Section of Livestock Research Station, Bihar, Patna who kept me always motivated during the course of this study.

The author extends his most sincere thanks to Dr. Girish Chandra, M.V.Sc.(Vet), Assistant Professor, Department of Anatomy, The College of Veterinary Science and Animal Husbandry, Mathura and Shri Bhatia, tutor, Department of Clinical Pathology, All India Institute of Medical Sciences, New Delhi, for the supply of chemicals and for providing facilities to cut the frozen sections.

Thanks are also due to the staff of Art and Photography Section of Bihar Veterinary College, Patna for taking photographs.

The author would be failing in his duty if he does not express deep admiration for his wife ' Nirmal ' who showed great adjustibility during the course of the present work.

(C. M. GUPTA)

Rajendra Agricultural University, Bihar, M. Sc. (Vet.) Thesis, 1971

Special qualifications:

(a) Secured commendable position in the final B.V.Sc.&A.H. examination, 1964 and on the basis of merit, was posted to Livestock Research Station, Bihar, Patna.

(b) Selected for the award of merit cum poverty scholarship from Govt. of Bihar, during B.V.Sc.&A.H. course (from 1960 to 1964).

(c) Selected by the Rajendra Agricultural University, Bihar, Patna for the award of Junior Fellowship in Anatomy.

(d) Selected by Magadh University to represent in All India Youth Festival, 1962.

(e) Published few research papers in standard Indian and foreign Journals.

Member of:

(a) All India Society of Microbiologists.

(b) Bihar Veterinary Association.

(c) All India Veterinary Association

****

Rajendra Agricultural University, Bihar, M. Sc. (Vet.) Thesis, 1971

TABLE OF CONTENTS

	Page
INTRODUCTION	1
REVIEW OF LITERATURE	5
Gross Anatomy	5
Microscopic Anatomy	10
Capsule	10
Stroma	11
Interlobular septa	11
Intralobular septa	13
Parenchyma	14
Acini or Alveoli	14
Myo-epithelial cells	22
Ducts	23
Interlobular ducts	23
Intralobular ducts	25
Blood supply	26
Nerve supply	28
Histochemistry	29
Mucopolysaccharide and PAS reaction ...	29
Lipids and fat	32
Enzymes	33
Proteins	34
MATERIALS AND METHODS	35
Techniques	35
Gross	35
Microscopic	36
Staining	38
Measurments	40
RESULTS AND DISCUSSION	41
Gross Anatomy	41
Microscopic Anatomy	50
Capsule	50
Stroma	54
Interlobular septa	54
Intralobular septa	56

Rajendra Agricultural University, Bihar, M. Sc. (Vet.) Thesis, 1971

	Page
Plasma cell	58
Parenchyma	59
Acini or Alveoli	59
Myo-epithelial cell	69
Ducts	70
Interlobular ducts	70
Intralobular ducts	72
Blood supply	74
Nerve supply	77
Histochemistry	79
Periodic acid-schiff reaction (PAS) ...	80
Glycogen	82
Acid mucopolysaccharides (AMP) ...	82
Proteins	84
Protein-Bound NH_2 group and Tyrosin ...	86
Mucin	88
DNA and Calcium, Lipids and Fat ...	90
Enzyme	92
SUMMARY AND CONCLUSIONS	93
LITERATURE CITED	98

****

Rajendra Agricultural University, Bihar, M. Sc. (Vet.) Thesis, 1971

Rajendra Agricultural University, Bihar, M. Sc. (Vet.) Thesis, 1971

LIST OF TABLES

TABLE		Page
I.	Gross measurments of the gland of male buffaloes	47
II.	Gross measurments of the gland of female buffalo	48
III.	Micro-measurments of different structures of the gland in male buffalo	75
IV.	Micro-measurments of different structures of the gland in female buffalo ...	76
V.	Histochemical properties of Lacrimal gland	92a

LIST OF PLATES

PLATES		Page
	Frontispiece - Coloured microphotograph showing presence of acid mucopolysaccharides, parenchyma and stroma including duct, artery and nerve.	
I.	Right lacrimal gland of an young male buffalo *in situ*	42
II.	Lacrimal glands of an young male buffalo	44
III.	Lacrimal glands of an young male buffalo	44
IV.	Lacrimal glands of female adult buffalo	45
V.	The Capsule of lacrimal gland ...	51
VI.	Lobules of parenchyma of the gland ...	53
VII.	Elastic fibres in the capsule ...	55
VIII.	Interlobular septa of the gland ...	55
IX.	Intralobular septa of the gland showing the fine collagenous fibres ...	57
X.	Plasma cells in interalveolar spaces	57
XI.	Reticular fibres in the parenchyma ...	61
XII.	Mitotic figure in cells of the gland	63
XIII.	Solitary alveolus with round nuclei ...	65
XIV.	Coarse and fine granules and different shapes of cells lining the alveoli ...	65
XV.	Myo-epithelial cell present in the ducts	67
XVI.	Goblet cells lining the excretory duct	71
XVII.	Single layer of cuboidal cells lining the intralobular ducts	71
XVIII.	Mitochondria in the ductual and alveolar cells	73

Rajendra Agricultural University, Bihar, M. Sc. (Vet.) Thesis, 1971

XIX.	Cross-section of artery and nerve present in the capsule ...	78
XX.	PAS reaction in the parenchyma ...	81
XXI.	PAS positive goblet cells lining the excretory duct ...	81
XXII.	Glycogen present in alveoli ...	83
XXIII.	Acid mucopolysaccharides in the alveoli	83
XXIV.	Proteins present in alveoli ...	85
XXV.	Ninhydrin-schiff reaction in alveoli	85
XXVI.	Tyrosin by Millon's reaction ...	87
XXVII.	Mucin present in lacrimal gland ...	91
XXVIII.	DNA present in nuclei of duct, alveoli and connective tissue ...	87
XXIX.	Fat cells within interlobular spaces	89

Rajendra Agricultural University, Bihar, M. Sc. (Vet.) Thesis, 1971

INTRODUCTION

Although considerable achievements have been made during recent years in the field of Veterinary anatomy, histology and histochemistry in different species of animals, very little seems to have been done with respect to buffaloes (Bos bubalis). Obviously, the reason for this appears to be the restricted distribution of this species in different parts of the world.

The total population of buffaloes in the world was estimated by the statistics division of F.A.O. (1958) to be 95.4 million, of which, 45 millions were in India. They play an importnat role in the livestock industry of this country due to the fact that the average annual milk yield per buffalo is 1,100 lbs as against 413 lbs only by an Indian cow. Further, their milk is a better source for butter and ghee production as it is one and a half times richer than the cow's milk in fat content (Bhattacharya, 1954). Their capacity to convert feed stuff into milk is probably unequalled by any other species of farm animals (Hafez, 1952). They are better utilizer of coarse fodder and are able to convert cheap food into milk (Nair, 1951). A recent estimate put that 52 percent of total milk production is contributed by buffaloes only (Makhijani, 1962).

Thus, the foregoing facts make it evident that the importance of buffaloes in the field of dairy cannot be overlooked and necessitates detailed studies on all relevant aspects concerning them. These studies would help in better utilization of buffaloes and their products and would go a long way in augmenting the national economy of the country as well as the states.

Rajendra Agricultural University, Bihar, M. Sc. (Vet.) Thesis, 1971

INTRODUCTION

Although considerable achievements have been made during recent years in the field of Veterinary anatomy, histology and histochemistry in different species of animals, very little seems to have been done with respect to buffaloes (*Bos bubalis*). Obviously, the reason for this appears to be the restricted distribution of this species in different parts of the world.

The total population of buffaloes in the world was estimated by the statistics division of F.A.O. (1958) to be 95.4 million, of which, 45 millions were in India. They play an importnat role in the livestock industry of this country due to the fact that the average annual milk yield per buffalo is 1,100 lbs as against 413 lbs only by an Indian cow. Further, their milk is a better source for butter and ghee production as it is one and a half times richer than the cow's milk in fat content (Bhattacharya, 1954). Their capacity to convert feed stuff into milk is probably unequalled by any other species of farm animals (Hafez, 1952). They are better utilizer of coarse fodder and are able to convert cheap food into milk (Nair, 1951). A recent estimate put that 52 percent of total milk production is contributed by buffaloes only (Makhijani, 1962).

Thus, the foregoing facts make it evident that the importance of buffaloes in the field of dairy cannot be overlooked and necessitates detailed studies on all relevant aspects concerning them. These studies would help in better utilization of buffaloes and their products and would go a long way in augmenting the national economy of the country as well as the states.

Rajendra Agricultural University, Bihar, M. Sc. (Vet.) Thesis, 1971

There can be no denial of the fact that in the field of human surgery, remarkable and marvellous achievements like heart transplantation, kidney transplantation, neuro surgery and tissue grafting etc. have been made. Achievements have also been made in ophthalmic surgery like eye transplantation and corneal grafting etc. and the presumption that such achievements would be made in veterinary surgery also, is not far-fetched. The importance of veterinary ophthalmology is increasing rapidly which are evident from investigations of Catcott (1952), Magrane (1957,'59), Runin (1965), Robert (1968) and Mortada (1971). In consideration of these facts it can be mentioned that successful ophthalmic surgery requires sound and comprehensive knowledge of ocular anatomy. Detailed study on ocular anatomy seems to be necessary as it would provide a basis for better standing of ocular physiology, pathology, clinical medicine and ocular surgery.

The present investigation on lacrimal gland was undertaken as it is a main appendage of the eye. Standard text books on histology like Greep (1954), Ham (1957), Maximow and Bloom (1957), Trautmann and Fiebiger (1957) and Copenhaver (1964) described the histological and histochemical details of lacrimal gland in human and domesticated animals but no mention has been made in respect of buffaloes.

Occurrence of pathological conditions in the eye involve its accessory stuctures also. Not infrequently, dacryoadenitis, tuberculosis and neoplasmata such as carcinoma and sarcoma of the eye affects the accessory structures and impair their functions. Sclare and Luxton (1967) have given histopathological evidence for an association between chronic inflammatory lesions of the thyroid

Rajendra Agricultural University, Bihar, M. Sc. (Vet.) Thesis, 1971

and lacrimal glands.

The functional importance of tears - a secretion from lacrimal gland, is known to the medical world since long. Tears act as surface lubricant, protectant and cleansing fluid. Bernard (1965) pointed out that the secretion of this gland, in addition, serve to improve vision by filling irregularities on the corneal surface and yielding a smooth surface. Smythe (1958) and Prasad (1964) reported that the cornea which is a non-vascular structure, get nourishment from tears. Honssay (1951), Trautmann and Fiebger (1957), Finerty and Cowdry (1960) and Bernard (1965) described that the lacrimal fluid contains bactericidal enzymes - lysozyme and β-glucuronidase also which increases the protective nature of fluid by facilitating destruction of infectious organisms and hence it may therefore be considered a part of defence for body against infection.

Michail and Vancea (1931) found that extracts of the lacrimal gland cause a sharpe contraction of the smooth muscle of the blood vessels and the uterus and also stimulates heart rate. These properties suggest the probability of an internal secretion in these glands.

Bubyakina (1967) observed that the lacrimal glands of white rat played an important role in the regulation of calcium metabolism in calcified tissues.

There is considerable controversy regarding the presence or absence and full or partial development of the lacrimal gland in vertebrate and invertebrate. The nature of the gland (histologically) whether serous, mucous or mixed type is also a matter

Rajendra Agricultural University, Bihar, M. Sc. (Vet.) Thesis, 1971

of controversy in different domesticated animals.

Thus the importance of the gland and different nature of controversies have given impetus to explore an exciting area of research. Going through the literatures or research papers on histological and histochemical studies on the lacrimal glands of various animals the author could find two references, on buffalo, one by Singh (1962) and the other by Dass (1966) and these too were restricted to histological aspect only. Summing up the work of different scientists, it is evident that much headway still has to be made in this direction. Under the circumstances, it was thought to undertake a study, within the framework of existing facilities, on the histological and histochemical studies of lacrimal gland of Indian buffaloes, an aspect which has remained in oblivion since long.

The present study includes histological and histochemical details on the lacrimal gland of buffalo with a brief account of its gross anatomy. All the histological and histochemical studies have been made under light microscope. Due to nonavailability, the ultramicroscopic details have not been studied.

Nevertheless, the present investigation would contribute towards an up-to-date informations on the anatomy of the lacrimal gland of Indian buffalo with special reference to its histological and histochemical details. This study may provide a basis for an insight into ocular physiology, pathology, clinical medicine and recent ophthalmic surgery in general and would also be of interest to the students particularly in the field of anatomy.

Rajendra Agricultural University, Bihar, M. Sc. (Vet.) Thesis, 1971

REVIEW OF LITERATURE

GROSS ANATOMY

Chauveau (1891) described that the lacrimal gland of ox was a voluminous mass. He also mentioned that the lacrimal gland of horse was little developed and was formed of very small granules united by fine connective tissue.

Vaughan (1907) described the lacrimal gland to be of conglomerate type. He further stated that the colour of the lacrimal gland of horse was pale yellow and consisted of numerous lobules, composed of saculi and tubules held together by cellular tissue.

Wiedersheim (1907) demonstrated the absence of lacrimal gland in crocodiles, snakes and hatteria while in chelone it was found to be extremely large.

Nicolas (1914) gave an elaborate description of the lacrimal glands of horse, ox, pig and dog. According to him the gland of the horse measured about 6 to 7 cms by 2 cms. He also mentioned that in man some accessory glands were found in the conjunctival fornix.

Sundwall (1916) made a valuable contribution towards the structure of the lacrimal gland of ox. In his view, the gland in general was a flattened oval or almond shaped structure situated on the superior contour of the bulb, with an auricular appendage. Both surfaces of the gland possessed the charateristic glandular lobulations. The long axis of the glandular mass was measured on an average from 5 to 5.5 cms in length. The

Rajendra Agricultural University, Bihar, M. Sc. (Vet.) Thesis, 1971

average width of the mass was 3 cms. with an average thickness of 1 cm. The weight of the entire glandular mass in adult ox was from 6 to 7 gms.

Bradley (1923) described that the lacrimal gland of horse was under the cover of the zygomatic process of the frontal bone and over the dorso-lateral face of the eyeball. It was pale red in colour and distinctly lobulated.

Bradley (1927) observed the lacrimal gland of dog which was under the orbital band and over the dorsolateral part of the eyeball and was pale red in colour and distinctly lobulated.

Cowdry (1932) held the view that the lacrimal gland was a skin gland which supplied fluid to the cornea and lens.

Wood (1946) described the lacrimal gland of man which was disc shaped occupying lacrimal fossa on the medial side of the zygomatic process of the frontal bone. The anterior part of the gland was partly cut off by the lateral edge of the levator palpebrae and was called palpebral portion. The chief part was termed as orbital portion.

Bremer and Weatherford (1948) noted that the age determined the development of the lacrimal gland in man. At birth the gland was small and during childhood it was only one fourth to one third of the size observed in the adult and it again became smaller as the age advanced. They further observed that the lacrimal gland was larger in man than in woman. They also marked the yellowish pink colour of the glandular mass.

Rajendra Agricultural University, Bihar, M. Sc. (Vet.) Thesis, 1971

Greep (1954) described in human that the lacrimal gland was not sharply separated into two lobes by the lateral horn of the aponeurosis of the levator muscle.

Habel (1955) described that the broad dorsal end of the lacrimal gland of cow was located under the roof of the supraorbital process and a long tail which extended around the lateral margin of the orbit to a point below the lateral canthus.

Mariappa (1958) studying the anatomy of the foetal Indian elephant observed that the lacrimal gland was absent and its absence was compensated by the presence of a large harderian gland.

Prince et al. (1960) gave an elaborate description of the lacrimal gland of dog, cat, horse, ass, mule, cattle, sheep, pig, goat and rabbit. According to them the gland of dog was light red, slightly lobulated and was within the periorbita. The gland did not have a serrated edge as it was found in most of the other animals. The shape of the gland was like the tip of a spatula. The gland of the cat was small and quite thin and had equal width and length. The maximum thickness occurred centrally and tapered towards its periphery. They stated that the gland of rabbit extended within the whole of the lower orbital rim and the caudal end of the upper rim.

The lacrimal gland of the pig was relatively small, thin and triangular in outline. The surface was quite finely lobulated.

According to them the lacrimal gland of cattle was situated caudodorsally to the globe and its large

Rajendra Agricultural University, Bihar, M. Sc. (Vet.) Thesis, 1971

lobulated mass was divided in two parts. The average length of the gland was about 65 mm with a thickness of 10 mm and a greatest depth of about 36 mm.

Last (1961) described that fishes had no lacrimal gland, the eye being bathed in surrounding media. In tortoise there was one gland for both the eyes. In serpent the lacrimal gland was absent.

It was interesting to note that the lacrimal and harder's gland developed from a single primordium in the lower lid. A growth of the medial portion produced harder's gland, which remained in its original position, while the lacrimal gland tend to move towards the outer canthus and then to the upper lid. Thus the rudiment in the lower lid of amphibia was really the rudiment of both lacrimal and harder's glands. He also mentioned that the tortoise had large lacrimal gland situated posteriorly. This was due to the fact that this aquatic animal crossed dry sandy tracts to lay eggs and to keep the eyes normally moist. In whale, the secretion of the lacrimal gland was fatty.

Hyman (1962) mentioned that the lacrimal gland of turtle was much larger and was extended over the posterior and ventral surfaces of the eyeball.

Sisson and Grossman (1962) stated that the lacrimal gland of horse measured about two inches transversely and an inch or more in the sagittal direction. In ox, it was thick and distinctly lobulated and was more or less clearly divided into a thick upper and thinner lower part (Glandula lacrimalis dorsalis, ventralis).

Rajendra Agricultural University, Bihar, M. Sc. (Vet.) Thesis, 1971

Prasad (1964) studied that the tortoise had much large lacrimal gland situated on the posteroventral surface of the eyeball. According to him this gland was vestigial or absent in reptiles, amphibians and birds but in mammals it was well developed.

Raghavan (1964) described that the lacrimal gland of ox lodged in a depression on the under surface of the supraorbital process and between the latter and the supero-external aspect of the eyeball.

Kharitonova (1964) observed the lacrimal glands of human foetuses which were differentiated into superior and inferior sagements. He also found auxillary lacrimal glands in four months foetuses.

Dass (1966) studied the lacrimal gland in amphibians, avians, horse, ox, buffalo, goat and dog. The gland was found to be situated at the dorsolateral aspect of the eyeball between the eyeball and the roof of the orbit and extended on to the deeper aspect of the upper lid. The colour of the gland was deep red in the ox and buffalo. The average length and breadth of the gland in bufflo was 37.25 mms and 22.00 mms respectively.

Sinha and Calhoun (1966) compared the lacrimal glands of sheep and goat which were similar in structure. They found to be flattened, oval and lobulated mass within the periorbita. The average weight of the gland of sheep was 1.64 gms and was 2.8 cms by 2.0 cms by 0.5 cm respectively in length, breadth and thickness. He also observed two surfaces, two boarders and two extremities.

Rajendra Agricultural University, Bihar, M. Sc. (Vet.) Thesis, 1971

Micheluzzi (1967) made an observation on accessory lacrimal glands of rabbit.

Diesem (1968) studied the gross anatomical structure of equine and bovine lacrimal glands showing morphological relations and variations. The gland of ox was 6.00 to 7.00 cms long and 3.5 cms at its greatest width and 10 mms thick. The gland had thick dorsal portion and a thin lateral portion.

Walker (1970) described that the lacrimal gland of cat and rabbit were dark glandular mass that layed on the postero-dorsal surface of the eyeball.

MICROSCOPIC ANATOMY

CAPSULE

Klein and Noblesmith (1880) described that the human lacrimal gland corresponded in structures to the true salivary gland. The gland was encapsulated by a band of connective tissue fibres.

Chauveau (1891) described that the lacrimal gland of horse was an aggregation of very small granules which were united by fine connective tissue.

Sundwall (1916) found that the capsule of lacrimal gland of ox was fused with the general areolar and adipose tissues of the orbit. Strands of tough connective tissue fibres, derived from the periorbital fascia, were also intimately fused with the capsule. He pointed out that the portion of capsule covering the convex surface of the gland was conspicuously thin but the interlobular septa which originated from this area

Rajendra Agricultural University, Bihar, M. Sc. (Vet.) Thesis, 1971

was appreciably dense. The thickest portion of the capsule was found on the concave surface. Both collagenous and elastic fibres were present in abundance. Numerous globules of fat were seen either singly or in groups irregularly distributed throughout.

Bremer and Weatherford (1948) described that the human lacrimal gland was surrounded by a loose connective tissue capsule. He also reported the presence of smooth muscle cells besides collagenic and elastic fibres.

Singh (1962) studied that the lacrimal gland of buffalo was closely enveloped by a connective tissue capsule which contained a mesh of collagenic fibres, elastic fibres and some smooth muscle cells.

Sinha and Calhoun (1966) found that the lacrimal gland of sheep was surrounded by a connective tissue sheath. They also noted that the capsule was ventrally related to a smooth muscle band.

STROMA

The Interlobular Septa - Sundwall (1916) observed that the interlobular septa was derived from the capsule and divided the gland into numerous lobules of irregular shape and size. Secondary septa originated from two or three large primary septa which entered the various lobules and formed the supporting structures. It also surrounded the various vessels, nerves and ducts which were in close proximity to each other. He, however, did not find any accumulation of lymphoid cells in the septa in either or old bovidae. The septa were composed chiefly of collagenic fibres.

Rajendra Agricultural University, Bihar, M. Sc. (Vet.) Thesis, 1971

Elastic fibres were present to some extent. He also noted cells suggestive of smooth muscle cells. Occasionally fat cells were observed. Numerous plasma cells were seen in both interlobular and intralobular tissue.

Bremer and Weatherford (1948) described that the septa originated from loose connective tissue capsule. The interlobular septa were composed of collagenic fibres, elastic fibres and smooth muscle cells. Lymphatic tissue was present to a varying extent in the septa which was absent at birth, sparse at puberty and was abundant in the adult.

Last (1961) described that the interlobular connective tissue septa of the lacrimal gland of human was hardly present in young but increased with advancing age. Aggregation of plasma cells and lymphocytes were also observed.

Prince et al. (1960) described that the connective tissue septa of lacrimal gland of cattle, carried capillaries and sometimes small vessels. An occasional presence of macrophage and an odd pigment cell were observed. Interlobular tissue of lacrimal gland in cat was relatively of sparse stroma of connective tissue in which some fat cells were also seen. The rabbit's lacrimal gland, like its harder's gland had only very loose connective tissue septa, which were so fine that they were barely visible in standard sections. Goat's gland had very fragile and less amount of interlobular septa which contained many interlobular ducts. Some large connective tissue septa were found in the lacrimal gland of pig.

Singh (1962) found that lacrimal gland of

Rajendra Agricultural University, Bihar, M. Sc. (Vet.) Thesis, 1971

buffalo had connective tissue capsule which extended numerous septa at irregular intervals to divide the gland into lobes and lobules. These septa contained fine collagenous fibres, delicate elastic fibres and few smooth muscle cells.

Copenhaver (1964) described that the human lacrimal gland had stroma which consisted of loose connective tissue blending peripherally with the surrounding structures. In the adult, considerable lymphoid tissue was observed in the stroma.

Sinha and Calhoun (1966) came to the conclusion that the capsule of lacrimal gland of sheep sent septas into the substance of the gland, dividing it into lobules. These septa were composed of dense collagenic and fine elastic fibres and contained smooth muscle fibres, blood vessels, nerves and ducts. The interlobular septa of goat's lacrimal glands were comparatively thin and contained many plasma cells.

John and Richard (1966) observed that dense sheath of interlobular connective tissue separated the lobules of lacrimal gland in Marine Turtles.

Mariano (1967) and Arey (1968) described the stroma of human lacrimal gland which contained interlobular connective tissue in which lymphoid and other cells were situated.

Intralobular Septa - Sundwall (1916) observed that the intralobular connective tissue septa were composed of collagen and reticular fibres. He noted the presence of elastic fibres only in relation with the blood vessels. Repeated examinations of tissue fixed in various fixatives and stained both by Weigert's

Rajendra Agricultural University, Bihar, M. Sc. (Vet.) Thesis, 1971

and the Unna-Taenzer method, he did not find the presence of elastic fibres surrounding the acini.

Numerous plasma cells were seen in both the interlobular and intralobular tissue, principally around the ducts and between the acini. These cells were typical in appearance - round, more or less eccentric nuclei with peripheral arrangement of the chromatin and fine basophilic granules in the protoplasm. These cells were differently shaped - some spheroidal, others elongated and irregular in outline.

Singh (1962) observed certain epitheloid cells which were seen in groups in the spaces between the tubules and in the interalveolar connective tissue. These cells were small cuboidal in shape and were quite distinct from the glandular cells. Their nuclei were small, spherical and centrally placed. The cytoplasm and the nucleus of such cells had taken characteristic stain with haematoxylin and eosin . He also noted numerous blood capillaries.

Sinha and Calhoun (1966) mentioned the presence of plasma cells, fat cells and lymphocytes in the intralobular septa and in the interalveolar spaces in the lacrimal gland of sheep.

Bolden (1967) observed that the lacrimal gland of male Wister rats had some mast cell aggregation in the stroma of the gland.

PARENCHYMA

Acini or Alveoli - Klein and Noblesmith (1880) described

Rajendra Agricultural University, Bihar, M. Sc. (Vet.) Thesis, 1971

that the lacrimal gland of human corresponded in structure to the true salivary gland. He pointed out that the lining cells were well defined, conical or cylindrical in resting alveoli while during secretion the cells were smaller, very opaque and granular with indistinct outline.

Nicolas (1914) and Sisson and Grossman (1962) mentioned that the gland of the pig was of mucous type.

Dawson (1948), Jordan (1952), Nonidez and Windle (1953), Maximow and Bloom (1958), Wolff (1958), Carleton and Short (1960) and Ham and Leason (1961) described that the lacrimal gland were different from the salivary gland by large lumina of the acini. The secreting tubules were of two kinds: (a) with tall and narrow glandular cells and (b) with low columnar or cuboidal cells. The tall cells became shorter after discharge of the secretion. The lacrimal gland also differed from the salivary gland due to the presence of myoepithelial elements.

Bremer and Weatherford (1948), Greep (1954), Ham (1968), Finerty and Cowdry (1960) and Arey (1968) described that the human lacrimal gland was a compound serous tubulo-alveolar gland.

Bremer and Weatherford (1948) further described that the secreting epithelium was simple columnar and the height of the cells were corresponding to different functional stages. During rest, the cytoplasm became filled with large, clear spherical bodies resembling vacuoles but after stimulation these were discharged leaving the cells shrunken dark and finely granular. Mitochondria were abundant. Epithelium were rested on reti-

Rajendra Agricultural University, Bihar, M. Sc. (Vet.) Thesis, 1971

cular basement membrane.

Roland (1958) stated that there was a great discrepancy of nuclear size of the acini of male albino rats, which employed a range from deploid to a highly polypoid condition and nuclei were found to occur in pairs of similar size. As the age advanced, there was a transformation of main parts of the gland with reduction of nuclear and cell size. There was a characteristic sparse deposit of "Yellow pigment" in both glandular and stromal cells which were not seen in male albinos.

Scott and Pease (1959) observed that the acinar cells of the lacrimal gland of rats were characterised by the presence of both light and dark granules which represented an admixture of mucous and zymogenic secretory granules. He claimed that such type of admixture of secretion granules were not observed in any of the salivary gland.

Prince et al. (1960) gave an elaborate comparative description of this gland in animals. It was tubulo-alveolar serous gland in cat, horse, cattle, pig and rabbit, mixed in dog and sheep and compound tubulo-alveolar mucous in the goat.

Omulecka (1962) observed the behaviour of the Golgi apparatus in cytoplasm of the rabbit's lacrimal gland at various periods of glandular activity by means of the Aoyama method. A decomposition of the Golgi-reticular-net-work was observed after fall of the lacrimation below the physiological level of the gland.

Ithikawa and Nakijima (1962) investigated the fine structure of lacrimal gland of the rat and its changes

Rajendra Agricultural University, Bihar, M. Sc. (Vet.) Thesis, 1971

according to the secretory cycles by light and electron microscopy. The acinar cell contained only one kind of secretory granules surrounded by a thin membrane originating from the Golgi membrane. The intercellular boundaries were characterised by well developed complicated interdigitation. The secretion granules were discharged into the acinus lumen in the typical manner of merocrine secretion.

Singh (1962) noted the presence of mucous cells in the lacrimal gland of buffalo. The gland was aporcine in its mode of secretion. It was compound tubulo-alveolar and the acinar cells and the cells of secretory tubules rested on a fine basement membrane.

Ping (1964) studied the ultramicroscopic structure of guineapig's lacrimal gland. The oval nucleus of the acinus cell was located in the basal region of the cells. The secretion granules were of mucous type, being PAS and mucicaramine positive. Well developed Golgi apparatus was located in the middle of the supranuclear cytoplasm. Small secretion granules were closely associated with Golgi elements. The surface of the acinus cells usually sent microvilli into both the central lumen of the acinus and the intercellular canaliculi.

Omulecka and Okulist (1964) noted the behaviour of the rabbit lacrimal gland cells after pilocarpine administration. The cells changed in size, nuclei were bigger and translocated to the cellular pole.

Babaeva (1966) observed the post-natal development of the size of the lobules, acini, nuclei and the

Rajendra Agricultural University, Bihar, M. Sc. (Vet.) Thesis, 1971

mitotic activity of the secretory cells of the external orbital lacrimal gland in white rats. Up to the age of 40 days the increase in the weight of the gland was due to the formation of new acini. After 40 days the formation of new terminal portion occurred.

Sinha and Calhoun (1966) found that the gland of goat was compound tubulo-alveolar and was mixed in nature. Lobules varied greatly in size.

Abel Jr. and Ellis (1966) studied detailed structure of the gland of turtle using differnt fixatives like Zenker, Bouins or Helly's fluid besides 10 percent formalin. Three distinct cell types were identified among the cells lining the tubules. At the blind ends of the tubule were small terminal cells with scanty cytoplasm and a high affinity for basic dyes. Most of the remainder of each tubule was paved with principal secretory cells. These were the small near the periphery of the tubule but they gradually increased in size as they approached the central canals. The principal and the peripheral cells contained a large central nucleus with a single nucleolus, bits of hetrochromatin and a homogenous karyoplasm. The third cell type of the tubule was morphologically unrelated to the secretory cells.

Bolden (1967) observed that maturation of the parenchyma of the male wister rat's lacrimal gland occurred at approximately 15 days after birth. The gland was composed of three basic elements acini 82 percent, ducts 3 percent and 15 percent non-secretory tissue.

Rajendra Agricultural University, Bihar, M.Sc. (Vet.) Thesis, 1971

Luciano (1967) observed sexual di-morphism in rat's lacrimal gland. The female gland was characterised by small acini with narrow lumen, easily visible cell borders with many intercellular channels and large cytoplasmic vacuoles, possibly filled with pigment containing fatty substances. The male gland was characterised by large acini with somewhat wider lumen, less distinct cell borders, striking nuclear polymorphism with inclusion of cytoplasmic material in the nuclei, specialised structure of the Golgi-fields and basal vacuoles.

Kessing (1967) found that the accessory lacrimal glands of human foetuses and new borns had both the serous cells as well as mucous cells. The mucous appearance during embrogenesis was due to the presence of Goblet cells which were found right from the earliest developmental stage.

Kuhnel (1968 a) performed a comparative histological, histochemical and electromicroscopical investigation of lacrimal gland of adult rabbits and cats of both sexes which revealed a distinct difference of the glandular acini.

Kuhnel (1968 b) found that the epithelium of goat's lacrimal gland consisted of dark and light cells on the basis of PAS technique. Short microvilli were projected into the lumen.

Kuhnel (1968 c) noted that the gland of sheep was a branched tubulo-acinar gland of serous type. By light microscopy two different cell types could be distiguished according to their staining reactions. Acinar and tubular cells were rich in alcian blue positive materials.

Rajendra Agricultural University, Bihar, M. Sc. (Vet.) Thesis, 1971

Kuhnel (1968 d) studied the lacrimal gland of cattle which was a branched tubulo-cinar gland of seromucous type. The terminal secreting acinar cells were composed of flat low cuboidal epithelium. The fine structure of the acinar cells were characterised by an accumulation of secretion containing vacuoles in the middle and epical cytoplasm of the cell. The secretion granules being PAS positive in the light microscopy were often bounded by ill preserved membranes. Their internal structures were electronlucent or electron dense, sometimes characterised by a flocculant graininess.

Kuhnel (1968 e) found that the staining of paraffin sections in astrablue, alcian blue, rutheniun red and PAS revealed the presence of large positive granules in the lacrimal gland of dog. The mitochondria were numerous, elongated and were oriented in the long axis of the columnar cells. The base of the cells was highly clefted by deep infoldings of the plasma membrane.

Kuhnel (1968 f) observed two types of secretory cells:(a) 'K' cells with large granules and (b) 'G' cells containing a few very small granules in human lacrimal gland. The granules of G cells were positive for alcian blue, astra blue, rutherian red and toluidene blue. Electromicroscopical study had demonstrated further dissimilarities between K cells and G cells: If the vertical axis of the acinar cell was divided into four equal zones, the basal zone always contained most of the rough surfaced endoplasmic reticulum. The nucleus was in the next zone and the apical half of the cell was filled with secretory mater-

Rajendra Agricultural University, Bihar, M. Sc. (Vet.) Thesis, 1971

ial of varying density.

Ruskell (1968) observed serous and mucous secretion granules in acini of the lacrimal gland of monkey.

Bloom and Fawcett (1968) described that the human lacrimal gland was tubulo-alveolar type. Its terminal portion was provided with a relatively large lumen and with irregular, saccular outpocketings. The lining epithelium of acini were narrow columnar and contained fat droplets.

Burock (1969) identified two different cell types in the acini of the lacrimal gland gland of cat: one type contained both acid and neutral mucosubstances and other types producing only neutral mucosubstances.

Hahn (1969) studied a histo-physiological importance of rat lacrimal gland by injecting cyproterone acetate. His investigation suggested the possibility that this gland might be playing a part in the sexual behaviour of the rats.

Egeberg and Jensen (1969) observed that human lacrimal glandular cells were quantitatively different regarding contents of organelles and granules but on the basis of morphological criteria it was not possible to demonstrate the presence of more than one type of glandular cells.

Nikiforovae and Colakov (1969) transplanted a amll piece of extra orbital lacrimal gland from albino rats into the peritoneal cavity of same species. From the third day on, the glandular structure was lost and the epithelium moved towards growing in stratified layers with the characteristic anisomorphism.

Rajendra Agricultural University, Bihar, M. Sc. (Vet.) Thesis, 1971

Rajendra Agricultural University, Bihar, M. Sc. (Vet.) Thesis, 1971

Myo-epithelial cell - Sundwall (1916) observed some structural tissue, surrounding the terminal tubules or acini of gland in general, which were composed of several elements such as fixed connective tissue cells and he called them "Korbzellen" or basket cells. They were more prominent in lacrimal glands of younger animals. He regarded them as of connective tissue origin rather than contractile musculo-epithelium.

Bremer and Weatherford (1948) described that there were some stellate flattened elements between secreting glandular cells and reticular tissue basement membrane. He called these stellate elements as "Basket cells". Some histologists interpreted the basket cells as ' myo-epithelial' , which others regarded as a species of connective tissue cells.

Scott and Pease (1959) observed myoepithelial cells having a limited distribution in the gland of rat being confined to the intercalated ducts of lacrimal gland. They were absent in the lacrimal alveoli.

Roland (1960) observed in detail the structure of myoepithelial cells in rat. In light microscopic preparation the cells appeared stellate with a central portion containing the nucleus and numerous processes which were passing around and between secretory cells. Thus they appeared to embrace the acini in a basket of finger-like cytoplasmic processes. The nuclei were oval and elongated and parallel to the basement membrane. The nuclear surface was mostly regular. The nuclear membrane was double and occasionally exibited pores. The cytoplasm was finely particulate, pale and organelles were concentrated near the

nucleus. Electromicrographs showed that the basement membrane was separated from the plasma membrane of the myoepithelial cell by a narrow interval containing a pale, amorphous material.

He thought these cells to be contractile elements which had an important role in the expulsion of secretion.

Ithikawa and Nakijima (1962) noted that the myoepithelial cells were recognised only around the terminal portion of the rat's lacrimal gland as well as around such ducts which were lined with epithelial cells containing secretory granules.

Ping (1964) observed myoepithelial cells in lacrimal gland of guineapigs which contained fibrils and small vesicles. Electron opacity of these cells were much denser than that of acinar cells.

Abel Jr. and Ellis (1966) had not detected myoepithelial elements in marine turtle lacrimal gland with either the light or electron microscope.

Mariano (1967), Ham (1968), Bloom and Fawcett (1968) and Egeberg and Jenson (1969) described the presence of myoepithelial cells or basket cells in human lacrimal gland.

Kuhnel (1968 d) located the myoepithelial cells in lacrimal gland of cattle between the base of the epithelial cells and basement membrane.

DUCTS

Inter-lobular ducts - Sundwall (1916) observed that the

Rajendra Agricultural University, Bihar, M. Sc. (Vet.) Thesis, 1971

primary ducts of lacrimalgland of ox ramified to form the interlobular ducts which further subdivided to form the intralobular ducts. The lumina of these interlobular ducts were wide and were about one-half to one-fourth the diameter of those of the main ducts. The epithelial wall was from 12 μ to 18 μ in thickness. It was composed of from one to two layers of cells which were cylindrical in from. Study of these cells under oil immersion lens showed the cytoplasm to be very finely granular. The nuclei were round or oval. Cell boundaries were indefinite. He also observed goblet cells in the primary ducts. There was a marked decrease of elastic fibres surrounding the ducts in stroma.

Scott and Pease (1959) observed that the excretory ducts of lacrimal gland of rat was devoid of any mucous cell. Microvilli were present lining the lumen but Myoepithelial cells were absent.

Finerty and Cowdry (1960) described that the strongly acidophilic secretory ducts were absent in lacrimal gland of man.

Prince et al. (1960) described that in sheep the interlobular ducts were lined with the usual single layer of cuboidal epithelium. Ducts were heavily surrounded by coarse connective tissue. Comparatively interlobular ducts were more numerous than other animals.

Ithikawa and Nakijima (1962) found dense secretory granules in the epithelial cells of small and large ducts in lacrimal gland of rat.

Singh (1962) observed that the interlobular

Rajendra Agricultural University, Bihar, M. Sc. (Vet.) Thesis, 1971

ducts were lined by cuboidal cells which had rounded or oval centrally placed nuclei.

Ping (1964) observed in guineapigs that cytoplasm of the epithelial cells of the ducts were denser than that of the acinus cells. Mucous granules were present in some of the duct cells.

Sinha (1965) found that in sheep the lobular and interlobular ducts were lined with stratified cuboidal epithelium containing a few goblet cells.

Luciano (1967) noted the presence of secreting granules in the ducts of the lacrimal gland of rat besides the common cytoplasmic components.

Kuhnel (1968 d) found that the interlobular ducts in cattle were lined by a single layer of columnar epithelium. He also found goblet cells in the duct.

Burock (1969) observed the lacrimal gland of cat in which stratified ducts were not observed but goblet cells were present.

Intralobular ducts and Intercalated ducts -

Sundwall (1916) observing the lacrimal gland of ox said that the intralobular ducts had reduction in the cells of the outer layer so that the smaller ducts appeared to possess a single layer of cells. The nuclei were elliptical. Occasionally double layer of lining of cells were also observed. The structure of the wall was made up almost entirely of collagen fibres with occasionally few elastic fibres. He did not find secretory granules or secretion capillaries in these ducts but intercalary ducts were

Rajendra Agricultural University, Bihar, M. Sc. (Vet.) Thesis, 1971

positive for secretion granules.

Scott and Pease (1959) differentiated the intercalated duct of the gland with other part of the duct-system due to the presence of myoepithelial cells. Small numbers of zymogen granules and RNA granules were present. The intercellular wall was folded to produce interdigitations. Microvilli were present lining the ducts.

Singh (1962) observed that the intralobular ducts were large and were lined with a regular row of cuboidal cells with oval nuclei arranged transversely to the duct.

Sinha and Calhoun (1966) observed in sheep that the samll intercalated and intralveolar ducts were lined with a single layer of cuboidal epithelium.

Bloom and Fawcett (1968) described in man that the smallest intralobular ducts were lined with a layer of low columnar cells and has few myoepithelial cells.

BLOOD SUPPLY

Bremer and Weatherford (1948) described in human that the chief blood supply to the lacrimal gland was through the lacrimal branch of the ophthalmic artery. Venules united within the interalveolar septa to form a lacrimal vein which drained into ophthalmic vein.

Rajya (1956) observed in a buffalo calf that the lacrimal gland received blood supply through the lacrimal artery which was a branch of ophthalmic artery.

SuarezNunez and Tolosa (1964) observed

Rajendra Agricultural University, Bihar, M. Sc. (Vet.) Thesis, 1971

microscopically that the blood supply of the lacrimal gland in human was made by lacrimal artery which first divided into external and internal branches. The former divided again into two branches, whereas the latter reached the innermost part of the gland and there formed an arterial network.

Perfumo and Sperati (1966) noted the presence of myoepithelioid cells in the walls of small arteries and in the anastomotic tracts of lacrimal gland.

Abel Jr. and Ellis (1966) observed in lacrimal gland that smaller arteries branched from the larger ones, penetrated the lobules through broad sheath of intralobular connective tissue and sent arterioles which after further ramification formed a rich capillary bed. These capillaries further entered the venous sinuses that fused together and drained into larger interlobular veins.

Carella (1968) presented a comparative study of microvascular architecture of lacrimal gland in cat, dog, goat, sheep and rabbit. The study of the fine microanatomy of arteriols, venules and capillaries and their behaviour at the level of connective tissue, parenchymal and ductural tissue, prompted some reflections regarding their functions.

Carella and Castelli (1968) observed the micromorphologic character of fine vascular system of lacrimal gland in human foetuses.

Vetter (1969) demonstrated the blood vessels and capillaries of the lacrimal gland in rat, by means of the reaction of their endothelium to alkaline phosphatase.

Rajendra Agricultural University, Bihar, M. Sc. (Vet.) Thesis, 1971

NERVE SUPPLY

Whitnall (1921) described in human that the gland was innervated by 5th and 8th cranial and by sympathetic nerve fibres.

Bremer and Weatherford (1948) and Houssay (1951) described in human that lacrimal gland was innervated by the lacrimal, facial and sympathetic nerves. The fibres ended in the gland substance as fine non-medullated ramifications between the alveolar cells and around the excretory ductuales and the blood vessels.

Kato (1958) observed the pattern of nerve fibre distribution within the lacrimal gland of human which were medullated and non-medullated fibres.

Scott and Pease (1959) found the nerve terminals between the basement membrane and the epithelial cells in lacrimal alveoli.

Ehinger (1966) observed in cat that every secretory cell of the lacrimal gland was reached by an adrenergic nerve fibres.

Ruskell (1967) investigated the ultramicroscopical structures of the perivascular axon terminals of the lacrimal glands of monkeys. Both sympathetic and parasympathetic axon terminals were noted between the adventitia and media. Capillaries and venules were sparsely innervated.

Ruskell (1968) observed in monkeys that nearly all lacrimal gland nerve fibres were non-myelinated. Terminal axons were present within the interstices and between serous

Rajendra Agricultural University, Bihar, M. Sc. (Vet.) Thesis, 1971

acinus cells but not between mucous acinus cells.

Ruskell (1971) observed the nerve supply of lacrimal gland in different species of monkeys. Examinations of the fine nerves showed that they were largely composed of non--myelinated nerve fibre bundles.

HISTOCHEMISTRY

PAS reactions and Mucopolysaccharides - Spicer and Duvenci (1964) observed the histochemical characteristics of mucopolysaccharides in exorbital lacrimal glands in mouse, rat and syrian hamster by applying a battery of histochemical techniques. In mouse, the mucopolysaccharide was marked with weak alcian blue affinity and PAS reactivity. The secretion of exorbital gland in the rat stained blue with alcian blue - PAS and aldehydefuchsin--blue stains. The exorbital lacrimal gland in the syrian hamster formed an intensely PAS - reactive mucopolysaccharide with very little or no basophilia except for faint blue staining by the aldehyde-fuchsin-alcian-blue procedure. The strong periodic acid--phenylhydrazine-schiff reactivity of this mucosubstance afforded the only histochemical evidence which suggested the presence of acid group of mucopolysaccharides.

Ping (1964) noted in guineapig's lacrimal gland that the secretory granules of alveoli were reactive with periodic acid-schiff procedure.

Abel Jr. and Ellis (1966) found in lacrimal gland of turtle the intercellular channels between the lateral margins of the principal cells intensely PAS positive. They

Rajendra Agricultural University, Bihar, M. Sc. (Vet.) Thesis, 1971

They exhibited a variable degree of metachromasia. Preipheral cells were more positive for glycogen. Abundant mucopolysaccharides in tubular cells were confirmed by the presence of bright blue green colour with alcian blue stain and intense pink after the PAS reaction even when the secretions were treated with diastase, saliva or hyaluronidase. The besement membrane was PAS positive but did not stain metachromatically by toluidine blue technique.

Krestinskaya (1966) observed the characteristic feature of lacrimal gland in white rats histochemically which revealed the presence of acid mucopolysaccharides around the segements.

Kuhnel (1968 a) demonstrated the presence of glycogen and mucopolysaccharides in the lacrimal gland of rabbit and cat.

Kuhnel (1968 b) differentiated the epithelium of the serous alveoli of lacrimal gland in goat as light and dark cells by periodic acid-schiff reaction. The dark cells were rich in PAS positive materials.

Kuhnel (1968 c) noted the PAS reactive granules in the acinar cells of the lacrimal gland in sheep.

Kuhnel (1968 d) observed in cattle that all the glandular cells contained PAS positive granules (neutral mucopolysaccharides). Some of these cells were rich in alcian blue and astra blue reactive materials (acid mucopolysaccharides).

Kuhnel (1968 e) observed the acid mucopolysaccharides in lacrimal gland of dog by alcian blue, ruthenium red and periodic acid-schiff technique.

Rajendra Agricultural University, Bihar, M. Sc. (Vet.) Thesis, 1971

Kuhnel (1968 f) studied in human that the acinar cells were characterised by a basal dense basophilia and the PAS positive materials were in the apical two-third of the cytoplasm.

Kriesten (1968) observed in white mouse that the epithelium of the ducts of the lacrimal gland mainly contained neutral mucopolysaccharides. In acini, the PAS positive substance was weak. Sulphated mucopolysaccharides were absent in the duct epithelial cells.

Kronman et al. (1968) observed in female golden hamster that the PAS reaction was intense in the sublingual gland, strong in the zygomatic gland and it was faint in the lacrimal gland. Acid mucopolysaccharides were negative in the lacrimal gland while they were present in the sublingual gland.

Jensen et al. (1969) observed that the mucosubstances of the acini of the human lacrimal gland by applying a battery of histochemical methods which were found to be orthochromatic, strongly PAS (periodic acid-schiff) positive and strongly alcianophilic. A high amount of siliac acid and small amounts of sulphated mucopolysaccharides were indicated.

Burock (1969) in cat identified two different cell types in the acini of lacrimal gland. One type was containing both acid and neutral mucosubstances and other was producing only neutral mucosubstances. Glycogen was absent. The apical portion of the cells lining the intraglandular ducts was characterised by a positive PAS reaction.

Rajendra Agricultural University, Bihar, M. Sc. (Vet.) Thesis, 1971

Lipids and fat - Sundwall (1916) observed in ox that the adipose tissue of the orbit were fused with the capsule of the lacrimal gland. The larger septa also contained fat cells.

Whitnall (1921), Bremer and Wetherford (1948), Arey (1968) and Ham (1969) described that in human the acinar or secreting cells of the lacrimal gland contained fat droplets or lipids.

Trautmann and Fiebiger (1957) described the presence of fat droplets in all domestic animals.

Greep (1954) described some fat cells in the stroma of the human lacrimal gland.

Prince et al. (1960) described that in dog and cat the interlobular septa of the gland were containing fat cells. In horse, the gland was invaded by small groups of fat cells occasionally. In pig, the gland was surrounded and invaded by fat cells.

Sinha and Calhoun (1966) found in sheep and goat that the frozen sections stained with Sudan balck B were giving a very weak reaction for lipids. Scattered, fine, black globules appeared in the cytoplasm of the glandular cells.

Luciano (1967) noted the large cytoplasmic vacuoles possibly filled with pigment containing fatty substance in the acinar cells of the rat lacrimal gland.

Kriesten (1968) observed in white mouse the presence of fat droplets in both acinar and tubular epithelium but in contrast to the acinar cells, the tubular cells did not show any unsaturated fatty acids.

Rajendra Agricultural University, Bihar, M. Sc. (Vet.) Thesis, 1971

Burock (1969) found that the glandular cells of the lacrimal gland in cat were containing small fat droplets.

ENZYMES

Venkovsky (1964) observed that in albino rats localization of alkaline phosphatase was weak in the intracellular spaces of the acini and in the lumina of the acini. The small and medium sized ducts and the myoepithelial cells were found to be more strongly positive. Basal portion of the acinar ce cells gave weak reaction.

Sinha (1965) observed that in sheep and goat, the alkaline phosphatase activity was stronger in the vicinity of the basement membrane. The reaction for acid phosphatase was week.

Abel Jr. and Ellis (1966) observed that in turtle, different phosphatases were extremly abundant within the lacrimal gland but were separately and discretely localized to specific areas. Alkaline phosphatase was restricted to the connective tissue and blood vessel endothelium.

Bolden (1967) noted that in male wister rat's lacrimal gland the sites of localization of alkaline phosphatase activity were principally the capillaries, the acini and the myoepithelial cells. Age did not cause any significant alterations in the intensity of the reaction.

Kuhnel (1968 c, d, f) observed a number of different enzymes in rabbit, cat, sheep, goat, cattle and human lacrimal gland.

Rajendra Agricultural University, Bihar, M. Sc. (Vet.) Thesis, 1971

MATERIALS AND METHODS

Lacrimal gland from twentyfour Indian buffaloes were taken for gross, histological and histochemical studies for this investigation. Out of twentyfour animals, eleven were adult females between nine to fourteen years of age while among the rest, thirteen were male calves varying from 1 to 3 years of age. The glands were collected from both right and left orbits of each animal, which were apparently healthy and free from any disease. The specimens of all female adult buffaloes were collected from local slaughter houses after their slaughter. Among the young male group, only six were emblamed by Grossman formula (1959) in the Department of Anatomy and the rest seven were freshly killed calves in the Department of Surgery, Bihar Veterinary College, Patna. During collection of materials due care was taken to avoid damage of these glands. Soon after removal from the dead bodies, the specimens were measured and put into different fixatives to prevent autolysis of the tissues.

TECHNIQUES

The following techniques were adopted for gross, microscopical and histochemical observations:

Gross

Both right and left orbital contents were taken out from each orbit with proper care and then the glands were separated from the respective eyeball. The superfluous connective tissue and fat were carefully removed. The glands were weighed in a physical balance. Gross measurments were taken on

Rajendra Agricultural University, Bihar, M. Sc. (Vet.) Thesis, 1971

eleven male calves and eleven female adults. The maximum length, breadth and thickness of both right and left glands were measured by slide caliper. The volume of each gland was recorded by water replacement method. The standard error and average length, breadth, thickness and volume of the gland of both sexes were calculated.

Microscopic

Fixatives - The following fixatives were used during the course of work for histological and histochemical studies:-

1. 10% aqueous formalin.
2. Bouins fluid.
3. UNNA'S fixatives (Gurr, 1962)
4. Neutral buffered formalin.
5. Zenker's fluid.
6. Chilled acetone, -20° C (Culling, 1969)
7. Helly's fluid.

Preparation of blocks - About one cm long and 0.5 cm thick piece of tissue were taken from each gland and labelled for proper identification. The tissues were then put into the selective fixatives for 24 to 48 hours. The tissue was washed for 6 to 12 hours in running tapwater as required in particular procedure.

Dehydration and clearing - After fixation and washing of the tissues the following schedules of dehydration and clearing were adopted:

(A) Ethyl alcohol-cedarwood oil schedule (Culling, 1969).

(a) 70% Ethyl alcohol - Two changes - 2 to 4 hours each.

Rajendra Agricultural University, Bihar, M. Sc. (Vet.) Thesis, 1971

(b) 80% Ethyl alcohol - Two changes - 2 to 4 hours each.

(c) 95% Ethyl alcohol - Two changes - 2 to 4 hours each.

(d) Absolute alcohol - Two changes - 2 to 4 hours each.

(e) Cedarwood oil - Two changes - 24 hours each.

(B) Acetone-Benzene Schedule (Culling, 1969):-

(a) 70% Ethyl alcohol - Two changes - 2 to 4 hours each.

(b) Acetone I - 15 to 20 minutes.
Acetone II - 15 to 20 minutes.
Acetone III - 15 to 20 minutes.

(c) Acetone Benzene (1:1) mixture - 15 to 20 minutes.

(d) Benzene I - 15 to 20 minutes.
Benzene II - 15 to 20 minutes.

Impregnation - The tissue were placed in paraffin oven at 60°C after dehydration and clearing according to the following schedule:-

(a) Paraffin (at 60°C) - No. I - 2 to 4 hours.

(b) Paraffin (at 60°C) - No. 2 - 2 to 4 hours.

(c) Paraffin (at 60°C) - No. 3 - 2 to 4 hours.

Embedding - The tissues were embedded in melted paraffin (60°C with cercin B.D.H.) and the blocks were prepared.

Sectioning - The sections were cut at different thicknesses varying from 3 μ to 15 μ. They were then flattened on warm water

Rajendra Agricultural University, Bihar, M. Sc. (Vet.) Thesis, 1971

and lifted on the albuminised slides. These slides were dried on the hot plate. Frozen sections were also prepared for some histochemical studies.

Staining - The following stains were prepared and used in the present investigations:

(A) For histological observations

1. Harris's Alum haematoxylin and eosin was used as a routine stain.

2. Weigert and van Gieson's stain (Culling, 1969)- for collagen and muscle fibres.

3. Gomori's Aldehyde-fuchsin stain (Gomori, 1950)- for elastic tissue.

4. Gridley's Reticular stain (Gridley, 1951) - for reticular fibres.

5. Grossman's Triple Mallory stain (Grossman, 1937) - for secretory granules, neuro-keratin network, elastic fibre.

6. Phosphotungstic acid haematoxylin Mallory's (Culling, 1969) - for collagen, reticulin, fibroglia, myoglia, centrioles and general nervous tissue.

7. Triple Mallory stain (Gray, 1958) - for connective tissue.

8. Azo-carmin Mallory (Gurr, 1962)

9. Weigert's resorsin fuchsin (Culling, 1969) - for elastic fibres.

10. Polychrome Methyleneblue stain (Gurr, 1962) - for mast cells and plasma cells.

11. Metzner's method (Sumner and Sumner, 1969) -

Rajendra Agricultural University, Bihar, M. Sc. (Vet.) Thesis, 1971

for mitochondria.

12. Thionin stain (Gurr, 1962) - for nervous tissue.

(B) For histochemical observations:-

1. Periodic acid-schiff (PAS) reaction (Pearse, 1968) - for carbohydrate and their complex substances.

2. Best's Carmine stain (Culling, 1969) - for glycogen.

3. Alcian blue - Neutral red (Sumner and Sumner, 1969) - for acid mucopolysaccharides (AMP).

4. Mowry's colloidal iron stain (Luna, 1968) - for acid mucopolysaccharides (AMP) and connective tissue fibres.

5. Mercury-Bromphenol blue stain (Pearse, 1968) - for demonstration of proteins.

6. Millon reaction (Pearse, 1968)- for demonstration of tyrosin.

7. Ninhydrin-schiff method (Pearse, 1968) - for demonstration of protein-bound NH_2.

8. Lillie and Ashburn's isopropanol oil red O method (Culling, 1969) - for demonstration of fat and lipids.

9. Sudan black B reaction (Pearse, 1968) - for demonstration of lipids.

10. Feulgen reaction (Culling, 1969) - for demonstration of DNA.

11. von Kossa's reaction (Culling, 1969) - for demonstration of calcium.

12. Mayer's mucicarmine (Jones, 1950) - for demonstration of mucin.

Rajendra Agricultural University, Bihar, M. Sc. (Vet.) Thesis, 1971

13. Mayer's mucihaematein (Culling, 1969) - for demonstration of epithelial mucin and connective tissue mucin.

14. Gomori's Technique (Culling, 1969) - for demonstration of Alkaline Phosphatase.

By usual procedures the slides were dehydrated, cleared and mounted with either glycerine jelly or D.P.X.

Measurments

Gross - For gross study the weight, length, breadth and thickness of each gland was taken. The average and standard errors of both sexes were calculated.

Micrometry - Before starting the microscopic measurments, the different magnifications were standardised with the aid of a stage and an ocular micrometers. Six readings from each slide were recorded for the width of capsule and for the diameter of interlobular and intralobular ducts. The same method was adopted to record the different diameters of an alveolus, cell and length and width of a nucleus. The thickness of the capsule and diameter of the interlobular ducts were measured in 10 x 10 magnification whereas intralobular ducts and the different diameters of the alveolus was taken under 10 x 40 magnification. Height of the cell and measurment of the nuclei etc. were taken in oil immersion magnification.

The average measurments and standard errors for both sexes were calculated. The readings were presented in tables.

****

Rajendra Agricultural University, Bihar, M. Sc. (Vet.) Thesis, 1971

RESULTS AND DISCUSSION

GROSS ANATOMY

The mammalian lacrimal gland is an exocrine gland mainly located in a fossa in the dorso-lateral aspect of the orbit. It is large modified skin gland which has assumed specialised functions as a tubulo-alveolar gland in similarity with the parotid. The gland usually comprises of two parts, a larger superior or orbital part and a small inferior or palpebral part. There is contiguity of both parts posteriorly. The gland is encased in periorbit. In most of the animals, the gland reveals distinct lobulations and is pale red in colour.

In the present study the lacrimal gland of Indian buffalo (Bos bubalis) was found to be dorso-laterally located in a depression on the under surface of the supra-orbital process and between the supra-orbital process and supero-external aspect of the eyeball. It was obviously lobulated and the surface lobulation was clearly marked in both left and right gland (Plate I). The gland was flat in appearance due to its location between the globe and the orbital wall. It was evidently thick at the superior or upper part whereas the lower or inferior part of the gland was thin.

The dorso-lateral surface was convex in adaptation to the concavity of the under face of the supra-orbital process (Plate II). The ventero-lateral surface of the gland was concave corresponding with the convexity of the eyeball and was in apposition to external recti and levator pulpebrae superioris

Rajendra Agricultural University, Bihar, M. Sc. (Vet.) Thesis, 1971

1
5
3
4

muscle. Both surfaces possessed the characteristic glandular lobulations. The anterior border was deeply notched or serrated. The posterior border was triangular in outline but in case of young one the apical angle of the triangle was rounded giving a dome shaped appearance (Plate III). The medial half of the gland was comparatively thicker than the lateral half in both young and old subjects. The medial angle was rounded in outline. The lateral angle was elongated and tapering (Plate IV).

The gland was completely enclosed within the orbit by the thick periorbital fascia. It was pale pink in colour in fresh specimens but became gray on fixation. The shape and size was greatly variable in accordance with the age of animals. The gland was more elongated in younger subject whereas in adults the breadth became gradually wider as age advanced. In calves, certain sparsed small lobules were observed extending from the thinner lateral half of the gland. These discrete lobules were widely separated by connective tissue from main substance of the gland.

Maximum length, breadth, thickness, volume and weight of all specimens from young group (buffalo calves) are furnished in Table No. I. In young animals aged from one to two and a half years, the maximum length, breadth, thickness, volume and weight of right lacrimal gland varied from 5.20 to 8.10 cms, 2.20 to 4.10 cms, 0.50 to 0.82 cms, 3.0 to 10cc and 3.30 to 9.25 gms respectively. The average length, breadth, thickness, volumes and weight of right lacrimal gland were 7.09 ± 0.30 cms, 2.90 ± 0.15 cms, 0.66 ± 0.03 cms, 5.50 ± 0.53 cc and 5.46 ± 0.45

Rajendra Agricultural University, Bihar, M. Sc. (Vet.) Thesis, 1971

RIGHT
LEFT
LACRIMAL GLAND


LACRIMAL GLAN
4
2
3
3
2
4
1
1
LEFT
RIGHT

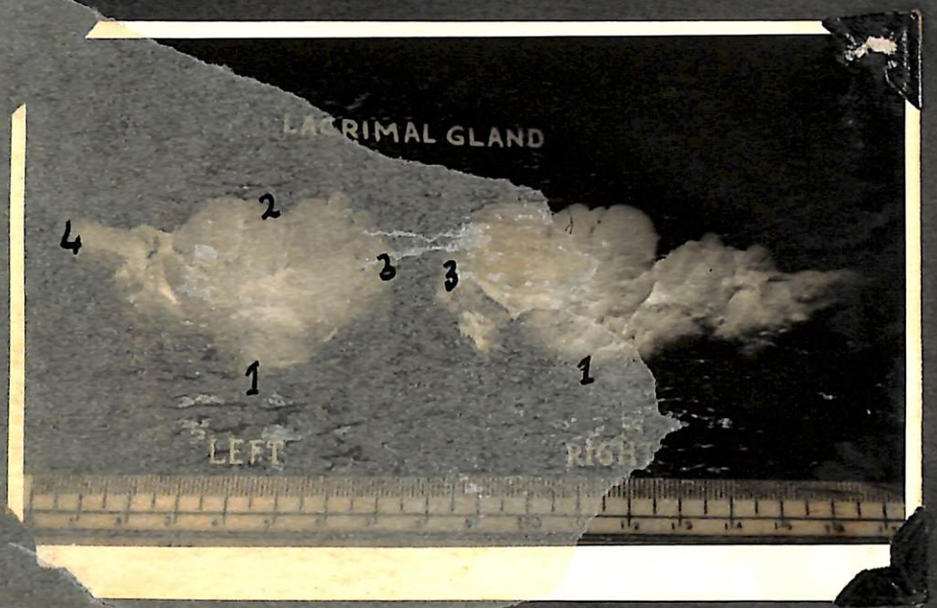

No. 44

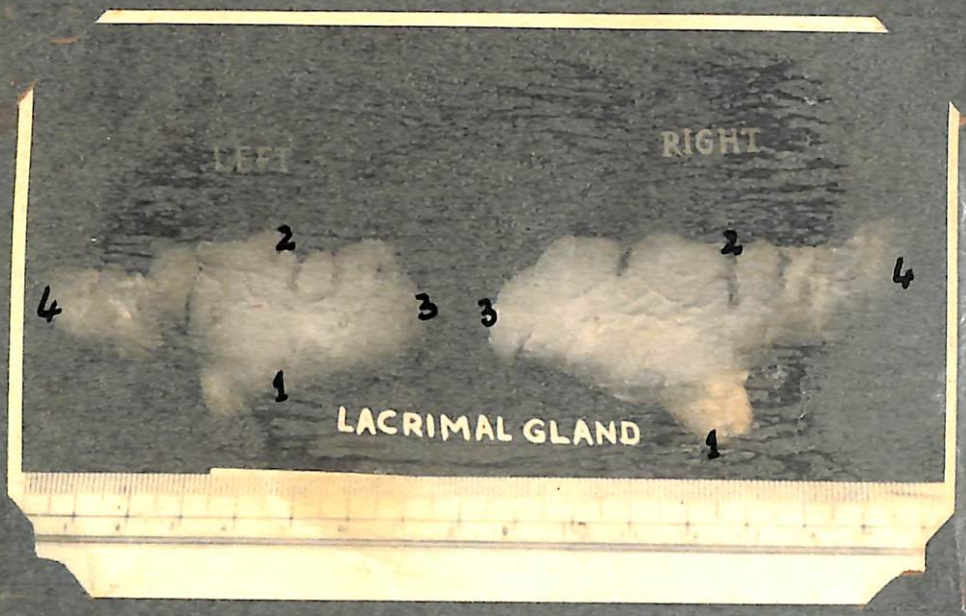
LEFT
RIGHT
2
2
4
4
3
3
1
1
LACRIMAL GLAND

gms respectively.

The length, breadth, thickness, volume and weight of the gland varied from 5.10 to 7.65 cms, 2.10 to 3.30 cms, 0.55 to 0.82 cms, 3 to 8 cc and 3.20 to 7.50 gms respectively. The average length, breadth, thickness, volume and weight of left gland in young animals were 6.68 (± 0.25) cms, 2.73 ± (0.08) cms, 0.67 (± 0.09) cms, 4.91 (± 0.39) cc and 5.01 (± 0.34) gms respectively.

The measurments of maximum length, breadth, thickness, volume and weight of all specimens from adult group (female buffalo) are furnished in Table No. II. The maximum length, breadth, thickness, volume and weight of right lacrimal gland in adult group varied from 7.58 to 9.07 cms, 3.52 to 5.14 cms, 0.55 to 0.96 cms, 8 to 22 cc and 9.10 to 21.20 gms respectively. The average length, breadth, thickness, volume and weight of right gland were 8.33 (± 0.16) cms, 4.19 (± 0.14) cms, 0.80 (± 0.03) cm, 15.68 (± 1.26) cc and 15.72 (± 1.24) gms respectively.

The length, breadth, thickness, volume and weight of left lacrimal gland of adult group varied from 6.70 to 9.82 cms, 3.14 to 4.65 cms, 0.53 to 1.02 cms, 8 to 20 cc and 9 to 19 gms respectively. The average length, breadth, thickness, volume and weight of left gland were 7.77 (± 0.36) cms, 3.85 (± 0.13) cms, 0.75 (± 0.03) cms, 13.86 (± 0.94) cc and 14.01 (± 0.87) gms respectively.

The morphological observations on the lacrimal glands recorded in this study were in corroboration with the observations of Sundwall (1916), Sisson and Grossman (1962)

Rajendra Agricultural University, Bihar, M. Sc. (Vet.) Thesis, 1971

and Raghavan (1964) in ox, Habel (1955) in cow, Prince et al. (1960) in cattle and Singh (1962) and Dass (1966) in buffalo. It therefore indicated that there existed no appreciable morphological difference between the lacrimal glands of ox and buffalo.

The location of the gland observed to be in the undersurface of the supra-orbital process, was in confirmity to the findings of Habel (1955) in cow. Though the location of this gland in buffalo has been found in the present study to be the same as that in cow, it may be different in different species of animals as reported by Bradley (1913) in horse and Wood (1946) in man. However, this needs further confirmation.

The colour of the gland was found to be pale pink which slightly differed from Singh (1962) and Dass (1966) who observed the colour to be pink and deep red respectively.

The measurments recorded in the present study (Tables I & II) were not consistent with the measurments recorded by Singh (1962) and Dass (1966) in buffalo. The figures also were not in accordance with the measurments reported by Sundwall (1916) and Diesem (1968) in ox. It therefore suggested that the differences might be attributable to difference in breed, age and environmental conditions. Bremer et. al. (1948) also described that age is the factor which governs the development of the gland.

The present study also revealed that the right gland was found to be heavier, more voluminous and had large dimensions as compared to the left in both young and old group. On statistical analysis ('t' test) the differences were

Rajendra Agricultural University, Bihar, M. Sc. (Vet.) Thesis, 1971

found to be highly significant. So far, the author has not come across any literature which has mentioned the above facts.

A salient feature of this study was that medial angle of both the gland was round and anterior or cranial border was deeply notched or serrated. These differences could be properly utilised for the identification of right and left gland.

MICROSCOPIC ANATOMY

Capsule

In common with those of most other glands in the body, the lacrimal gland is also enveloped by a thick capsule. The capsule has a basic matrix of typically staining connective tissue fibres in which blood vessels, nerves and ducts of different diameters are embedded. There are different types of connective tissue fibres present in the lacrimal capsule. The proportion of these fibres varies tremendously, collagenous fibres being the most numerous. Smooth muscle fibres are present in less number. Elastic fibres are also present in the lacrimal capsule in scanty number.

In the present investigation the capsule of lacrimal gland of Indian buffalo was found to be composed of areolar tissue by the use of different connective tissue stains (Plate V). The capsule was fused with the general areolar and adipose tissue of the orbit. Strands of tough connective tissue fibres derived from the periorbital fascia was also intimately fused with the capsule. It was bound down to the glandular paren-

Rajendra Agricultural University, Bihar, M. Sc. (Vet.) Thesis, 1971

6
7
3
5
4
3
3
3
2
1

chyma by numerous interlobular septa which originated from the capsule and ramified throughout the gland separating it into numerous lobules (Plate VI). The capsular sheath was highly innervated by nerve fibres and was also richly vascularised. Numerous blood vessels and ducts of different diameters were observed. The fat cells were found to be scattered in the capsular thickness. In some places these fat cells were in high concentration. The average thickness of the lacrimal capsule were 316 μ and 642 μ in young and adult animals respectively (Tables III & IV). The places from where the septa originated were much denser. This fibrous capsule was composed of areolar tissue in general. Both collagenous and elastic fibres were present in abundance. Numerous globules of fat were seen singly or in groups irregularly distributed throughout the sheath. Some smooth muscle fibres were also observed intermingled with the collagenous fibres. On the internal surface, the capsule contained large blood vessels and nerve fibres. Numerous elongated and flattened nuclei were observed. The elastic fibres were long and fine and were arranged almost parallel to the surface of the capsule (Plat VII).

The above findings on the structures of the lacrimal capsule in Indian buffalo was quite in agreement with the findings of Sundwall (1916) in ox, Singh (1962) in buffalo and Sinha and Calhoun (1966) in sheep and goat.

A similar discription has also been made by Bremer and Weatherford (1948) in human lacrimal capsule. However, the author did not find any smooth muscle band related to the ventral surface of the capsule of the lacrimal gland in

Rajendra Agricultural University, Bihar, M. Sc. (Vet.) Thesis, 1971

3
3
3
1
2
3
3
1
2
1
2

Indian buffalo as observed by Sinha and Calhoun (1966) in sheep and goat. The study did not show remarkable difference between left and right glandular capsule. No sex difference was observed in the structure of the capsule also.

Stroma

Interlobular Septa

The interlobular septa were derived from the capsule and divided the parenchyma into numerous lobules of irregular shapes and sizes. These septa originated from the capsule at irregular intervals. Secondary septa originated from two or three large primary septa and entered the various lobules. These branches of primary septa formed the supporting structures of the lobules. It also supported other structures of stroma , surrounding the various blood vessels, nerve fibres and ducts of different diameters. These vessels, nerves and ducts were in close proximity to each other.

By application of various connective tissue stains, it was confirmed that the interlobular septa were composed of practically the same tissue as observed in the capsule. Collagenous fibres were in large amount which were becoming denser in old groups (Plate VIII). A few elastic fibres were also present. Presence of smooth muscle fibres were also noticed. The branches of septa contained fine collagenous fibres, delicate elastic fibres and few smooth muscle fibres. Occasionally adipose tissue in groups were present. Lymphatic tissue was observed to a varying degree in the septa. The connective tissue were very loose

Rajendra Agricultural University, Bihar, M. Sc. (Vet.) Thesis, 1971

in young animals but it was denser in old subjects. Numerous fibroblasts were observed. Varying number of plasma cells were seen in both interlobular and intralobular tissues.

The observations on the structures of interlobular septa of lacrimal gland in Indian buffaloes were in agreement with the findings of Sundwall (1916) in ox, Bremer and Weatherford (1948) and Copenhaver (1964) in human, Prince et al. (1960) in cattle, Singh (1962) and Dass (1966) in buffaloes and Sinha and Calhoun (1966) in sheep and goat.

Bremer and Weatherford (1948) in human described that lymphatic tissue was present to a varying extent in the septum which was lesser in number in puberty and was abundant in aged subject. The same features were also observed in the lacrimal gland of buffaloes.

The present study also disclosed that connective tissue septa were thinner in young animals but became denser with the advancing age as described by Wolff (1958) in human lacrimal gland.

Intralobular Septa

Present investigation revealed that the intralobular septa was made up of connective tissue. These connective tissues were mainly composed of collagenous and reticular fibres (Plate IX). Presence of elastic fibres were related with the blood vessels. Repeated examinations of tissues fixed in different fixatives and stained both by Weigert's resorcin fuchsin and Gomori's aldehyde fuchsin, did not reveal presence of any elastic fibre surrounding the acini. Collagenous fibres were denser around

Rajendra Agricultural University, Bihar, M. Sc. (Vet.) Thesis, 1971

the capillaries and intralobular ducts.

Plasma Cell

Numerous plasma cells were observed in interalveolar spaces (Plate X). Occasionally some fat cells and lymphocytes were also noticed. They usually surrounded the ducts. The number of these plasma cells varied from place to place. In some places, it was in clusters. These cells were typical in appearance. The nuclei of these cells were somewhat round, more or less eccentrically placed with peripheral arrangment of the chromatin and fine granules in the protoplasm. These cells were differently shaped - some spheroidal, some oval and others elongated and irregular in outline. Singh (1962) called these cells as epithelioid cells which were in groups in the spaces between the tubules and acini and in the interacinar connective tissues.

In young or old group of animals did not show any difference regarding the presence of these plasma cells.

The present findings regarding the structures of intralobular septa were in close accordance with the observations of Sundwall (1916) in ox, Singh (1962) and Dass (1966) in buffalo and Sinha and Calhoun (1966) in sheep and goat.

Plasma cells were also identified by Sundwall (1916) in ox and Sinha and Calhoun (1966) in sheep and goat.

Last (1961) also described the aggregation of plasma cells intra-alveolar connective tissue.

The Unna polychrome stain for differentiation of plasma cells was not giving satisfactory results as the

Rajendra Agricultural University, Bihar, M. Sc. (Vet.) Thesis, 1971

glandular parenchyma was also stained at the same time. However, the chromatin material was taking deep stain which was adherent to the nuclear membrane giving the nucleus a " cart wheel " appearance. The functional significance of plasma cells in the interalveolar tissue was not clear. Probably it helped in the production of antibodies. Michel and Vencea (1931) found that the extracts of the lacrimal gland had motor action on plain and cardiac muscles. It was probable that the plasma cells might have been associated with the internal secretion of the lacrimal gland, as attributed by these authors.

Parenchyma

Acini or alveoli

Alveoli are the secretory units of the lacrimal gland. Its shape, size and nature varies greatly according to mode of their of secretions. In some species, it is serous in nature. It may be purely mucous type or mixed in some species. These units secrete tears with some enzymes. They are generally lined by glandular epithelium.

The present study revealed that the parenchyma of the lacrimal gland of Indian buffalo was an agglomeration of alveoli or acini, tubules and different kinds of ducts. These structures were embedded in connective tissue stroma (Plate VI). It was confirmed from Gridley's reticular stain that alveoli were preponderantly weaved by reticular fibres. These supporting fibres were finally ramified and surrounded each acinus or tubule, forming a network of reticulum and a base for the alveolus (Plate XI).

Rajendra Agricultural University, Bihar, M. Sc. (Vet.) Thesis, 1971

Using various stains, it was observed that the alveoli were mixed in type. Both serous and mucous alveoli were noticed. In some cases one and in the same alveolus few cells stained lightly or faintly bluish and others stained deep in haematoxylin and eosin preparation. Some alveoli were found to be showing affinity for basophilic stain and in such acini the nuclei of the lining cells were somewhat flattened and situated against the basement membrane. Mayer's Mucihaematein and PAS technique were found to be ideal for differentiating serous and mucous cells and alveoli. Even single alveolus was mixed in type. Mitotic figures were noticed (Plate XII) in the cells of the alveoli and ducts.

Serous alveoli

The serous alveoli were lined by pyramidal epithelial cells resting upon a basement membrane and surrounding a narrow lumen. The cell boundaries were apt to be indistinct. The lumen was very narrow. In some cases lumen was not observed at all. Secretory granules were eosinophilic and basal striation was not observed. A solitary and big round or slightly oval nucleus was occupying each cell palcing itself away from basement membrane (Plate XIII). Secretory capillaries were noticed in serous alveoli.

Mucous alveoli

In the routine haematoxylin and eosin preparations, the purely mucous alveoli presented a light bluish-purple appearance in contrast to the deep reddish-purple of the serous alveoli. The nuclei were rounded, oval or flattened. In majority of cases they were rounded or oval and in some cases it was flatt-

Rajendra Agricultural University, Bihar, M. Sc. (Vet.) Thesis, 1971

ened. These nuclei were situated at different levels from basement membrane depending upon the shape of the nucleus. The flattened nuclei were always found to be situated at the base of the cell. When these nuclei were round or oval, they occupied a position in the cell away from the basement membrane. Secretory granules were in more denser form around the apical portion of the alveoli. Some cells were noticed with cytoplasmic network vacuoles. Sometimes serous demilunes were also observed.

Occasionally only basal portion of the alveolus was sectioned and therefore in this way an aggregation of cells with distinct nuclei were noticed.

Phosphotungstic acid haematoxylin Mallory's stain, like other stains also revealed the presence of three types of alveoli: (a) acidophilic, (b) basophilic and (c) mixed types.

The following glandular cells were noticed:-

(A) According to the colour of granules

(a) Cells containing yellowish red granules, dispersed throughout the whole extent of the cells.

(b) Cells containing bluish-purple granules usually finer than the former, dispersed throughout the cells.

(c) Cells containing both types of granules.

(B) According to shape of granular cells

(a) Pyramidal type

(b) Columnar type

(c) Polyhedral type

Rajendra Agricultural University, Bihar, M. Sc. (Vet.) Thesis, 1971

Azocarmine mallory technique differentiated two types of granules. Some fine secretory granules were found to have taken orange red colour. Coarse granules were with purple colour and were more distinctly discriminated (Plate XIV). Some zymogenic granules were also noticed.

It was noticed that lacrimal gland tissues prepared according to Metzner's method for demonstration of mitochondria was satisfactory which had shown these elements as cocci or granular form irregularly distributed throughout the cell with marked fuchsinophilic character (Plate XVIII). Secretory granules had also the affinity for acid fuchsin.

The alveoli were of different shape and size. They were round, oval and irregular in outline. The average diameter of round alveolus was 42.70 μ and 38.95 μ in male and female subjects respectively. The average greatest length and width of oval alveolus were 63.37 μ and 40.70 μ respectively in young male. It was 50.33 μ and 34.49 μ respectively in old female. The maximum average height of pyramidal cells was recorded as 14.25 μ and 17.82 μ respectively in young and aged groups. The average length and breadth of columnar cell was 16.03 μ and 7.38 μ respectively in young animal and 18.20 μ and 7.06 μ in aged object. The average diameter of round nucleus was recorded as 5.66 μ and 5.98 μ respectively in young and aged animals. The average length and width of flattened and oval nucleus was 7.20 μ and 2.84 μ respectively in young animals and it was 8.71 μ and 4.58 μ respectively in aged subject. These measurments have been summarised in tables III & IV.

Rajendra Agricultural University, Bihar, M. Sc. (Vet.) Thesis, 1971

Bremer and Weatherford (1948), Greep (1954), Finerty and Cowdry (1960), Arey (1968) and Ham (1969) described that lacrimal gland was a compound tubulo-alveolar gland. The same view was also expressed by Kuhnel (1968a, b, c, d, e, f) in human, cattle, goat, rabbit etc.

The present study also revealed that the lacrimal gland of Indian buffalo was compound tubulo-alveolar gland. The same finding was also observed by Singh (1962) and Dass (1966) in buffalo.

Nicolas (1914) and Sisson and Grossman (1962) mentioned that this gland in case of pig was of mucous type. Trautmann and Fiebiger (1957) described that cells giving mucin reaction were found in the lacrimal gland of sheep. Prince et al.(1960) described as serous gland in cat, horse, cattle, pig and rabbit. The present study revealed that buffalo lacrimal gland was seromucous in type. The same findings were noticed by Singh (1962) in buffalo and Kuhnel (1968 d) in cattle and Ruskell (1968) in monkey. Variation in the shape, size and situation of nuclei in mucous cells were observed in the present investigation. It was suggested that the secretion of the cell was the chief factor to govern the situation, shape and size of these nuclei at different levels. When the cell was full of mucin, nucleus became flattened angular in shape and situated close to the basement membrane due to the inside pressure of secretory granules. But when the cell was depleted of mucinous secretion, the nuclei changed its shape and situation becoming round or oval in shape and moved away from the basement membrane.

Rajendra Agricultural University, Bihar, M. Sc. (Vet.) Thesis, 1971

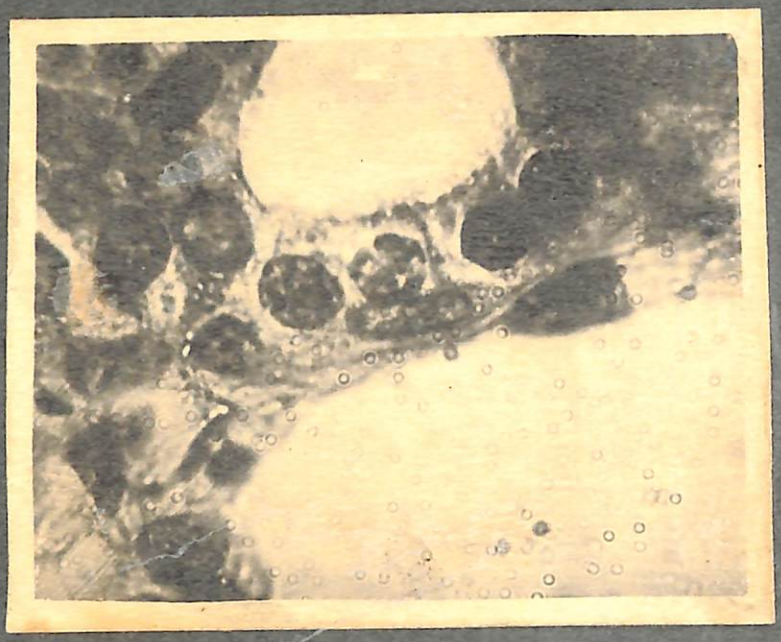

In some places within the lobules, aggregation of cells with distinct nuclei were observed. It was due to the fact that the alveolus was sectioned through the wall. It was not possible in the present study, without physiological findings to classify the gland according to mode of secretion as noted by Singh (1962) in buffalo lacrimal gland being epocrine in nature.

Summarising the micro-measurments of acini in both sexes (Tables III & IV), it appeared that the female lacrimal gland was characterised by the presence of small acini with narrow lumen. Luciano (1967) observed sexual diamorphism in rat lacrimal gland in which the female gland was differentiated from male by the presence of comparatively small acini and easily visible cell border. However, it needed further investigation for the sexual differentiation.

Microvilli were not noticed in the lumen of the alveoli as studied by Kuhnel (1968 b) in goat.

Kuhnel (1968 f) observed coarse and fine granules in human lacrimal gland. The same type of granules were also noticed in buffalo lacrimal gland.

Organells in the cytoplasm was not observed in detail. Mitochondria was visible in cocci or granular form. It was not possible to demonstrate centriole in the prenuclear region following phosphotungstic acid mallory haematoxylin technique as claimed by Culling (1969).

Summarising the whole findings, these observations appeared specially interesting in view of the fact that earlier microscopists like Sisson and Grossman (1953), Finerty and

Rajendra Agricultural University, Bihar, M. Sc. (Vet.) Thesis, 1971

Cowdry (1960), Arey (1968) and Bloom and Fawcett (1968) described that lacrimal gland resembled the true parotid salivary gland but the present study differed with this view and it would be suggestive by resembling the lacrimal gland of Indian buffalo with sub--maxillary salivary gland.

Myo-epithelial cell

The present investigation recorded the presence of myo-epithelial cells in the lacrimal gland of Indian buffalo. These elements were recognisable by using Weigert and van Gieson's stain. They were found to lie between the basement membrane of the secretory epithelium and the secretory cell. Frequently they were found in ducts but occasionally observed in alveoli. Nucleus was dark in colour. These cells appeared stellate with a central portion containing the nucleus. Generally these nuclei were flattened oval or elongated parallel to the basement membrane (Plate XV). The nuclear surface was mostly regular. The cytoplasm was fine and stained faintly. These cells were visible better in phosphotungstic acid haematoxylin mallory and azocarmine stains. Cytoplasmic fibres were not observed.

The present study brought to the conclusion that myo-epithelial cells were present in the lacrimal gland and had limited distribution in the alveoli and comparatively more in ducts. The same observations were also noticed by Scott and Pease (1959) in rat lacrimal gland.

Sundwall (1916) observed these elements and called it " Korbzellen ".

Ithikawa and Nakijima (1962) found these

Rajendra Agricultural University, Bihar, M. Sc. (Vet.) Thesis, 1971

elements around the terminal portion of rat lacrimal gland as well as around such ducts which were lined with secretory cells.

It was thought that these cells might be contractile elements which had an important role in the expulsion of secretion.

Arey (1968), Bloom and Fawcett (1968) and Ham (1969) described the presence of these cells in human lacrimal gland. Many names have been given by various authors. Some referred these cells as muscular in nature and others as connective tissue cells (Sundwall, 1916). Further work on these elements, especially of an embryological nature, would be essential to determine the positive nature of these cells.

Ducts

Inter-lobular ducts

The primary ducts ramified to form the inter-lobular ducts. These ducts were found to be embedded in inter-lobular connective tissu septa in company with nerves and blood vessels (frontispiece). These ducts were of different diameters. The average diameter of interlobular duct was 85.64 μ in adult subject and 69.73 μ in young animals (Tables III & IV).

These ducts were lined by single layer of epithelium which was cuboidal or low columnar in nature. Cell boundaries were not distinct at all in any stain employed in the present study. The cytoplasm stained deeply and evenly in the various cytoplasmic stains. Study of these cells by means of oil immersion, noticed the cytoplasm to be very finely granular and

Rajendra Agricultural University, Bihar, M. Sc. (Vet.) Thesis, 1971

homogenous. Basal striations were not observed. Individual cell was occupied by single oval or rounded nucleus. The nuclei were found to be touching each other. Sometimes myoepithelial cell was noticed with large elongated nucleus under the basement membrane of the cell (Plate XV). Bigger ducts were surrounded by dense connective tissue (Plate VIII). The connective tissue wall surrounding the epithelium of the ducts varied in amount depending upon the thickness of the septa in which the ducts were situated.

The present observation of interlobular ducts of lacrimal gland of buffalo were the same as noticed by Sundwall (1916) in ox, Prince et al. (1960) in sheep and Singh (1962) in buffalo.

Kuhnel (1968 d) and Burock (1969) found the presence of goblet cells in the duct in case of cattle, but in the present studies no goblet cell was observed.

In some cases, only the excretory duct was completely lined by single layer of goblet cells (Plate XVI) which was also confirmed by PAS and other mucin reactive stains.

Intra-lobular duct

The intra-lobular ducts varied in the size of the lumina and the quantity of surrounding connective tissue in which preponderancy of collagen fibres were noticed (frontispiece). The lumen of these ducts were of different diameters. The average diameter of intra-lobular duct was 29.70 μ and 16.85 μ respectively in aged and young animals.

They were lined with single layer of cuboidal epithelium. Some lumina of these ducts were observed to be

Page No. .....

Rajendra Agricultural University, Bihar, M. Sc. (Vet.) Thesis, 1971

partially filled with some epithelial debris. The lining epithelium was not clear in outline. Each epithelium was occupied by a single big nucleus which was mostly round or slightly oval in shape. The cell boundaries were not distinct. The nuclei were closely situated slightly away from the basement membrane(Plate XVII). These nuclei were multinucleolated and were deeply stained. Mitochondria were in denser form in cytoplasm than the cytoplasm of the alveolar epithelium (Plate XVIII). The cytoplasm of the epithelium did not appear granular. These ducts were not giving any mucin reaction in any mucin-reactive stain.

The interlobular and intralobular ducts were sectioned at different levels and hence they appeared in different angles.

The above findings about the intralobular ducts were the same as observed by Singh (1962) in buffalo and Kuhnel (1968 d) in cattle. Sinha (1965) observed some goblet cells and stratification of lining cuboidal epithelium in intralobular duct in lacrimal gland of sheep.

BLOOD SUPPLY

It has been noticed during morphological study of the gland that its ventral surface was invaded by branches of lacrimal artery and lacrimal nerves.

The present study revealed that the stroma of the gland was highly vascularised. The capsule and septa were richly invaded by blood vessels of different diameters. They were found always in close proximity to ducts and nerves and surrounded

Rajendra Agricultural University, Bihar, M. Sc. (Vet.) Thesis, 1971

by connective tissue. Various connective tissue stains revealed the same histological structures of these blood vessels as described by various histologists. The internal elastic layer of medium sized artery was clearly stained black with aldehyde-fuchsin preparation (Plate XIX). The interalveolar spaces were found to be full of blood capillaries. Very fine collagenous fibres were noticed occasionally surrounding these capillaries. Blood cells were orange, vermilion, and eosinophilic in different mallory, Weigert and van Gieson and haematoxylin and eosin preparations. Some of the blood vessels were cut transentially and some longitudinally and transversely.

The present investigation including microvascular architecture of the lacrimal gland of Indian buffalo was the same as studied by Abel Jr. and Ellis (1966) in man and Rajya (1956) in buffalo.

NERVE SUPPLY

The observations to be described in this chapter in respect of innervation pattern of the lacrimal gland was the outcome of a part of histological investigations of the gland in general.

The gland was found to be richly innervated by nerves. Capsule of the gland was highly innervated. These nerve bundles were found to be of different diameters. Some of them were sectioned in longitudinal fashion and some were in transverse directions. The ventral capsular surface was very richly supplied with nerve fibres. In transverse sections, their nuclei were easily

Rajendra Agricultural University, Bihar, M. Sc. (Vet.) Thesis, 1971

recognisable particularly in Grossman's modification of mallory technique. Stromal septa of the gland was also innervated by nerve bundles of different diameters. These nerve bundles were mostly found to be in close proximity to the blood vessels and ducts. Thionin reaction for the demonstration of nerve fibres (Gurr, 1962) were found not to be satisfactory for the lacrimal gland tissue.

Kato (1958) & Ehinger (1966) studied the pattern of nerve supply in lacrimal gland of human and cat respectively. Ruskell (1967, 1968 and 1971) observed the innervation pattern of lacrimal gland in different species of monkey. These nerve fibres were myelinated or non-myelinated.

The observations made under the present investigation revealed that the lacrimal gland of Indian buffalo was richly innervated. Parenchymal innervation pattern and the classification of the nerve fibres were not observed and it required further investigation on this particular aspect chiefly in respect to the glandular secretions.

HISTOCHEMISTRY

While going through the available literatures, it was found that the studies on the histochemical aspect of lacrimal gland of Indian buffalo have not been carried and scientific descriptions were almost lacking. However, in the present study elucidative attempts have been made with the help of various available techniques to study the different organic components of the gland.

Rajendra Agricultural University, Bihar, M. Sc. (Vet.) Thesis, 1971

Periodic acid-schiff reaction (PAS)

Sections from lacrimal gland tissue from different animals were stained by Periodic acid-schiff method. Histochemical observations revealed that the tissue of the gland was reactive for PAS. Stromal connective tissues were weakly positive whereas parenchymal tissues were strongly positive. Interalveolar connective tissue cells were devoid of PAS reaction. Alveoli were mixed in reaction. Some alveoli were strongly positive completely and some of them were completely devoid of PAS reactive substances. It was found to be interesting that even a single alveolus was mixed, some of the epithelium being PAS positive strongly (Plate XX).

Basement membranes of all alveoli were found to be mildly reactive. In some places only apical portion of the cell towards lumen were positive. Duct system of the gland was mildly positive. Goblet cells of excretory duct was strongly positive (Plate XXI). When some of the sections, as control, were digested with human saliva, the colour of the reactive substances became very slightly faint. This was probably due the removal of glycogen content from the sections.

Ping (1964) and Abel Jr. and Ellis (1966) observed PAS reactive substances in the lacrimal gland of guinea pigs and turtle respectively.

Kuhnel (1968 c) noted the PAS reactive granules in the acinar cells of lacrimal gland of sheep. Kronman et al. (1968) noted the presence of PAS reactive substances which were faintly reactive for PAS in golden hamster.

Rajendra Agricultural University, Bihar, M. Sc. (Vet.) Thesis, 1971

Rajendra Agricultural University, Bihar, M. Sc. (Vet.) Thesis, 1971

Glycogen

The histological observations by Best's carmine reaction revealed that the lacrimal gland tissue of Indian buffalo was positive for glycogen (Plate X XII). the stromal and parenchymal tissues were found to be positive. Capsule of the gland including nerves, ducts and blood vessels were reactive for glycogen. The nuclei of the alveoli and interalveolar connective tissue cells were strongly positive. Cell cytoplasm was faintly reactive. Cell cytoplasm and nuclei of the different ducts were found to be equally positive. In some cases nuclear membrane was more reactive than their nucleoplasm.

The presence of glycogen in lacrimal tissue was confirmed by the control sections which were non-reactive or very mildly reactive.

Abel Jr. and Ellis (1966) demonstrated the presence of glycogen in turtle's lacrimal gland. The same observation was made by Kuhnel (1968 a) in rabbit and cat. Burock (1969) was unable to demonstrate the glycogen in cat gland.

Acid mucopolysaccharides

During the observations of PAS reaction, it was confirmed from the control sections that lacrimal tissue of Indian buffalo had complexes of polysaccharides which might be in the form of mucopolysaccharide or mucoproteins and glycoproteins.

The present histochemical studies had demonstrated the alcianophilic affinity of the tissue and hence confirmed the presence of acid mucopolysaccharides (AMP) in lacrimal

gland (Plate XXIII). The stroma of the gland including their blood vessels and nerves were found to be non-reactive for AMP. The parenchymal tissue except their ductual system was of mixed type as this was observed in this study by their alcianophilic reactivity with the stains used. Sometimes the secretion or cell debris present in the ducts were positive for AMP.

Some alveoli were completely negative and some were intensely reactive. Even some of the lining cell of the single alveolus was reactive and others were shown alcianophobia (Frontispiece). It was also studied that this reactivity of the secretory units varied from animal to animal. This might be due to the different secretory phases of the secretion.

The presence of AMP in lacrimal gland were demonstrated by Spicer and Duvenci (1964) in mouse and rat, by Abel Jr. and Ellis (1966) in turtle, by Krestinskaya (1966) in white rat and Kuhnel (1968 a, d, c) in rabbit and cat, catlle and dog.

Kronman et al. (1968) noted the absence of AMP in female golden hamster.

Further classification of mucopolysaccharide has not been undertaken in this study and for that further work is needed.

Proteins

When sections were stained by mercury--bromphenolblue-preparation, the connective tissue and the secretory units of the gland including their ductual system were found to be highly reactive. The interalveolar connective tissues were

Rajendra Agricultural University, Bihar, M. Sc. (Vet.) Thesis, 1971

also strongly positive.

Hence, the observation made under the present study revealed the presence of proteins in all type of tissues in lacrimal gland of Indian buffalo (Plate XXIV).

Fabel *et al.* (1969) demonstrated the presence of proteins in the human lacrimal gland tissue.

Protein-Bound NH_2 group

Ninhydrin-schiff method showed that connective tissue of the gland was slightly reactive or in some places it was moderately positive. The apical portion of some of the alveoli were found to be positive. Basal portion of the alveoli was more reactive but it was not showing uniformity everywhere (Plate XXV).

Blood vessels and nerves were noticed having affinity for the stain. Membrana elastica of the blood vessels were more positive than its other layers. Hence it was noticed, through the observations made under this aspect that protein-bound NH_2 groups were present in the lacrimal gland of Indian buffalo.

The work of Fleming and Allison (1925) in tears of horse, cow, sheep and of Vankovsky (1964) in lacrimal gland of albino rat supported the view that different constituents were present in the lacrimal gland tissue.

Tyrosin

The alveolar cells, ducts and all types of connective tissue cells of the gland were found to be faintly reactive by millon reaction preparation.

Rajendra Agricultural University, Bihar, M. Sc. (Vet.) Thesis, 1971

lacrimal gland of Indian buffalo contained mucin.

Desoxyribonucleic acid (DNA)

The present study revealed the presence of DNA in the nuclei of lacrimal gland tissue of Indian buffalo by Feulgen reaction (Plate XXVIII).

By this method, the plasma cell nuclei had deeply stained chromatin material situated around the periphery of the nucleoplasm in close relation to the nuclear membrane giving a typical " Cart wheel " like appearance.

In the nuclei of the alveolar cells the chromatin network was found to be in the form of granules or sometimes they condensed towards periphery of the nuclear membrane.

The intensity of the colour taken by chromatin network of plasma cell suggested that their nuclei contained more DNA than that of alveolar cells.

Calcium

The lacrimal gland tissue of Indian buffalo was found negative for calcium.

Lipids and Fat

For the detection of lipids and fat secretions were stained with Sudan black B and some thick frozen sections were stained with oil red O.

No lipids were observed either in alveoli or in plasma cells or in ducts in lacrimal gland of buffalo under the present investigation.

It was noticed from the frozen sections

Rajendra Agricultural University, Bihar, M. Sc. (Vet.) Thesis, 1971

stained by oil red O method that fat cells were greater in number and was frequently placed in stroma (Plate XXIX). Similar observations have been recorded by Greep (1954) in human lacrimal gland.

Sinha and Calhoun (1966) noted in sheep and goat that the frozen sections of lacrimal gland tissue stained with Sudan black B were very faintly reactive for lipids.

Enzymes

Despite that several batches of lacrimal glands were subjected to staining by Gomori's technique, they were found non reactive for alkaline phosphatase.

****

Rajendra Agricultural University, Bihar, M. Sc. (Vet.) Thesis, 1971

TABLE V

HISTOCHEMICAL PROPERTIES OF LACRIMAL GLAND

Structures	PAS.	Amp.	Gly.	Pr.	P.B. NH_2	Tyr.	Cal.	DNA. in Nu.	Mu.	Lip.	F.C.
Capsule	(+)	(-)	(++)	(+++)	NO	NO	(-)	(++)	(-)	(-)	-
Interlobular septa	(+)	(-)	(+)	(+++)	NO	(+)	(-)	(++)	(-)	(-)	-
Plasma cell	(-)	NO	(++)	(+++)	NO	NO	(-)	(+++)	(-)	(-)	-
Alveolar cell	(+++)	(+++)	(++)	(+++)	(++)	(+)	(-)	(+)	(+++)	(-)	-
Blood vessels	NO	(-)	(++)	(+++)	(++)	NO	(-)	NO	(-)	(-)	-
Nerves	NO	(-)	(++)	(+)	(++)	NO	(-)	NO	(-)	(-)	-
Interlobular duct	(+)	(-)	(++)	(+++)	(+)	(+)	(-)	(++)	(++)	(-)	-
Interalveolar space	-	-	-	-	-	-	-	-	-	-	(+++)
Intralobular duct	(+)	(-)	(++)	(+++)	(+)	(+)	(-)	(++)	(++)	(-)	-
Duct-secretion	(++)	NO	NO	NO	NO	(-)	(-)	-	(++)	-	-

(+) = mild reactive; (++) = reactive; (+++) = strongly reactive; (-)= negative(non-reactive);
NO = not observed .

PAS.= Periodic acid-Schiff reaction; P.B.NH_2= Protein bound NH_2; Lip.= Lipids;(Fat droplet).

Amp.= Acid mucopolysaccharides; Tyr. = Tyrosin; F.C.= Fat cell;
Gly.= Glycogen; Cal. = Calcium; Mu. = Mucin;
Pr. = Proteins; DNA. = Desoxyribonucleic acid; Nu. = Nucleus.

SUMMARY AND CONCLUSIONS

1. The present investigation was designed to study histological and histochemical aspects of the lacrimal glands of Indian buffaloes. Lacrimal glands from eleven young male and thirteen adult female buffaloes were collected for the present study. Tissues were preserved in common and special fixatives depending upon the staining technique to which they were subjected. Tissues were sectioned between the range of 3 μ to 7 μ . Comparatively thick sections were used for histochemical studies. Observation were made under the light microscope. Besides routine Harris haematoxylin and eosin, selective stains were also used to stain different connective tissues, plasma cells, parenchyma, blood vessels and nerves. In order to carry out histochemical studies, various stains were employed for the demonstration of PAS reaction and identification of glycogen, acid mucopolysaccharide, proteins, protein-bound NH_2 , tyrosin, lipids and fat, calcium, alkaline phosphatase, desoxyribonucleic acid and mucin.

2. The present studies revealed that the right gland was heavier, more voluminious and had bigger dimension as compared to the left in both young and adult animals.

3. The average length, breadth, thickness, volume and weight of right gland of young animals were 7.09, 2.90, 0.66 cms, 5.50 cc and 5.46 gms respectively while the left was 6.68, 2.73, 0.67 cms, 4.91 cc and 5.01 gms respectively. The average length, breadth, thickness, volume and weight of the right gland of adult buffalo were 8.33, 4.19, 0.80 cms, 15.68 cc and

Rajendra Agricultural University, Bihar, M. Sc. (Vet.) Thesis, 1971

15.72 gms while the left was 7.77, 3.85, 0.75 cms, 13.86 cc and 14.01 gms respectively.

4. A salient feature of this study was that medial angle of both the glands were somewhat rounded and anterior or cranial border was deeply notched or serrated. These differences could probably be utilised for the identification of right and left gland.

5. Microscopical study revealed that the gland was encapsulated by a thick and strong connective tissue capsule which was richly innervated and vascularised. The average thickness of the capsule was 316 μ in young and 642 μ in adult animals respectively. The capsule was intimately connected with the glandular parenchyma by numerous interlobular septa which originated from the capsule and ramified throughout the gland separating into numerous lobules.

6. The gland consisted of stroma and parenchyma. The interlobular septa were composed of the same connective tissue as observed in the capsule. Lymphatic tissue was also present. These septa were found to be thinner in young animals but became denser as age advanced.

7. Intralobular septa were devoid of elastic fibres and were mainly composed of fine collagenous fibres and reticular fibres.

8. The presence of plasma cells, besides other connective tissue cells, were recorded in the lacrimal gland of Indian buffalo.

9. The gland was compound tubulo-alveolar and

Rajendra Agricultural University, Bihar, M. Sc. (Vet.) Thesis, 1971

sero-mucous in nature. The parenchyma of the gland was an agglomeration of alveoli of different shapes and sizes. Serous and mucous alveoli were noticed in different phases of secretions. It was interesting to note that even single alveolus was lined by serous and mucous cells suggestive of mixed alveoli.

10. The cells constituting alveoli presented different appearances depending upon the secretory stages from which they were passing. The epithelial lining of alveoli were pyramidal, columnar and polyhedral with round, oval or flattened nuclei. In maximum granular stage, the cells were large, spheroidal or oval. Generally granules were uniformly distributed throughout the cell of the alveoli. Two types of granules - coarse and fine were noticed.

11. Mitochondria were found to be in the form of large granules.

12. Myoepithelial cells were noticed in the lacrimal gland of Indian buffalo.

13. Mitotic figures in different stages were noticed in the cell.

14. Micro-measurments of capsule (thickness), diameters of round or oval alveoli, height of pyramidal cells, length, breadth of columnar cells of alveoli, diameters of round nuclei and diameters of oval or flattened nuclei were recorded separately in young and adult animals.

15. In one case, the excretory duct was completely lined with goblet cells. The interlobular and intralobular ducts were of different diameters and were lined with a single

Rajendra Agricultural University, Bihar, M. Sc. (Vet.) Thesis, 1971

layer of cuboidal or low columnar cells with indistinct borders.

16. As a whole the glandular tissue was found to be richly innervated and highly vascularised.

17. Summarising the whole findings, these observations appeared specially interesting in view of the fact that most of the earlier workers described the lacrimal gland to resemble the true parotid salivary gland but in this study it was found to be almost resembling the submaxillary gland.

18. Histochemical observations revealed that the tissue of the gland was reactive for PAS. Stromal tissue were mildly while parenchyma was strongly positive. Some alveoli were completely reactive for PAS while some were completely devoid of it. Sometimes, even single alveolus gave a mixed reaction to PAS.

19. The lacrimal gland of Indian buffalo was weakly positive for glycogen. The nuclei of the alveoli, interalveolar connective tissue and basal portion of the cells were strongly positive.

20. The glandular tissue had complexes of polysaccharides, in which, the presence of acid mucopolysaccharides were demonstrated.

21. The gland was reactive strongly for proteins, and was moderately positive for protein-bound NH_2 group. The quantity of tyrosin was found to be negligible.

22. The parenchymal tissue was strongly positive for mucin. Mayer's mucihaematein stain proved most suitable for the demonstration of mucin. Alveoli were mixed in reaction.

23. Studies revealed the presence of DNA in the

Rajendra Agricultural University, Bihar, M. Sc. (Vet.) Thesis, 1971

nuclei of lacrimal gland of Indian buffalo.

24. No lipid or fat granules in the cytoplasm of the epithelial cells were observed. However, adipose tissue was demonstrated in frozen sections in the interlobular spaces.

25. Presence of calcium was not detected by von-Kossa's technique.

26. Alkaline phosphatase was not detected by using Gomori's technique.

****

Rajendra Agricultural University, Bihar, M. Sc. (Vet.) Thesis, 1971

LITERATURE CITED

Abel Jr., J.H., and R.A.Ellis 1966 Histochemical and electromicroscopical observation on the salt secreting lacrimal glands of Marine Turtles. Am. J. Anat., 118(2):337-344.

Arey, L.B. 1968 Human Histology. W.B.Saunders Company, Philadelphia.

Babaeva, A.G. 1966 Postnatal development of the submaxillary salivary and external orbital lacrimal glands in white rats. Byul. Eksp. Biol. Med., 61(5):173-175. (abstracted in Biological Abstract, 50(10):4897, 1969).

Bernard, L.S. 1965 Hawk's Physiological Chemistry. The Blackiston Division, McGraw-Hill Book Company, New York.

Bhattcharya, P. 1954 Animal Genetics; Silver Jubilee Souvenir (Dec. 1954)., I.C.A.R., N. Delhi 86.

Bloom, W., and D.W.Fawcett 1968 A text-book of Histology. W.B. Saunders Company, London.

Bolden, T.E. 1967 Age, a factor in growth of the exorbital lacrimal gland; - a Sigrid Juselius foundation Symposium on control of cellular growth in adult organisms. 4 to 6 october, Helsinxi, Finland Academic Press, London.

Bradley, O.C. 1923 The topographical Anatomy of the Head & Neck of the horse. W. Green & Sons, London.

_____ 1927 Topographical Anatomy of the dog. Oliver & Boyd, Edinburgh.

Bremer, J.E., and H.L.Weatherford 1948 A text-book of Histology. The Blackiston Company, Philadelphia, Toronto.

Bubyakina, M.S. 1967 Effect of removal of the (extraorbital) Lacrimal glands on mineral metabolism in classified tissues. PATOL. FIZIOL. EKSPTER., 11(2):68-70 (abstracted in Biological Abstract, 49:7864, 1968).

Burock, G. 1969 Morphological and histochemical studies on the Lacrimal gland of the Cat. Arch. Klin. Exp. Opth., 177(3):187-205 (abstracted in Excerpta Medica, sec.I., 24:122, 1970).

Carella, G. 1968 Comparative study of microvascular architecture of lacrimal gland (cat, dog, goat, sheep & rabbit). Ateneo. Paramense. Sez. Acta. Bio. Med., 39(6):653-680 (abstracted in Biological Abstract, 50:12606, 1969).

Rajendra Agricultural University, Bihar, M. Sc. (Vet.) Thesis, 1971

Carella, G., and C. Castelli 1868 The development of microvascularisation in the lacrimal gland. Ann. Ottal., 94(8):952--995(abstracted in Excerpta Medica, Sec.I., 24:30, 1970).

Carleton, H.M., and R.H.D.Short 1960 Schafer's Essentials of Histology. Green & Co., Ltd., London.

Catcott, E.J. 1952 Ophthalmoscopy in canine practice. J. Am. Vet. Med., 121:35-37.

Chauveau, A. 1891 Comparative Anatomy of the Domesticated Animals. J. & A. Churchil, London.

Copenhaver, W.M. 1964 Textbook of Histology. The Williams and Wilkins Company, Baltimore, U.S.A.

Cowdry, E.V. 1932 Special Cytology, Vol.I, Paul B. Hoeber, Inc., New York.

Culling, C.F.A. 1969 Handbook of Histopathological Techniques, Butter Worth's & Co., London.

Dass, B.B. 1966 Study on comparative anatomy of lacrimal apparatus in vertebrates; A Thesis for D.Phil (Med)., University of Calcutta, Calcutta.

Dawson, H.L. 1948 Lambert's Histology. McGraw-Hill Book Co., Inc., New York.

Diesem, C. 1968 Gross anatomic structures of equine and bovine orbit and its contents. Am. J. Vet. Res., 29(9):1769-1781.

Egeberg, J., and O.A.Jensen 1969 The ultrastructures of the acini of the human lacrimal gland. Acta. Ophthal., 47(2):400--410.

Ehinger, B. 1966 Distribution of adrenergic nerves in the eye and some related structures in the cat. Acta. Physiol. Scand., 66(1):123-128 (abstracted in Excerpta Medica, Sec.I., 36, 1967).

F.A.O. 1958 Quoted in " The Semen of Animals and Artificial Insemination ". Edited by J.P.Maule (1962). Commonwealth Agriculture Bureaux, Farnham Royal, Bucks, England. P. 184.

Fabel, H., O.A.J.Iens and K.D.Judith 1969 Mucosubstances of the acini of the human lacrimal gland (orbital part). Acta. Ophthalmol., 47(3):620-624.

Finerty, J.C., and E.V.Cowdry 1960 A Textbook of Histology. Iea & Febiger, Philadelphia.

Rajendra Agricultural University, Bihar, M. Sc. (Vet.) Thesis, 1971

Fleming, A., and V.D.Allison 1925 On the specifity of the protein of tears. Brit. J. Exp. Path., 6:87-90.

Gomori, G. 1950 Aldehyde-Fuchsin; a new stain for elastic tissue. Am. J. Clin. Path., 20:665-666.

Gray, P. 1958 Handbook of Basic Microtechnique. McGraw-Hill Book Co, Inc., Newyork.

Greep. R.O. 1954 Histology. The Blackiston Company, Inc., New York.

Gridley, M.F. 1951 A modification of the silver impregnation method of staining reticular fibres. Am. J. Clin. Path., 21: 897-899.

Grossman, G. 1937 Mallory Triple Stain (Grossman modification) Anat. Rec., 69:33-38.

Grossman, J.D. 1959 Student's guide to the dissection of the Bovine Edited by Prem Nath. I.C.A.R. Publication, New Delhi.

Gurr, E. 1962 Staining Animal Tissues Practical & Theoritical. Leonard Hill Limited, London.

Habel, R.E. 1955 Guide to the Dissection of Cow. J.W.Edwards, Publisher, Inc., Michigan.

Hafez, E. 1952 The Buffalo - A review. Ind. J. Vet. Sci., 22:257--264.

Hahn, J.D. 1969 Effect of cyproterone acetate on sexual diamorphism of the exorbital lacrimal gland in rats. J. Endocrinology., 45(3):421-424.

Ham, A.W. 1957 Histology. Pitman Medical Publishing Co., London.

_____ 1969 Histology. J.B.Lippincott Company, Igaku Shoin Ltd., Tokyo.

Ham, A.W., and T.S.Leeson 1961 Histology. Pitman Medical Publishing Co., Ltd., London.

Honssay, B.A. 1951 Human Physiology. McGraw-Hill Book Company, Inc, London.

Hyman, L.H. 1962 Comparative Vertebrate Anatomy. The University of Chicago Press, Chicago-Illinois.

Ithikawa, A., and Y.Nakajima 1962 Electronmicroscopic study on the lacrimal gland of the rat. Tohoku. J. Exp. Med., 77(2): 136-149. (abstracted in Excerpta Medica, Sec.I., 17:1161, 1963).

Jensen, O.A., I.F.Hansen, T.Jacobsen and A.Michelsen 1969 Mucosubstances of the acini of the human lacrimal gland;Histochemical identification. Acta. Ophthalmol., 47(3):605-619.

Rajendra Agricultural University, Bihar, M. Sc. (Vet.) Thesis, 1971

John, H.A., and A.E.Richard 1966 Histochemical and electronmicroscopical observation on the salt secreting lacrimal glands of Marine Turtles. Amer. J. Anat., 118:337-358.

Jones, R.M. 1950 McClung's Handbook of Microscopical Technique. Hafner Publishing Co., New York.

Jordan, H.E. 1952 A Textbook of Histology. Appleton-Century Crofts, Inc., New York.

Kato, Y. 1958 A histological study on the distribution of nerves in the human lacrimal gland. Japanese Jnl. of Ophthal., Vol.2 cited by Prince et al. 1960 Anatomy and Histology of the Eye and Orbit in Domestic Animals. Charles C Thomas, Publisher., Illinois.

Kessing, S.V. 1967 On the presence of mucous cells in the accessory lacrimal glands of human foetuses & new borns. Acta. Ophthalmol., 45(1):76-81.

Kharitonova, V.L. 1964 Anatomy of the human lacrimal gland. Makro--Micro-skopiche-skoi. Anatomii., 328-338 (abstracted in Excerpta Medica, Sec.I., 19:975-976, 1965).

Klein, E. and E. Noblesmith 1880 Atlas of Histology. Smith Edler & co., London.

Krestinskaya, T.V. 1966 Morphologic and physiologic characteristics of glands producing hypotonic secretion. Byull. Eksper. Biol. Med., 62(12):21-24 (abstracted in Excerpta Medica, Sec.I., 22:126, 1968).

Kriesten, K. 1968 Histochemical investigations of the external orbital gland of the white mouse. Acta. Histochem., 30(2):234-246 (abstracted in Excerpta Medica, Sec.I., 23:226, 1969).

Kronman, J.H., J.O. Donell and H.H.Chauncey 1968 A morphological and histochemical comparision of the golden hamster. J. Dent. Res., 47(2):207-213(abstracted in Biological Abstract, 49:8857, 1968).

Kuhnel, W. 1968a A comparative histological, histochemical & electronmicroscopical study of lacrimal gland - rabbits & cats. Z. Zellforch., 85(3):408-440 (abstracted in Excerpta Medica, Sec.I., 22:852, 1968).

_____ 1968b A comparative histological, histochemical & electromicroscopical study of lacrimal gland - The goat. Z. Zellforsch., 86(3):430-443 (abstracted in Excerpta Medica, Sec.I., 22:853, 1968).

_____ 1968c A comparative histological, histochemical & electronmicroscopical study of lacrimal gland in sheep.

Rajendra Agricultural University, Bihar, M. Sc. (Vet.) Thesis, 1971

Z. Zellforsch., 87(1):31-45 (abstracted in Excerpta Medica, Sec.I., 22:692, 1968).

Kuhnel, W. 1968d A comparative histological, histochemical and electromicroscopical study of lacrimal gland of cattle. Z. Zellforsch., 87(4):504-525 (abstracted in Excerpta Medica, Sec.I., 22:853, 1968).

———— 1968e A comparative histological, histochemical & electromicroscopical study of lacrimal gland in dog. Z. Zellforsch., 88(1):23-38 (abstracted in Excerpta Medica, Sec.I., 22:853, 1968).

———— 1968f Comparative histological, histochemical & electromicroscopical investigations on lacrimal gland VI The human lacrimal gland, Z. Zellforsch., 89(4):550-572 (abstracted in Excerpta Medica, Sec.I. 22:225-226, 1968).

Kuhnel, W., and G.Burger 1969 Cytochemical localisation of some hydrolases in three glands of the orbit in the rabbit; Lacrimal gland, infraorbital gland and harderian gland, Histochemic., 20:87-98 (abstracted in Excerpta Medica, Sec.I., 24:729, 1970).

Last, R.J. 1961 Eugene Wolff's Anatomy of the Eye and Orbit. H.K. Lewis & Co., Ltd., London.

Luciano, L. 1967 The ultrastructure of the lacrimal gland of the rats & its sexual dimorphism. Z. Zellforsch., 76(1): 1-20 (abstracted in Excerpta Medica, Sec.I., 21:538, 1967).

Luna, L.G. 1968 Mannual of Histologic Staining Methods of the Armed forces Institute of Pathology. McGraw-Hill Book Co., New York.

Magrane, W.G. 1957 Diseases of the orbit. Vet. Med., 52:449-451.

———— 1959 Canine Medicine. American Veterinary Publication, Inc., Santabarbera.

Makhijani, H.J. 1962 Milk and Milk Products. Gosambardhan., 9:24--30.

Mariano, S.H.D.F. 1967 Atlas of Human Histology. Lea & Febiger, Philadelphia.

Mariappa, D. 1958 Anatomy of the foetal Indian elephant. Part VIII: The Head & Neck. Indian Vet. Jour., 35:362-385.

Maximow, A.A., and W. Bloom 1958 A Textbook of Histology. W.B. Saunders Co., Philadelphia & London.

Michail, D., and P.Vancea 1931 Compt. Rend. Soc. de Biol.,108:277

Ralendra Agricultural University, Bihar, M. Sc. (Vet.) Thesis, 1971

(cited by Singh, B.K. 1962 Studies on the lacrimal and harderian glands of the Indian buffalo; a dissertation for M.V.Sc., University of Madras, Madras).

Micheluzzi, P. 1967 Orbital glands of the rabbit. Schweizer. Arch. Tierheilk., 109:171-182 (abstracted in Vety. Bulletin, 37:780, 1967).

Mortada, A. 1971 Tuberculoma of the orbit and lacrimal gland. Brit. J. Ophthal., 55(8):565-567.

Nair, K.S. 1951 Correspondence - for the buffalo. Ind. Vet. J. 27:49.

Nicolas, E. 1914 Veterinary and Comparative Anatomy. H. & W. brown, London.

Nikiforovae, H., and H. Colakov 1969 Growth and differencian of the epithelium of the lacrimal gland by means of transplantation in diffusion chamber. Folia. Med., 11(2):69-75 (abstracted in Excerpta Medica, Sec.I., 24:652, 1970).

Nonidese, J.F., and W.F.Windle 1953 Textbook of Histology. McGraw--Hill Book Co., Inc., New York.

Omulecka, D. 1962 The Golgi apparatus in the rabbit's lacrimal gland. Ophthalmologica., 144(3):165-174 (abstracted in Biological Abstract, 41:652, 1963).

Omuleka, D.K., and A.M.Okulist 1964 Morphological and histochemical investigations of the lacrimal gland cells. Klin. Oczna., 34(3):315-319 (abstracted in Excerpta Medica, Sec.I., 19:248-249, 1965).

Pearse, A.G.E. 1968 Histochemistry, Theoritical and Applied Volume I, J. & A. Churchill, Ltd., London.

Perfumo, G., and G.Sperati 1966 Regulation of the circulatory output of the wall of the lacrimal canaliculis. Arch. Ital. Octol., 77(6):853-863 (abstracted in Excerpta Medica, Sec.I., 21:706, 1967).

Ping, L.C. 1964 An electromicroscopic study of the guineapig lacrimal gland. Mem. Coll. Med. Taiwan Univ., 10:8-18 (abstracted in Excerpta Medica, Sec.I., 19:921, 1965).

Prasad, S.N. 1964 A Textbook of Vertebrate Zoology. Kitabmahal Private Ltd., Allahabad.

Prince, J.H., C.D.Diesem., I.E.Gilitis and G.L.Ruskell 1960 Anatomy and Histology of the Eye and Orbit in Domestic Animals. Charles C Thomas, Publisher, Illinois, U.S.A.

Raghawan, V. 1964 Anatomy of the Ox - I.C.A.R. Publication, New Delhi.

Rajya, B.S. 1956 Observations on an arterial plexus on the ophthal-

Rajendra Agricultural University, Bihar, M. Sc. (Vet.) Thesis, 1971

mic artery in a buffalo calf. Brit. Vet. J., 112(5): 188-190.

Robert, S.R. 1968 Canine Medicine. Ist Cat-Cott edition. American Veterinary Publication, Inc., California.

Roland, L.C. 1960 The electronmicroscopy of the myoepithelium in the rat exorbital gland. Anat. Rec., 137:45-55.

Roland, W. 1958 Age changes in the rat's exorbital lacrimal gland. Anat. Rec., 132:49-70.

Rubin, L.F. 1965 Chemical estimation of lacrimal function in dogs. J. Am. V. M. A., 147:946.

Ruskell, G.L. 1967 Vasomotor axons of the lacrimal glands of monkeys and its ultrastructural identification of sympathetic terminals. Z. Zellforsch., 83(3):321-333 (abstracted in Excerpta Medica, Sec.I., 22:358, 1968).

_____ 1968 The fine structure of nerve terminals in the lacrimal glands of monkeys. J. Anat., 103(1):65-76.

_____ 1971 The distribution of autonomic post ganglionic nerve fibres to the lacrimal gland - in monkeys. J. Anat., 109(2):229-242.

Sclare, G., and R.W.Luxton 1967 Fibrosis of the thyroid and lacrimal gland. Brit. J. Ophthal., 51:173-177.

Scott, B.L., and D.C.Pease 1959 Electron microscopy of the salivary and lacrimal glands of rat. Amer. J. Anat., 104:115-162.

Singh, B.K. 1962 Studies on the Lacrimal and Harderian glands of the Indian buffalo; A dissertation for M.V.Sc., University of Madras, Madras.

Sinha, R.D. 1965 A gross histologic & histochemical study of the eye adnexa of sheep & goats. Ph.D. Thesis, Michigan State University.

Sinha, R.D., and M.L.Calhoun 1966 A gross, histologic and histochemical study of the lacrimal apparatus of sheep and goats. Am. J. Vet. Res., 27:1633-1640.

Sisson, S., and J.D.Grossman 1962 The Anatomy of the Domestic Animals. Asia Publishing House, Bombay.

Smythe, R.H. 1958 Veterinary Ophthalmology. Baillere Tindall & Cox, London.

Spicer, S.S., and J.Duvenci 1964 Histochemical characteristics of

Rajendra Agricultural University, Bihar, M. Sc. (Vet.) Thesis, 1971

mucopolysaccharides in salivary and exorbital lacrimal glands. Anat. Rec., 149(3):333-358.

Suareznunez, J.M., and S.A.Tolosa 1964 Blood supply of lacrimal gland. Arch. Soc. Offal. Hisp. Amer., 24:65-70 (abstracted in Excerpta Medica, Sec.I., 19:34, 1965).

Sumner, A.T., and B.E.H.Sumner 1969 A laboratory mannual of microtechnique and histochemistry. Blackwell Scientific Publications, Edinburgh.

Sundwall, J. 1916 The lacrimal gland. Am. J. Anat., 20(2):147-235.

Trautmann, A., and J.Fiebiger 1957 Fundamentals of the histology of domestic animals. Comstock Publishing Associates, Ithaca, New York.

Vaughan, I. 1907 Strangeway's Veterinary Anatomy. Willium Green & Sons, London.

Venkovsky, T. 1964 Histo-enzymochemical study of the external lacrimal gland in the albino rat (alkaline phosphatase, acid phosphatase and succinodehydrogenase). Izv. Inst. Morfol., 9(10):193-206 (abstracted in Excerpta Medica, Sec.I., 19:824-825, 1965).

Vetter, H. 1969 Histochemistry and Capillarization of the duct systems of the goat salivary gland and the glandula lacrimalis extraorbitalis of the rat. Z. Anat. Entwicklungsgesch., 128(2):141-162 (abstracted in Biological Abstract, 50:11506, 1969).

Walker, W.F. 1970 Vertebrate Dissection. W.B.Saunders Company, Toronto.

Whitnall, S.E. 1921 The Anatomy of the Human Orbit and Accessory Glands of vision. Oxford Medical Publication, Hodder & Stonghton, London.

Wiedersheim, R. 1907 Comparative Anatomy of Vertebrates, Parker's Translation. Hodder & Stonghton, London.

Wolff, E. 1958 The Anatomy of the Eye & Orbit. H.K.Lewis & Co., Ltd., London.

Wood, F. 1946 Buchanan's Mannual of Anatomy. Bailliere, Tindall & Cox, London.

****

Rajendra Agricultural University, Bihar, M. Sc. (Vet.) Thesis, 1971