Studies On
Autogenous Skin Grafting in Bovine

Thesis
Submitted to the
RAJENDRA AGRICULTURAL UNIVERSITY, BIHAR
in partial fulfilment of the requirements for
the degree of
MASTER OF SCIENCE (VETERINARY)
1971

BY
Damodar Prasad Singh.
G. B. V. C. (Pat.), B. V. Sc. & A. H. (M. U.)
Junior Research Fellow
RAJENDRA AGRICULTURAL UNIVERSITY, BIHAR.
Post-Graduate Department of Surgery
BIHAR VETERINARY COLLEGE
P A T N A.

Studies On
Autogenous Skin Grafting in Bovine

Thesis

Submitted to the

RAJENDRA AGRICULTURAL UNIVERSITY, BIHAR

in partial fulfilment of the requirements for

the degree of

MASTER OF SCIENCE (VETERINARY)

1971

6091
15.5.72.

BY

Damodar Prasad Singh.

G. B. V. C. (Pat.), B. V. Sc. & A. H. (M. U.)

Junior Research Fellow

RAJENDRA AGRICULTURAL UNIVERSITY, BIHAR.

Post-Graduate Department of Surgery

BIHAR VETERINARY COLLEGE

P A T N A,

DEDICATED

to

my parents

for their high thoughts

and principles which

guided me in life.

Dr. A.A. Khan,
B.V.Sc. & A.H., M.V.Sc.(Madras), F.R.V.A.C.(Denmark),
Professor incharge and Head,
Post-Graduate Department of Surgery,
Bihar Veterinary College,
PATNA.

PATNA,

Dated, the 29th February, 1972.

I certify that this Thesis has been prepared under my supervision by Dr. Damodar Prasad Singh a candidate for the Degree of M.Sc. (Vet), with Surgery as Major subject, and it incorporates the results of his independent study.

A. Khan

(A.A. KHAN).

BIHAR AGRICULTURAL UNIVERSITY M. SC. (VET) THESIS 1971

Dr. A.A. Khan,
B.V.Sc. & A.H., M.V.Sc.(Madras), F.R.V.A.C.(Denmark),
Professor incharge and Head,
Post-Graduate Department of Surgery,
Bihar Veterinary College,
PATNA.

PATNA,

Dated, the 29th February, 1972.

I certify that this Thesis has been prepared under my supervision by Dr. Damodar Prasad Singh a candidate for the Degree of M.Sc. (Vet), with Surgery as Major subject, and it incorporates the results of his independent study.

A. Khan

(A.A. KHAN).

RAJENDRA AGRICULTURAL UNIVERSITY M.Sc. (VET.) THESIS 1971

ACKNOWLEDGEMENT

The author has no words to express his sincere gratitude to Dr.A.A.Khan, B.V.Sc.& A.H.,M.V.Sc.(Madras),F.R.V.A.C.(Denmark), Professor incharge and Head of the Department of Surgery, Bihar Veterinary College, Patna for his constant encouragement, constructive criticism,untiring supervision, lofty inspiration and invaluable suggestions and guidance, which has led to the completion of this work.

The author is deeply indebted to Dr. R.C.P. Yadava, M.Sc., Ph.D. (Mich, U.S.A.), Principal, Bihar Veterinary College, Patna for providing adequate facilities to carry out this study.

The author is also grateful to Dr. S.M. Ishaque, G.B.V.C. (Pat), P.G. (Germany), F.R.V.C.S. (Sweden), Ex-Principal, Bihar Veterinary College, Patna for providing facilities to conduct this study during the tenure of his principalship.

Warmest thanks are due to Dr. K.B.P. Agarwal, M.V.Sc., Assistant Lecturer, Dr. P.N.Sahay, B.Sc., B.V.Sc. & A.H., Assistant Lecturer and other staff of the Department of Surgery, Bihar Veterinary College, Patna for their timely help and other assistance provided, whenever needed.

The author also wishes to extend his sincere thanks to Dr. L.P.Singh, M.Sc.(Vet), Assistant Professor of Anatomy and Dr. Jagarnath Prasad, B.V.Sc. & A.H., Assistant Lecturer and other staff of Anatomy Department, Bihar Veterinary College,

Patna for their kind help in conducting the Histopathological study.

He is also thankful to his colleagues, Dr. N.R.Joshi, Dr. P.K. Samanta and Dr. M.N. Nassimi for their cordial co-operation and help rendered during this study.

Thanks are also due to the members of the staff of Art and Photo Section of Bihar Veterinary College, Patna for their invaluable help.

A deep sense of gratitude is extended to Professor R.N.Sinha, F.R.C.S., Head of the Department of Plastic Surgery, Patna Medical College Hospital, for his valuable suggestions, and keen interest shown for this experiment.

Grateful thanks are also due to the Vice Chancellor, Rajendra Agricultural University, Bihar, for the award of Junior Research Fellowship and other financial help to pursue this study.

The author is also thankful to M/s. Glaxo Private Ltd. for supplying Vitablend as free samples for use in experimental animals.

Last but not the least the author must thank his wife Smt. Usha Sinha for her sacrifice, patience and endurance which was essential to pursue the whole study.

(D.P. SINGH).

RAJENDRA AGRICULTURAL UNIVERSITY

Patna for their kind help in conducting the Histopathological study.

He is also thankful to his colleagues, Dr. N.R.Joshi, Dr. P.K. Samanta and Dr. M.N. Nassimi for their cordial co-operation and help rendered during this study.

Thanks are also due to the members of the staff of Art and Photo Section of Bihar Veterinary College, Patna for their invaluable help.

A deep sense of gratitude is extended to Professor R.N.Sinha, F.R.C.S., Head of the Department of Plastic Surgery, Patna Medical College Hospital, for his valuable suggestions, and keen interest shown for this experiment.

Grateful thanks are also due to the Vice Chancellor, Rajendra Agricultural University, Bihar, for the award of Junior Research Fellowship and other financial help to pursue this study.

The author is also thankful to M/s. Glaxo Private Ltd. for supplying Vitablend as free samples for use in experimental animals.

Last but not the least the author must thank his wife Smt. Usha Sinha for her sacrifice, patience and endurance which was essential to pursue the whole study.

(D.P. SINGH).

C O N T E N T S

	PAGE
INTRODUCTION.	1
REVIEW OF LITERATURE.	5
ANATOMY OF SKIN.	21
MATERIALS AND METHODS.	26
OBSERVATIONS AND RESULTS.... ...	39
DISCUSSION.	69
SUMMARY AND CONCLUSIONS.	82
REFERENCES.	i-xi

Number of Tables... ... 7.

Number of Graphs... ... 5.

Number of Figure... ... 1.

Number of Photographs. ... 29.

*****
***
*

INTRODUCTION

years later in Germany Dieffenbach (1792-1847) began his pioneer work in transplantation and experimental surgery in animals.

Baronio (1804) a Milanese physician obtained successful results with free full thickness autogenous skin grafting in a sheep. In that sheep, he carried out successfully a full thickness graft of a piece of skin as large as 12.5x7.5 c.m. Bunger (1823) was probably the first European surgeon, who performed successful free skin grafting of oval shape measuring 3x4" and transplanted it one and half hours after its removal. As cited by Converse (1962), Warren is supposed to be the first surgeon who performed skin grafting in U.S.A.

Significant findings of Baronio regarding skin grafting went unnoticed and little attention was paid to Bunger's report. It was only about half a century back that the free whole thickness skin grafting came into general use. Reverdin (1869), who is generally credited for stimulating the clinical use of skin grafting, reported the use of "Epidermic graft", otherwise known as "Reverdin graft". After that several workers (Ollier, 1872; Thiersch, 1874; Wolfe, 1875) developed different techniques of skin grafting, which are now known by their names in medical world.

In last two decades, several authors (Billingham and Medawar, 1951; Woolsey and Schaffer, 1952; Jensen, 1959; Spreull, 1962; and Bromberg, 1964), described, after study on experimental and clinical cases, the different techniques of skin grafting in animals.

In clinical cases skin grafting is indicated in wounds

involving a loss of skin so extensive as to preclude the possibilities or likelihood of epithelization of the denuded area by ingrowth occuring from the border of the wound. In cases of thermal burns, when vital organs like udder, joints etc. are involved and where there is complete loss of skin on larger surfaces and epithelization of such part becomes necessary, there the only alternative procedure, to achieve perfect functional cure is skin grafting. Because, the conventional method of healing i.e. by granulation tissue, leads to cicatricial scarformation resulting in contracture of the part concerned. Sometimes after removal of big tumours, the problem of primary closure arises, owing to insufficient skin present at the site of wound, where skin grafting can very well serve the purpose.

Spreull (1962) pointed out that patients presented with wounds of skin outnumbered those suffering from any other individual condition or disease and a good number of these wounds caused extensive skin damage. Secondary skin loss also frequently occurs as a result of gross bacterial infection and consequent necrosis, especially in cases where there has been severe contusion of the skin. Such cases also demand skin grafting. Injury of skin on limbs and face of cattle due to wire cuts, laceration from loading and unloading in trucks, trailors and boats etc. presents many problems, as the amount of skin adjacent to defect is limited which cannot be slided over to cover the wound. The frequent slow rate of normal healing, and tendency to excessive granulation of wound, hampers the satisfactory repiar within a reasonable time. To overcome these difficulties skin grafting is the best solution.

It is an admitted fact that the autogenous skin graft is

the most successful type of skin graft as the donor and recipient areas are of identical antigenic makeup. So the percentage of "take" is high, if all surgical precautions and procedures are followed strictly. The autogenous skin graft is of two types i.e. free graft and attached graft.

Skin grafting is a widely used technique in human surgery, but its use in veterinary surgery is negligible because of certain limitations.

Although, various types of skin grafting have elaborately been tried clinically and experimentally in horse and dog, yet there is very little evidence of this work being conducted in bovine. Keeping in view the great economic importance of bovine species in India and paucity of literature on use of skin grafting in this species of animal, the author has been tempted to undertake the present study of autogenous skin grafting in bovine.

Therefore, the present work has been designed to study the different techniques of skin grafting, such as Pinch or seed graft, Split thickness graft, Full thickness graft and Pedicle graft, to determine how far these techniques would be useful to treat the cases of extensive wounds in bovine, under environmental condition of this country.

*****
***
*

REVIEW OF LITERATURE

REVIEW OF LITERATURE

Available relevant literatures, related to the study undertaken have been briefly reviewed hereunder.

Skin grafting is a very valuable and old procedure for covering large wounds. It was practised in ancient India and Egypt. Carpue (1816), a British surgeon reported two cases of restoration of the nose by the Indian method of skin grafting.

Bunger (1823) used ancient Indian method to repair the nose of a 33 year old lady, in which he took full thickness skin graft from her thigh.

Although as early as 1804 Baronio successfully carried out free skin grafting in sheep, but previously little importance was given to this aspect of treatment of extensive skin damages. It was only after world war II that plastic surgery developed tremendously and by now it has made considerably rapid strides in human surgery. The use of skin grafting to treat a large and extensive wound is still not very much in vogue in the field of veterinary profession.

Surgeons, both in the field of veterinary and human surgery, have published a lot of papers but their works are mainly limited to mice, rabbits, dog, horse and other experimental animals. But so far, bovine surgery is concerned, very little work has been done. Since much work has been done in human surgery, so a lot of references have been cited from those works.

Blair (1924) advocated the superiority of the full

thickness skin grafting, while summarising his routine methods of skin grafting in human cases. He said that though the result of full thickness graft was uncertain but it was better than either the pedicle or the split thickness skin graft.

Davis and Traut (1925) performed full thickness skin grafts on dogs and observed that the blood supply established in grafted skin was as follows :-

(a) by anastomosis of small capillaries;

(b) by upward growth of capillaries inside the old vessels and

(c) by invasion of capillaries from host tissue.

He further stated that circulation sufficient to maintain the graft was established on the 8th day.

Douglas (1930) described the method of transplanting relatively large full thickness graft which he first devised and used in the year 1928. He called it a "seive graft" method because the graft was uniformly perforated with small round openings. The advantage of the method to which he drew attention was that it provided for adequate drainage, prevented accumulation of serum or exudate between the graft and the under lying bed and afforded better opportunity of overcoming wound infection.

Self (1934), while dealing with the importance of skin grafting in canine practice, described that there were innumerable indications of skin grafting, such as chronic ulcers, surfaces left by burns, by fire or acids and surfaces left without skin by

traumatism.

Dragstedt (1937) described a simple practical method for using full thickness skin graft to cover selectively large wounds. The method he described, utilises the seive graft principle of Douglas (1930).

Davis (1940) reported his own experience regarding the use of small deep graft in the repair of surface defects. He stated that the healing was stable, strong and permanent if the grafts were used in proper way. He used deep graft with greatest satisfaction and found the method indispensable while dealing with large losses of surface tissue and in solving some of the complicated problems of wound healing.

Brown and Mc Dowell (1941) observed that functions were found to persist in large skin grafts which remained in places during long period of growth. Both thick split and full thickness grafts do seem to grow or at least stretch out with the growth of the body to permit normal movement.

Brown and Mc Dowell (1942) reported that homografts took in the same way as auto-graft and survived from 3 to 10 weeks. During this period the patient was given rest, his general condition improved and there was a stimulus to his own epithelization so that complete healing might occur even after absorption of the homograft. They further stated that there did not seem to be any relationship between the "take" of a homograft to the blood group. Homografts in identical twin had been shown to survive permanently.

Brown and Mc Dowell (1942) further studied the epithelial

healing and transplantation of skin in close association with the clinical picture of the requirement and possibilities of repair in large number of petients. They studied the reasons for wound healing, the spontaneous repair of donor site of graft, the behaviour of homografts and many other points by microscopic studies of the sections of the tissues involved. They observed that skin was a complex organ and the epithelium was the only part which regenerated. The pad of the derma which gave bearing protection did not regenerate.

Converse (1942) reported that skin grafting of infected granulating wounds following secondary debridement and local use of sulphanilamide powder had enhanced success in percentage of skin graft "takes", estimated at 88% in 56 cases. In wounds caused due to compound fracture, skin grafting was performed successfully, in general practice.

Medawar (1944) mentioned that the natural process of wound healing was always necessary, but not always sufficient to secure on efficient functional repair of damaged tissue. For such cases skin grafting operation was a foolproof solution.

King (1945) described that through the use of skin grafting many open wounds could be converted into close wounds and thus primary healing obtained. Primary healing means a tremendous economic saving as well as decreased pain, improved functions and superior cosmetic results.

To obtain a greater success for the sake of better results he advised that all the dirty wounds should be surgically

cleaned before grafting. Grafts must be placed and held in firm apposition with the underlying tissue. The most common cause of failure of skin grafting were :-

(a) Infection.

(b) Blood or serum pockets beneath the graft.

(c) Inadequate contact between the grafts and its bed.

(d) Improper or inadequate anchorage of the graft, so as to allow movement during the healing period.

Keef (1946) performed the delayed and immediate tube graft in cat. In immediate tube graft he observed that lower portion of the graft sloughed out within a week but this defect was very much minimised by delayed tube graft.

Handfield - Jones and Porritt (1948) suggested that skin grafting should be done as soon as possible where there is extensive loss of tissues. He further reported that mild sepsis was no barrier to successful skin grafting but pinch grafts were giving better results than Theirsch graft in cases of severe infection.

Padgett (1948) described that after autotransplantation of skin, the repair was somewhat analogous to that of the repair of an ordinary incised wound. The graft was first fixed in place by the exudate of fibrin within five hours after transplantation. The graft became adherent to its base. The fibrin layer was soon infiltrated by leucocytes and phagocytes. A primary stage of plastic circulation, which varied from 24 to 48 hours temporarily preserved the viability of the graft.

He further stated that the histologic picture of the full thickness graft did not differ materially from that of thinner grafts. The process of degeneration and regeneration was slightly more rapid in thinner grafts. He observed that within two to three months, a layer of fat began to develop beneath the graft, the cellular infilteration disappeared and fibrous tissue layer decreased in width and amount. The fibroblasts began to lengthen. The skin then gradually became movable and pliable on its base.

Barsky (1950) stated that grafted tissue behaved as parasitic structure until the circulation was not fully established in it. Therefore, post-operative immobilisation was an absolute necessity. Particularly for full thickness graft, he further advocated strict aseptic precautions and gentle handling to prevent additional injuries to the grafted tissues.

Billingham and Medawar (1951) reported that the pinch graft took longer time to heal soundly but gave cosmetically and functionally better results. On the other hand split thickness graft being devoid of hair follicles failed to regenerate a normal crop of hairs. They also advocated the practice of "no touch" technique in operation of skin grafting.

Out of seven cases of excessive granulating wounds, Woolsey and Schaffer (1952) obtained successful results by buried split skin graft in five cases. They claimed that it was not necessary to take any special effort towards sepsis.

Moraes and Ribeiro (1953) used whole thickness skin grafts for treatment of primary or recurrent hernia including

full thickness, split thickness, tube graft and small buried graft and found that none of the grafts were uniformly successful for all the areas of the dog's body nor for all kinds of skin lesions. Restraint, maintenance of a satisfactory pressure bandage and prevention of contamination of the grafted area appeared to be the greatest difficulties, which he encountered in his study.

He found delayed tube graft most successful for lesions of the extremities whereas free full thickness graft, though difficult to accomplish did well for lesions free from contamination. Small deep grafts, although easy to perform, did not give good cosmetic appearance, since it resulted in a "cobble stone" or pitting effect at both donor and recipient sites. Scaling was observed in the split thickness graft which was lacking resistance to trauma. For getting rapid results he used antibiotic in almost all cases.

Hogle et al (1959) used different techniques of skin grafting both in fresh and granulating wounds of 61 horses with special emphasis on split grafting. They used antiseptic packs on recipient area one day prior to operation and applied antibiotic on the edges of grafted skin to combat infection. A pack soaked in physiological saline was used and was impregnated daily with saline solution with a view to prevent dislodgement of the deeper layer along with bandage. They further observed that the hair growth was sparce on grafted area and remained scaly owing to lack of functional sebaceous glands. As regards full thickness graft, they concluded that this technique was more difficult to achieve success, whereas the later suffered less necrosis in comparision

eventration of the abdominal wall in one hundred three cases. Penicillin was administered in all patients for three days, one pre and two post operatively. They concluded that whole thickness skin grafting gave the best result in hernia and eventration of the abdominal wall.

Gibbens (1957) used a thin strip of skin (3"x6") as skin transplant to repair the ruptured anterior cruciate ligament.

Neal (1958) using woolsey and Schaffer's method performed 3 operations of skin grafting in horses. Two were successful. He concluded that the technique has a useful application in the treatment of granulating wound.

Higgins and Orr (1958) described that the area to be grafted should be free from active infection. They further said that accurate contact between the graft and the underlying bed was essential. The graft that moved frequently did not heal properly, so grafted area should be perfectly immobilised. They also discouraged the use of strong antiseptic either on donor area or on the recipient area.

Franklin et al (1959) after conducting experiment on rats, described a method in which Michel clips were used to secure homografts in position. One thousand animals were successfully grafted by this technique. They preferred it to save the graft from unnecessary trauma by suture.

Jensen (1959) performed 98 autogenous skin grafts in dog by using four different techniques. The techniques he used were

full thickness, split thickness, tube graft and small buried graft and found that none of the grafts were uniformly successful for all the areas of the dog's body nor for all kinds of skin lesions. Restraint, maintenance of a satisfactory pressure bandage and prevention of contamination of the grafted area appeared to be the greatest difficulties, which he encountered in his study.

He found delayed tube graft most successful for lesions of the extremities whereas free full thickness graft, though difficult to accomplish did well for lesions free from contamination. Small deep grafts, although easy to perform, did not give good cosmetic appearance, since it resulted in a "cobble stone" or pitting effect at both donor and recipient sites. Scaling was observed in the split thickness graft which was lacking resistance to trauma. For getting rapid results he used antibiotic in almost all cases.

Hogle et al (1959) used different techniques of skin grafting both in fresh and granulating wounds of 61 horses with special emphasis on split grafting. They used antiseptic packs on recipient area one day prior to operation and applied antibiotic on the edges of grafted skin to combat infection. A pack soaked in physiological saline was used and was impregnated daily with saline solution with a view to prevent dislodgement of the deeper layer along with bandage. They further observed that the hair growth was sparce on grafted area and remained scaly owing to lack of functional sebaceous glands. As regards full thickness graft, they concluded that this technique was more difficult to achieve success, whereas the later suffered less necrosis in comparision

with split graft.

Rogers (1959) described three types of skin grafts, namely auto, homo and hetero grafts. In auto graft the skin was obtained from one part of the body and transplanted to another part of the self same body. In homo graft skin obtained from one individual of the same species e.g. rabit to rabit and in hetero graft the skin obtained from individual of one species to an individual of another species, e.g. Guinea pig to dog, chicken to rat.

Vrubel et al (1959) observed that the chlortetracycline, when applied on skin grafts, increases the percentage of "take". He applied chlortetracycline in auto grafts of varying thickness.

Hughes (1960) after reviewing the structure of mammalian skin remarked that the advances in domestic animal's dermatology were far behind as compared to the human dermatology.

Neal (1961) again treated eight cases of horse by the same method of Woolsey and Scaffer (1952) with success in five. He observed in the successful cases that the epithelium covering the wound was at first delicate but with time became progressively more robust. For this he advised that the wound should be protected during the early period of epithelization by application of stable bandage.

Converse (1962) stated that autografts were usually successful when the technical details of the transplantation were followed carefully, whereas homografts were rejected on account of immunological response, known as homo graft reaction. He further

said that two methods of auto grafts were employed, the mediate and immediate. In immediate transplantation of skin a portion of skin is completely severed from its vascular connections, revascularisation of the transplant occurs by the penetration of new endothelial levels from the site of implantation. In mediate transplantation of skin the survival of the transplant is insured by a pedicle thus termed as pedicle flap.

According to Gius (1962) the skin grafts are extensively employed to cover cutaneous defects. They may be of "split thickness" including the epidermis and a portion of the dermis or of "whole thickness", including all of the dermis and epidermis. In general, the thinner the skin transplant, the greater are its chances of survival, but the thicker the transplant, the better the functional and cosmetic result will be.

When a skin transplant is placed on a recipient bed, which may be either granulation tissue or raw tissue, it is at first not attached to the underlying surface. Then fibrin, which is deposited between the bed and the transplant, binds the surfaces by conglutination. Maximal conglutination is usually attained in about seven hours. Until the graft is anchored by ingrowing blood vessels and collagen strands, it is in the parasitic phase of transplant existence. In skin, this is usually about forty eight hours.

Hickman et al (1962) studied on the storage of foetal sheep skin and its growth as an auto graft on lamb and observed that the stored skin grafts survived on lambs and expanded rapidly.

Unwin (1962) reconstructed the left two teats, which were conjoined for two third of their length, in a 2 year old Red poll heifer by mobilising pedicles from the lateral aspect of the udder. The teats were seperated by thermocautery and four skin flaps were then mobilised from the lateral aspect and sutured so as to draw the teats apart and introduced one inch of skin between them. The operation was done under chloral hydrate narcosis.

Spreull (1962) recommended the tube graft for repairing defects on the trunk, neck and extremities. He compared the pedicle and free graft and observed that the later had the advantage as the major defects could be repaired where transplantation of flap and tube was difficult. He used light plaster cast as a routine method for immobilisation of grafts.

Wallace et al (1962) performed full thickness graft in dog and bandaged after applying sterile paraffin gauze on the graft. A small portion of the graft did not take which was regrafted by Spreull (1962) with a modification, that instead of paraffin gauze dry dressing was applied and immobilised with light plaster cast. They reported that full thickness and pedicle grafting were the two methods by which sound repair of major defects could be achieved. But pedicle graft required careful and skillful design and was tedious, hazardous, lengthy causing a considerable discomfort to the animal.

Clinically, all sorts of procedures may be used for grafting skin varying from snips of the outer coats (Reverdin or pinch grafts) which sticks on a granulating wound to large masses

of skin and subcutaneous fat (full thickness grafts) which are used for covering denuded area (Markowitz, 1964).

Bromberg et al (1964) performed 50 split thickness grafts in yorkshire pigs. He used a plastic adhesive to affix the grafts to avoid unnecessary trauma caused by conventional repair of tissue with sutures. No significant difference in sound healing was observed between sutured graft and plastic adhesive fixed grafts, but application of plastic adhesive to exposed part of either grafts or recipient bed resulted in immediate tissue damage and sloughing.

Archibald (1965) observed that skin grafting was likely to be unsuccessful, if the hamoglobin level of the patient was low. He further described that the principles of plastic surgery were the same as those of general surgery, but in addition to surgical attitude the plastic surgeon should possess the quality of an artist. These qualities would be beneficial not only in aiding him to design various incisions but is invaluable in permitting him to visualise the eventual outcome of his procedure.

The ease with which skin can be acquired, makes its grafting the most commonly practised procedure in plastic surgery. The repair of defects with skin utilises basic surgical principles. Skin can be used in its entire thickness (full thickness graft) or only a portion of the thickness of the skin may be utilized (Cowley, 1965).

Chanana et al (1966) studied the skin graft reaction in calves by light microscope and observed that in all grafts

the superficial portion of the epidermis seperated as a "Ghost" graft. In auto grafts there was minimal vacuolization of epithelium, some karyorrhexis and slight to moderate proliferation of connective tissue around hair follicles were observed.

Vaughan and Scott (1966) conducted series of experiments to study the fate of whole thickness skin auto grafts used to replace the anterior cruciate ligament in goat and advocated that the skin could be used with confidence as substitute for joint ligaments, not only in the stiffle but for the stabilization of other joints in preference to the use of steel wire or synthetic fibre.

Boyd (1967) applied 24 full thickness and 24 split thickness skin grafts at various sites on horses leg. Out of 24 full thickness grafts 18 survived and out of 24 split thickness grafts 16 were successful. He observed that pigmented hair covered grafted surface had a much better cosmetic appearance than the cicatrix produced by granulation. The most desirable cosmetic effects were produced by the full thickness skin transplants. An uniform skin covering developed in a shorter period on grafted lesions than those allowed to heal by cicatrix formation.

Deokiouliyar (1967) applied four types of grafts on 39 surgical wounds in canine and observed that :

(a) Free full thickness graft was relatively successful with good cosmetic results, but infection appeared detrimental for this graft.

(b) Delayed tubed pedicle graft offered the most satisfactory result and appeared suitable for the lesions of the extremities but lack of loose skin to cover the area from where the skin was used for preparation of tube, limited this method to small areas.

(c) Success achieved in the split thickness was not satisfactory and was objectionable cosmetically due to negligible growth of hairs and leathery appearance of the skin.

(d) Pinch graft was easy to perform but it did not provide a smart appearance at donor as well as at the recipient areas. This graft appeared resistant to infection and gave good results even on infected lesions.

Ross (1968) recommended seed grafts to cover granulating or contaminated wounds. Split thickness was recommended when insufficient skin was available for transplantation. He observed that both types were weak and unsightly when healed. Pedicle grafts were found highly successful but were difficult to perform and graftable areas were limited by skin availability. Free full thickness grafts were the most useful type for canine wound closure. They were easily placed on any surface wound and were tough, grow hair well and were cosmetically very much satisfactory.

Smith and Markes (1968) employed simple skin grafting technique for speeding the epithelial covering of large and slow healing wounds in horses. The technique consisted of collecting

small pinches of skin from a donor site and implanting them in surgically prepared pockets scattered over a granulating wound surface. Eleven wounds on seven horses were grafted by this method. They claimed that healing time in extensive wounds could be shortened by as much as 80%.

Dogneli (1969) performed experimental skin grafting on 10 teats of three cows. Full thickness skin grafts and small deep grafts were successful, but four of the five teats with tube grafts showed good results and were suitable for milking after 12 days.

Ham (1969) described, when total thickness of the skin was destroyed, say by severe burn there was no way for the epidemis to become regenerated, except for it to grow from the edges of the denuded area from one side to the other. If the denuded area was large, the growth of epidermis from its edges was impracticable. About split thickness graft he said that the split thickness graft was a saving cut of skin and when this piece of skin was placed on a raw surface it got its nourishment from the tissue fluid of the raw surface, and in due course connective tissue cells from its bed would grow to form new intercellular substance to attach it. In course of time, it would become vascularised. He further studied the vascularisation of full thickness graft by means of injection experiments in pig and observed that the capillaries of the graft and capillaries in its bed soon become joined and by 7 days blood would be found flowing again in the larger vessels of the graft, which must have remained alive by diffusion phenomena. Full thickness grafts were used

for better cosmetic appearance. It was of interest to note that the old vessels of the graft were used again.

Pullen (1969) treated successfully a case of extensive skin laceration on the left lateral thorax of a dog by sliding "H" full thickness skin flap and described that, wounds and other large skin defects in animals were often left to heal by second intension, which causes contraction of the part concerned, whereas in many cases surgical repair or reconstruction would result in much faster recovery and a more desirable cosmetic appearance.

Goel and Nayak (1971) designed a simple trephine for cutting skin grafts. The sharp edge of the instrument cuts the skin pieces of definite size and depth without much pressure on the animal.

Sahu and Singh (1971) performed pedicle full thickness skin grafting in a bullock to cover large denuded area of the base of horn and observed uneventful healing.

Boyd and Hanselka (1971) developed an easy and effective skin grafting procedure that used a skin punch technique for applying free full thickness auto grafts. This method was designed for use primarily on wounds of the lower part of the limb that have extensive loss of skin and excessive granulation tissue. The survival rate of the grafts on 7 horses ranged from 75 to 95%.

ANATOMY OF SKIN

ANATOMY OF THE SKIN

Gross :

The skin forms the outermost covering of the body. It is highly elastic, resistant structure which varies in thickness at different parts of the body of the same individual and aslo with sex and age. It contains the peripheral branches of sensory nerves, and is essentially an organ of the sense of touch (Sisson and Grossman, 1962).

After covering the entire body it becomes continuous at the margin with the mucous membranes of natural orifices viz., digestive, respiratory, urinary and genital tracts. It forms into folds in certain parts, which are effaced and refaced by movement, The skin remains attached to the underlying structure by subcutaneous tissue. The subcutaneous tissue contains variable amount of fat in its meshes. The skin is lossely attached to the underlying structure where subcutaneous tissue is in abundance and closely attached where it is thin. Next to the skin striped cutaneous muscles are placed. Fibers of these muscles are inserted in skin in the region of trunk (Raghavan, 1964). The skin performs many important functions. It protects the body from injurious substances, helps in the regulation of the body temperature, constitutes the most extensive sense organ of the body for reception of the tectile, thermal and painful stimuli, in addition it also acts as an organ of excretion and excretes water, fat and some other metabolic waste products of the body (Copenhaver, 1964).

The thickness of the skin varies with age and sex. It is thicker on the back, extensor surfaces of the limbs than on the belly and the flexor surfaces.

Microscopic structure :

Microscopically the skin consists of two main parts:

(a) Epdermis.

(b) Dermis or corium.

The epidermis is a stout epithelial layer derived from the ectoderm, and corium is a connective tissue derivative of mesoderm.

(a) Epidermis :

The epidermis is characterised by a high degree of elasticity. It has two main layers.

According to Trautmann and Fiebiger (1957) the epidermis is divided into the succulent deep layer and superficial horny layer. Further the deep layer is subdivided into two and superficial layer in three, secondary layers.

From outside in upto dermis the layers are as follows:

Superficial layer :

1. Stratum corneum : - It is the cells of outermost layer, they are usually flat, but may at times be swollen and vesicular. They exhibit short tooth like processes in place of the intercellular bridges and contain in their cornified peripheral layer the true horny substance, keratine. The nucleus is absent, and the interior of the cells often appear empty or dried

to a fine mesh work. The cells are dead and are shade as scabs.

2. Stratum lucidum : - It is next layer of shiny non-nucleated flattend cells of homogenous appearance and the bounderies of which are obscured.

3. Stratum granulosum : - It consists of one to five layers of fusiform serrated cells. The stratum granulosum and stratum lucidum may be found missing in the thin epidermis.

Deep layer :

This layer is also known as stratum germinativum or Malpighi, which is further subdivided into Stratum spinosum and Stratum cylindricum.

(1) Stratum spinosum or prickle cell layer : - It consists of stratified prickle cells. These cells are connected by intercellular bridges and fill in all the depressions between the dermal papillae.

(2) Stratum cylindricum : - Consists of a layer of columner cells of varying hight which produce most of the epidermis.

The cells and intercellular bridges of the Malpighian layer are traversed by cytoplasmic fibrils known as Tonofibrils which reinforce the epithelium.

Odland (1966) described two layers in human skin regardless of its thickness. The outer layer of non-nucleated cells called stratum corneum and the inner layer of moist viable cells, called stratum germinativum.

Singh et al (1971) also observed two layers in the buffalo skin of dorsal region, i.e., stratum corneum and stratum germinativum. According to their findings the stratum germinativum was further differentiated into stratum cylindricum and stratum spinosum.

DERMIS OR CORIUM

On the basis of the direction of their bundles two layers are recognised in dermis, they are papillary and reticular layer.

(1) Papillary layer :- In this layer, the fine collagenous bundles are densely interwoven. The surface of this layer bears cone shaped papillae which usually contain capillary loop. The shape of papillae varies. There are simple papillae, which may be long and slender or short and thick. Others are large and have bifurcated ends. Some papillae branch into more than two cone shaped processes, giving rise to compound papillae.

(2) Reticular layer :- It is deeper and heavier layer of the dermis. Here the thick fiber bundles interweave mainly in a horizental plane.

Glands of the skin :

According to Raghavan (1964) two types of glands are found in skin. They are sebaceous gland and sweat gland. Sebaceous glands are small and sacculated, and their ducts open into the hair follicles. Though they are mostly associated with hairs,

they are also found in regions where there is no hair e.g. lips, vulva, anus, and prepuce. These glands secretes a greasy substance, the sebum cutaneum.

The sweat glands are placed on the under surface of the corium. They are small, rounded or oval reddish bodies. The secretory part consists of a convoluted tube, from which the duct of the gland proceeds upwards through the dermis and the epidermis and opens on the surface of the skin by a funnel shaped orifice.

Blood supply to skin :

In skin the arteries inter communicate freely. In the deeper part of the corium they form plexus and another net work is formed under the papillae. Small vessels form the deep plexuses and go to the fat and sweat glands, and the subpapillary plexuses send fine branches to the papillae, hair follicles and sebecéous glands.

The vein forms two plexuses one beneath the papillae and other at the junction of the corium and subcutis.

The lymph vessels form subpapillary and subcutaneous plexuses.

Nerve supply :

The nerve supply to skin varies widely in number in different parts of the skin. The terminal fibers either end freely in the epidermis and in certain parts of the corium, or form special microscopic corpuscles of several kinds.

*****

MATERIALS AND METHODS

MATERIALS AND METHODS

MATERIALS

SELECTION OF EXPERIMENTAL ANIMALS :

For the present study sixteen male buffalo calves, representing bovine species were obtained from the experimental animal supplier of the Bihar Veterinary College, Patna. The animals selected were apparently healthy and in fairly good condition. All the animals were kept under personal and keen observation and common environmental condition for a week. During this period all preliminary routine examinations were carried out to ensure that the animals used for experiments were reasonably healthy, free from ectoparasites and skin diseases. The average age and weight of the animals varied between 12 to 24 months and 250 lbs. to 300 lbs. respectively.

SUTURE MATERIALS :

Non absorbable black braided silk size 3 and 4/0 were used in this experiment to suture the graft as well as to close the donor site.

NON ADHESIVE PARAFFIN GAUZE :

Jelonet, (Smith and Nephew Ltd.) non adhesive dressing gauzes were used to cover the graft just after operation.

VELROC :

Velroc (Johnson and Johnson) bandages were applied in some of the cases to immobilise the grafts as light plaster casts.

JOHNSON AND JOHNSON ADHESIVE TAPE :

Adhesive tape was also used in some of the cases to immobilise the graft.

DESIGN OF THE EXPERIMENT :

Sixteen animals under study were randomly divided into four groups consisting of four animals in each group. The four groups were allotted to four different methods of skin grafting randomly. Two experiments were carried out in each animal. Thus the total number of grafts added to thirty two.

In this experiment four techniques of skin grafting, as given below were taken up for study.

(1) Free skin grafting:

(a) Pinch graft.

(b) Split graft.

(c) Full thickness graft.

(2) Attached skin grafting:

(a) Pedicle graft.

In these particular experiments observations were carried out with special reference to percentage of viability of each

graft, pliability of graft, hair growth, resistance to trauma and histopathological changes at the junction of graft. Grossly the grafts were observed for changes on 14th, 21st and 28th post-operative days. The period of observation lasted for 30 days after the date of operation, and then the animals were sacrificed and materials collected for histopathological study.

M E T H O D S

PRE-OPERATIVE CARE :

The animals were kept under personal and keen observation for a week prior to surgery. They maintained in identical environment so far as feeding and management was concerned. Ad-lib feeding of paddy straw and green fodder were given in addition to the normal grazing.

Gamexene was applied externally on skin against ecto-parasites. Deworming in all the buffaloe calves were done by Phenothiazin (I.C.I.) irrespective of their stool examination results.

PRE-OPERATIVE PREPARATION:

Clinical Examination:

The following clinical examinations were carried out on each animal prior to surgery, in order to ensure that the animals were free from any disease.

Recording of temperature, pulse and respiration :

Temperature, pulse, and respiration were daily recorded

both morning and evening for 7 days pre-operatively (Table No. 6).

Faecal sample examination :

The faecal samples from the experimental animals were examined for endoparasitic infestation and the positive cases were treated accordingly.

Haematological examination :

Appraisement of the blood constituent (Hb %, total count of R.B.C., W.B.C. and differential count of W.B.C.) was done to rule out anaemia and any blood borne parasite. Nothing significant was found (Table No.5).

Preparation on the previous day of operation :

The animal was given a general bath with 5% carbolic soap and tap water.

Selected sites for donor and receipient area :

The common sites selected were medial, lateral and dorsal aspect of metacarpal, and radioulnar region in fore limbs, tibial and metatarsal region in hind limbs and lateral wall of thorax. These sites were selected only due to their suitability to keep and maintain the plaster or bandage in position to protect the graft post-operatively with ease.

Preparation of donor site :

The donor sites were clipped closely and shaved cleanly

taking utmost care so as to avoid any nick or abrasion on the skin surfaces and scrubbed well with 5% carbolic soap and water. Thereafter, the sites were completely dried with sterile towel and painted again with solvent ether for defattening of external surface of the skin and allowed to dry. Finally, painted with Spt. mercurochrome 1% solution and covered with sterile bandage.

Preparation of receipient sites :

The receipient sites were also prepared in the same way as the donor area and covered with sterile bandage. The animals thus prepared were kept in a separate stall on light food and water.

PREPARATION ON THE DAY OF OPERATION :

Sterilization of the instruments and appliances :

The instruments, drapes, towels, gauze, cotton, bandage and other necessary appliances were sterilised in autoclave under 15 lb. pressure at a temperature of 120°C for 30 minutes. The Bard Parker blade and skin grafting knife were sterilised in concentrated solution of Dettol.

Scrubbing of the surgeon's hand with 5% carbolic soap and water followed by washing with dettol lotion was done as a routine procedure.

Preparation of animals :

The temperature, pulse, and respiration were recorded

prior to operation. The bandage of donor and receipient areas were opened and again scrubbed well with soap and water dried with sterile towel, swabbed with ether and finally painted Spt. mercurochrome 1% and covered with sterile drapes.

Anaesthesia :

All the animals were invariably drenched with chloral hydrate 3 to 4 drammes with treacle according to their body weight as narcotic agent, half an hour prior to operation. Sevicaine 2% (Glaxo) was used as local anaesthetic to anaesthetise the donor and receipient sites in all cases.

Positioning of the animal during operation :

The animals were casted either in left or right recumbency, as per suitability to keep the operative site uppermost. Afterwards, the animals were secured by tying the opposite legs together and as such maximum exposure of the operative sites were achieved.

OPERATIVE PROCEDURE :

The site of operation was finally painted with 1% Spt. mercurochrome solution after infiltration of local anaesthetic. The animal was draped leaving the operative site exposed. The drapes were kept in position by means of towel clips.

Preparation of recipient wound :

For every type of grafting, rectangular, square, or

circular wounds were first prepared at the selected recipient site, taking all aseptic precautions. The bleeding points were completely checked with the help of haemostats and the wound was then kept covered till grafting with gauze soaked in physiological saline solution, so as to avoid dessication.

Skin grafting technique :

The following four techniques of skin grafting were employed for the present experimental study :

(1) Pinch graft : - The grafts were harvested from the lateral wall of thorax, just 3 or 4" behind the point of elbow. The most satisfactory pinch grafts were obtained by inserting a sharp straight suturing needle grasped in a haemostat into the skin and gently elevating a cone of skin by retracting the needle slightly. This elevated a cone of skin which was then cut across, parallel with the skin surface, with a sharp scalpel (Plate No. 1). This freed a small disc shaped piece of skin, about 4 mm. in diameter, which was thickest in its centre and gradually thinest at the periphery. The number of these sections were simply placed on the recipient bed, which was prepared earlier as an open wound (Plate No.2). Terramycin liquid (Pfizer) was used in all the cases as topical application to combat infection. The graft was then covered with jelonet (Plate No.3) and thick fold of gauze soaked in physiological saline solution. In some cases, velroc plaster of paris was applied after padding with sterile cotton to immobilise the grafted area and in some cases simply Johnson and Johnson adhesive tape was used as immobilising agent and then

bandaged. The first dressing was changed on 14th day post-operatively.

(2) Split thickness graft : - A long, sharp, specially made skin grafting razor with rounded point was used for cutting the grafts. This graft included epithelial layer as well as some portion of dermal layer of skin. For proper cutting of graft the skin of donor area was held tensed and taut, usually by means of two thin sterile wooden board in the hands of assistant and operator (Plate No. 7). The blade of the knife was kept moist by dripping physiological saline solution on the area as the graft was cut. The graft was placed at once on the recipient area which was prepared earlier and kept covered with a sterile gauze soaked in sterile physiological saline solution. The wrinkles and curled margins were spread out gently with the help of instruments. Interrupted stures using braided silk size 4/0 were applied at 4 or 5 points to hold the graft in position. Terramycin (Pfizer) liquid was used as topical application. The graft was then covered with Jelonet over which a pad of saline soaked gauze was placed and immobilised with Johnson and Johnson adhesive tape and finally bandaged. In some grafts plaster cast was also used as immobilising agent. The wound was opened after 14 days for first dressing. The donor area was dressed antiseptically and bandaged.

(3) Full thickness graft : - In full thickness graft the piece of skin used as graft was in its entire thickness. Recipient bed was prepared first by making rectangular wound in the recipient site and all bleeding points were checked by means of haemostats and kept covered with sterile saline shoaked gauge. After

that an accurate pattern of the wound was made with a sterile used piece of X-ray film placed on the defect and outlined the margin very accurately by cutting with scissors. This pattern was then placed on the donor area and outlined with a dye (5% brillient green in alcohol). After marking the outline of graft the X-ray film piece was removed and by sharp scalpel the graft was cut, making skin incision 1 mm. beyond the margin of pattern. Slightly oversized graft was cut to allow shrinkage so as to reduce the tension at the suture line when applied on defect. One end of the graft was then raised from the underlying tissue of donor area, rolled it on the cylindrical object made of sterile gauze bandage to provide tension during the course of cutting (Plate No.$_{11}$), and to facilitate easy dissection of subcutaneous fat from the graft. Immediately the graft was placed upon the wound bed and held in position with four interrupted sutures at the four corners of the wound (Plate No.$_{12}$). Additional interrupted sutures with fine braided silk size 4/0 were placed to approximate the graft accurately with the wound margins (Plate No.$_{13}$). The tension on the sutured graft was maintained the same as that of the normal skin. Three or four stab wounds were made on the surface of the graft to permit drainage of the serum if accumulated beneath it (Plate No.$_{13}$). Terramycin liquid (Pfizer) was used in all the cases as topical application to combat infection if any. The graft was then covered with Jelonet over which was placed a pad of gauze soaked in saline solution and bandaged with sterile bandage and then finally immobilised the grafted area with plaster of paris cast or with adhesive tape.

The donor area was sutured with No. 3 braided silk and

bandaged.

(4) Pedicle graft :- In this technique the blood supply of the grafted skin was maintained by means of tube or pedicle attached with its one end to the donor area. Immediate method of grafting was taken up for this study. The graft bed was first prepared carefully by making circular or rectangular wound on the selected site of transplantation. Grafts were obtained from neighbouring skin of the wound and transplanted it on the defect by twisting the pedicle. Tubed pedicle flap was prepared in the donor area by making two parallel longitudinal incisions about 2" apart leaving the skin attached at both ends. By grasping the loose skin of the donor area and pulling it upward it was determined as to how wide the proposed tube could be cut and yet allowed for skin closure. The parallel incisions were extended to get the required length of the tube so that the tube may reach to the recipient site without tension. With the help of rat tooth forceps and scalpel the skin was elevated from its underlying tissue in the form of stripe. For preparing the tube, one interrupted suture was placed at each end of the elevated stripe of skin leaving the ends of thread longer so that it could be held by an assistant. These were used as traction sutures to rotate the edges of the skin stripe to facilitate exposure and suturing. Simple interrupted sutures with braided silk size 4/0 were used to prepare the tube keeping its raw surface inside (Plate No.16). The tube thus formed was severed from its one end leaving the other end attached to the donor area (Plate No.6). The free end of the pedicle was brought to the defect by tiwisting it and transplanted on the wound (Plate No.7). The edges of

the graft were carefully approximated with the margin of wound and interrupted sutures with braided silk size 4/0 were applied. Terramycin liquid topical was applied on the line of suture. The donor area was sutured with braided silk no. 3 in Halstead fashion.

The graft was then covered with non adherent Jelonet paraffin gauze and bandaged. First dressing was changed after 14 days, then the sutures were removed and pedicle was severed from its attachment to the graft and the donor area and again bandaged after applying terramycin liquid topically.

Post-operative care and management :

Recovery from the effect of chloral hydrate was uneventful. The animals were able to stand and walk on their feet within two hours after operation.

Temperature, pulse and respiration were recorded morning and evening till the seventh day of operation (Table No. 7).

Post-operative management and feeding :

The animals were kept confined in the stall for 14 days post-operatively. They were maintained on hay, paddy straw and green grasses. Water was allowed ad-libitum.

Change of dressing :

The wound of donor area was dressed daily with Spt. mercurochrome 1% till the removal of sutures on 8th day. The first change of dressing of graft was done on 14th day post-operatively.

Medicinal treatment :

All the experimental animals received the following treatment :

(1) Pronapen (Pfizer) 20 lacs x 5 vials.
1 vials I/m daily for five days.

(2) Vitablend (Glaxo).
1 ml. daily with water per os for seven days.

Removal of sutures :

Stitches of the donor area were removed on the 8th day of operation. The sutures of the grafted area were removed on the 14th day of operation when the wound was opened for the 1st change of dressing. After removal of the stitches the wound was lightly swabbed with 70% alcohol, dried, and dressed with terramycin liquid (Topical). Taking all antiseptic precautions the wound was bandaged again.

SURGICAL PATHOLOGY

All the experimental animals were sacrificed at the end of observation period by intravenous administration of super suturated Magsulph solution. The grafted areas were collected alongwith the portion of the surrounding skin and preserved in 10% formaline solution for histopathological examination.

MICROSCOPICAL EXAMINATION

Paraffin blocks of the tissues were made by standard technique. Longitudinal sections through the junction of grafted skin and host skin were made and the slides were stained with standard technique of Haemotoxylin and Eosin stain and mounted. The slides were then examined for histopathological changes microscopically.

*****
***
*

OBSERVATIONS & RESULTS

OBSERVATIONS AND RESULTS

Four different techniques of skin grafting were studied on 16 male buffaloe calves. The observations were made with particular reference to the clinical functions of the grafts, macroscopic changes at the grafted site and microscopic changes at the junction of graft and host tissue.

The clinical functions of the skin grafts included viability of each graft to cover the wound for its quick healing, pliability and resistance to trauma. The macroscopic observations were confined to hair growth, cosmetic appearance, contraction of the grafted wound and microscopic observation included histopathological changes found at the junction of grafted skin and the host skin.

G R O U P - I

In this group of animals the pinch graft technique of skin transplantation was studied. In all eight pinch graft operations were performed on four animals. The gross observations were recorded on 14th, 21st and 28th post-operative days.

Buffalo calf No. 1.

The animal recovered uneventfully from the effect of narcosis. The temperature, pulse and respiration remained almost normal during the observative period.

Experiment No. 1

In this experiment a surgically prepared wound measuring 2x3 inches, on lateral aspect of right forearm was seeded with 10 pinch grafts. No untoward symptoms except slight swelling all around the proximal and distal margin of the bandage was observed on the next day of operation which gradually subsided and became normal on 6th day post-operatively.

On fourteenth day when the wound was opened for first dressing, it was observed that out of ten pinch grafts seeded only three did not "take" and casted off in the form of dried scab. The remaining seven grafts were found in position quite alive and had spread all around to meet each other. The viable grafts were looking like islands of skin on raw area. On twenty-first post-operative day it was observed that all the pinch skin grafts extended and almost covered the entire area of the wound. A slight contraction was also marked in the wound. The grafted skin was firmly attached with negligible pliability. The hair growth was very sparce on the islands of grafted skin and the area appeared to be very delicate. On twentyeighth post-operative day, comparatively more hair growth was found on the grafted skin which had grown slightly thicker with the elapse of time. The epithelial covering of the wound was complete in all respect and the wound healed uneventfully.

Experiment No. 2.

In this experiment the pinch graft operation was per-

-formed on the posteromedial surface of the left forearm.

No untoward symptoms were observed in this case when the wound was opened for first dressing on the fourteenth post-operative day. It was found that out of ten pinch grafts nine had taken well and the remaining one could not succeed to "take" and casted off in the form of dry scab. The wound appeared normal and the healthy grafts looked like islands. They were in process of spreading towards each other. The area between two pinch grafts were pink in colour and healthy looking. On twenty first day the wound was found almost covered with new delicate epithelium with slight contraction of its area. A few hairs were seen on the islands. By twentyeighth day the denuded area was found completely covered with new epethelium which was still weak to bear any stretching or friction and the wound healed uneventfully.

Buffalo calf No. 2:

The recovery from the effect of chloral hydrate was uneventful. The temperature, pulse and respiration were recorded to be almost normal.

Experiment No. 3 :

In this experiment pinch graft operation was performed on the lateral aspect of left forearm and after preliminary dressings light plaster cast was applied. In all, eight pinch grafts were seeded on a area of 1½x2½ inches.

On fourteenth day, when the plaster was removed and the wound opened for first dressing it was found that all grafts were viable and sticking firmly on the underlying host bed. They were spreading from all sides to meet their fellows. The uncovered area of the wound, in between grafts were pink in colour and looking healthy. On twenty first post-operative day, the whole wound was found almost covered with the creeping epithelium from the grafted island of the pinch graft. A few hairs were observed here and there on grafted skin. The epithelial covering was complete by twentyeighth post operative day. There was marked contraction of the grafted area and the healed wound gave "cobble stone" appearance.

Experiment No. 4 :

In this experiment eight pinch grafts were seeded on the medial aspect of the right forearm. The prepared denuded area was 1½x2½ inches in size. Light plaster cast was applied after preliminary dressings.

No untowards symptoms were observed on the area beyond the wrapped plaster cast.

After fourteenth post-operative day the plaster of paris cast was cut and removed. On gross examination all the eight pinch grafts seeded on the recipient bed were found firmly attached with the underlying tissue. The wound was found clean and noninfected. On twentyfirst day each pinch grafts which was looking like islands of skin spread out and almost covered

the entire denuded area. A few hairs, here and there were also observed growing in that area. The epithelial covering was found complete by twentyeighth day and entire wound healed uneventfully. The grafted area was not strong enough to bear stretching, and looking unsmart cosmetically.

Buffalo calf No. 3 :

The animal recovered within two hours from the effect of chloral hydrate post-operatively. Temperature, pulse and respiration remained almost normal.

Experiment No. 5 :

In all seven pinch grafts were seeded on a surgically prepared wound measuring 1½x2 inches on dorsal metacarpal region of left forelimb. After preliminary dressings light plaster of paris bandage was applied. Clinically, the lower part beyond the plaster cast was found slightly swollen on the next day of operation which subsided gradually on fourth day post-operatively.

On fourteenth day, after removal of plaster cast and bandage the wound was found clean and healthy with all the pinch grafts in position, firmly adhered to the underlying bed. They were spreading towards each other and by twentyfirst day, they nearly covered the entire denuded area. The grafts were firmly attached and showing sparce hair growth. On twentyeighth day, the epithelial covering was complete but still not strong enough to bear friction.

Experiment No. 6 :

In this case 7 pinch grafts were seeded on surgically prepared wound measuring about 1½x2 inches on the postero-medial aspect of the right forearm. After completing the preliminary dressings it was immobilised with light plaster cast.

Clinically no untoward symptoms were observed in this limb. On fourteenth post-operative day the bandages were removed for the first change of dressings and it was observed that out of seven pinch grafts transplanted only six were viable and spreading to cover the denuded area, whereas the last one failed to survive. Other findings were similar to experiment No. 5.

Buffalo calf No. 4 :

The animal recovered well from the effect of narcosis. There was slight rise of temperature on the second day of operation which became normal on the fourth day. With the end of febrile stage the pulse and respiration also became normal.

Experiment No. 7 :

The pinch grafts were seeded on the lateral aspect of the right forearm. In total nine pinch grafts were transplanted on the surgically produced wound. In this case adhessive tape was used to immobilise the graft.

The wound was opened on fourteenth day post-operatively for the change of dressings. Out of nine, seven pinch grafts

were found viable and spreading to cover the wound. On inspection the wound was found clean and free from infection. On twentyfirst day a few hairs were found growing on the grafts. There was marked contraction of the wound. Almost all the viable grafts spread out considerably and with the elapse of time they were becoming thicker. On twentyeighth day the epithelial covering was found complete and grafted area healed successfully. So far the pliability and resistant to trauma was concerned it was found similar to other experiments discussed above.

Experiment No. 8 :

Eight pinch grafts were transplanted on a surgically prepared wound on the medial aspect of the left forearm. Adhessive tape was utilised to immobilise the grafted site. When the wound was opened for renewal of dressings on fourteenth post-operative day it was found that all the eight pinch grafts were viable. Other observations were similar to experiment No. 7

All the above four animals were sacrificed on thirtieth post-operative day to collect the tissue for histopathological study.

R E S U L T S

G R O U P -I

All the four animals of this group on which total eight pinch graft operations were performed showed no post-

operative complications except in buffalo calf Nos. 1 and 4 in which slight swelling beyond the bandaged area and rise of temperature were noticed respectively. These symptoms were not of significant value as they gradually subsided. The success obtained in this type of grafting was almost cent percent and all the wounds healed uneventfully. The islands of the grafted skin multiplied progressively over the underlying tissue until they coalesce themselves. Eventually the entire denuded area of the wound was covered by a thin and tender layer of epithelium. But with the elapse of time it grew thicker. The grafted area was firmly adherent to underlying tissue with less pliability. The hair growth was sparce and mostly found on the islands of skin. The newly formed epithelium was not so strong enough to bear friction or stretching.

Microscopic study of the pinch grafts revealed that the epidermal cell differentiation was more pronounced. The epidermal pegs were of little extent. Fibrosis was clearly marked with leucocytic infiltration but of little extent. Normal hair follicles sweat glands and sebacious glands were also noticed throughout the whole extent even under the line of union.

...

G R O U P - II.

In this group the split thickness skin grafting operations were performed on four animals. In all eight experiments were conducted for this study. Braided silk, size 4/0 was used to suture the grafts in position. The gross observations were recorded on 14th, 21st and 28th post-operative days.

Buffalo calf No. 5 :

The animal recovered uneventfully from the action of chloral hydrate within 2 hours post operatively. The temperature, pulse and respiration recorded were found almost normal.

Experiment No. 9 :

A split thickness skin graft was transplanted on a surgically created wound measuring about 1½x2 inches in size on the lateral aspect of the right forearm. Adhesive tape was used to immobilise the graft.

When the wound was opened after fourteen days following surgery for the first change of dressing, the graft was found firmly attached with the underlying tissues. The external surface of the grafted skin was found clean and non-infected and appeared light pink in colour. On twentyfirst day, the wound area was found some what contracted and the surface of the graft showed the sign of fine hair growth here and there. The area was looking white and firm. On twentyeighth day, wrinkles were observed on

the surface of the graft. The graft took well but the surface remained scaly with few hairs here and there. The grafted skin was not much resistant to friction and stretching but pliability was found to some extent.

Experiment No. 10 :

In this experiment a surgically prepared wound measuring 1½x2 inches on lateral aspect of left forearm was grafted after taking split thickness skin graft from the medial aspect of the right thigh.

On fourteenth day, after removal of the bandage for dressing, the graft was found in position and firmly adhered with the underlying tissue. The wound appeared clean as well as non infected. The graft was pinkish white in colour and covering the entire wound. The wound area was reduced in size due to marked contraction. On twentyfirst day, the graft was found dry and its upper surface appeared slightly wrinkled. It was looking tender and shiny. On twentyeighth post-operative day, it was observed that the graft had taken perfectly well and the tissue appeared some what thicker. Sparce fine hairs were observed here and there, but the area remained scaly and nonpigmented. Cosmetically the surface of the skin was looking unsmart due to wrinkling and scalyness. Pliability and resistant to trauma were noticed to a little extent.

Buffalo calf No. 6 :

The animal recovered from the effect of narcosis without

any untoward complication. The temperature, pulse, and respiration remained normal.

Experiment No. 11 :

In this experiment split graft was applied on a wound measuring 1½x2 inches on the lateral aspect of the left forearm and it was held in position by six stitches using braided silk size 4/0. The adhesive tape was used to immobilise the graft. On fourteenth day, after removal of the bandage, the wound was found in fair condition. The graft was viable and closely adhered with the bed. A very thin superficial layer in form of dry scab came out with bandage leaving behind shining pinkish white epithelium on the wound. The grafted area appeared slightly contracted. On 21st day the grafted skin was found dry and wrinkled on the upper surface, which showed clear indication of contraction. The area was slightly pliable by twentyeighth day. It was further observed that with times it had become more thicker and pliable still not much resistant to trauma. Sparce hair growth were also observed here and there.

Experiment No. 12 :

In this experiment the split graft was applied on the wound of lateral aspect of right thigh. After preliminary dressings the graft was immobilised with Johnson & Johnson adhesive tape and then bandaged. Some difficulty was felt in the beginning to maintain the bandage in position due to slanting anatomical construction of thigh which was unfavourable for holding the

bandage in position. Nothing untowards were observed beyond the area under bandage. Before the schedule date for changing the dressing from the wound i.e. on fourteenth day, the bandage slipped twice from its position and it was readjusted. When the wound was opened on fourteenth day post-operatively, the graft was found dried and had no attachment with the underlying tissue. When the stitches were removed, it came off from the raw surface of the wound. The wound appeared clean and non-infected. In this case the graft failed to "take", perhaps due to imperfect immobilisation.

Buffalo calf No. 7 :

The animal recovered uneventfully. Pulse, temperature and respirations were recorded almost normal. Braided silk size 4/0 was used as suture material.

Experiment No. 13 :

In this experiment, the animal received split thickness skin graft on its medial aspect of left forearm. The wound was prepared earlier measuring 1½x2 inches in size. After grafting and preliminary dressings the grafted area was immobilised with light plaster of paris cast.

On fourteenth post-operative day when the plaster cast and bandages were removed, the graft was found quite alive and firmly attached to the underlying tissue. The graft showed shining and slightly moist appearance on the upper surface. The

forearm was selected as recipient site. Surgically prepared wound measuring 1x2 inches was grafted taking split graft from the medial aspect of the left forearm.

On fourteenth day when the wound was opened for removal of stitches the graft appeared dead and dry. After removal of the stitches it came off from the wound in the form of dry crust. The graft failed to "take" and the wound did not heal by first intention.

Experiment No. 16 :

A wound measuring 1½x2½ inches on the lateral aspect of the right thigh was utilised as recipient bed. The grafted area was immobilised with plaster cast after proper bandaging.

On fourteenth post-operative day when the wound was opened for change of dressing, it showed healthy signs of healing. The graft was found in position quite viable and its margins were found intimately attached with the underlying bed. It appeared glossy and pinkish white in colour with no pliability on manipulation. On twentyfirst post operative day the size of the wound was found reduced owing to contraction. Sparce fine hairs were also observed on the grafted area. The pliability of the grafted skin was found to be increased slightly by twentheighth day. But the grafted area was looking scaly, white with some fine hairs here and there. The thickness of the graft was found increasing with the elapse of time. The graft took well and the wound healed without any complication.

All the above four animals were sacrificed on thirtieth post-operative day for collection of tissue for histopathological study.

R E S U L T

G R O U P -II.

Split thickness grafts were studied under this group with seventyfive percent success. In all eight split graft operations were performed on four animals, out of which six remained viable and offered complete epithelization of the wounds under study. On the other hand, two grafts of experiment Nos. 12 and 15 failed to "take" and sloughed out with the bandage on fourteenth post-operative day when the bandage was opened for the change of dressing.

All the viable grafts behaved almost in similar manner. Hair growth was very sparce and fine. The graft area was found scaly with wrinkles on its upper surface. Cosmetically it looked unsmart and varied in colour from the surrounding skin. It was pliable to some extent and thickened with the elapse of time. The resistance against trauma was also found to be increased with the time.

Microscopic study revealed epidermal cell differentiation more pronounced. The meshes of startum papillaire were heavily laden with fibroblasts and leucocytes. The fibrosis was seen to be continued from the hypodermis to the epidermis at the line of junction and under the epidermis of the grafted part.

Sebaceous and sweat glands were however not noticed.

...

GROUP - III

In this group, the full thickness skin grafting operations were performed on four animals. In all, eight experiments were conducted on surgically prepared wounds. Braided silk, size 4/0 was used to suture the grafts in position. The gross observations were recorded on 14th, 21st and 28th days post-operatively.

Buffalo calf No. 9 :

The animal recovered uneventfully from the action of basal narcosis. Temperature, pulse and respiration were recorded normal till seventh day post-operatively.

Experiment No. 17 :

A graft bed was surgically created measuring 2x3 inches on the lateral aspect of the right forearm and grafted with full thickness skin taken from the medial aspect of the left forearm.

No post operative complication was observed in this case. On fourteenth post-operative day, when the plaster cast and bandages were removed for renewal of dressing and removal of stitches, a patch of thin superficial layer of skin came away

adhered with the Jelonet gauze. Even then, some blebs were found on the surface of the graft filled with serous fluid. The external surface appeared pinkish white and blistered. Small black hair roots were observed uniformly scattered like pin points on the whole surface of the graft. The line of junction between grafted and normal skin showed perfect union. On twentyfirst day, the external surface was found dry and covered uniformly with small hairs. There was still some difference in colour from the surrounding skin but gradually it was proceeding towards normalcy. Pliability and resistance against friction or streching were more marked.

Experiment No. 18 :

In this experiment the donor site of experiment No.17 was utilised as recipient bed. The full thickness graft was taken from the right lateral thoracic wall.

No untowards symptoms were noticed post-operatively except some swelling around the area distal to the plaster cast. The swelling subsided on fifth day.

On fourteenth post-operative day, when the wound was opened for renewal of dressings and removal of stitches, the grafted skin was found viable and firmly attached to the host tissue. Disquamation of surface epithelium was also noticed but not to that extent as in experiment No. 17. The graft appeared pinkish white in colour and fine hair roots were observed scatered uniformly on the grafted surface. On twentyfirst post-

operative day, the colour of the grafted skin was found changing towards normalcy. The hair growth was also observed in uniform manner on the skin surface. On twentyeighth day it fooked more or less like normal skin, with strong union on the line of junction. The graft was somewhat pliable and resistant to trauma.

Buffalo calf No. 10 :

Recovery from the action of chloral hydrate was uneventful. Temperature, pulse and respiration showed no significant change.

Experiment No. 19 :

An area measuring 2x2½ inches on lateral tibial region of right hind limb was grafted with full thickness skin taken from the lateral aspect of the right forearm.

On fourteenth post-operative day, it was observed that the area distal to the plaster cast had developed some swelling and abrasion on its medial aspect. The plaster was removed on seventh post-operative day as it was producing discomfort to the animal. Then the swelling subsided gradually and on fourteenth post-operative day, when the wound was opened, the grafted skin appeared devitalized and necrosed. The graft did not take and sloughed off completely immediately after removal of the stitches.

Experiment No. 20 :

The donor site of the experiment No. 19 was utilised as recipient bed and grafted with full thickness skin measuring 2½x3 inches, taken from the right side of the thorax. After preliminary dressings, it was immobilised with light plaster cast. No untowards symptoms developed in this limb beyond the area wrapped under plaster cast.

On fourteenth post-operative day, when the plaster cast and bandages were removed for renewal of dressings and removal of sutures, all the stitches were found intact and there was complete union between grafted and the host skin. The external surface of the graft showed disquamation of superficial epithelial layer. The entire surface appeared pinkish and shining except there existed a few necrotic focci which was cleaned and dressed antiseptically. On twentyfirst post-operative day hair growth was marked on the grafted surface. By twentyeighth post-operative day, the colour of the grafted area became almost the same as that of the normal skin. Pliability and cosmetic appearance of the grafted skin were comperatively better.

Buffalo calf No. 11 :

The animal was on its feet within two hours post-operatively. Temperature, pulse and respiration remained almost normal.

Experiment No. 21 :

In this particular experiment a surgically prepared

wound measuring about 1x1½ inches on lateral aspect of the left metacarpal region was grafted with a piece of skin taken from the medial aspect of the right metacarpal region. Then plaster cast was applied after preliminary dressing. No post-operative complication appeared over the area beyond the wrapped plaster cast.

On fourteenth post-operative day when the wound was opened for renewal of dressing and removal of stitches, the graft showed considerable disquamation of superficial layer of the skin which separated out as a moist scab with Jelonet gauze, leaving a pinkish surface behind. The wound was found clean and non infected. The surface of the graft gave a blistered appearance. The line of junction showed perfect union all around. On twentyfirst post-operative day, the grafted area indicated an uniform hair growth on its surface. By twentyeighth post-operative day, it assumed somewhat the same colour as that of the surrounding skin. Pliability and resistance against stretching were also observed similar to experiment No. 20. The graft survived well and the entire wound area healed uneventfully.

Experiment No. 22 :

In this experiment the donor wound measuring 1½x2 inches of experiment No. 21 was grafted with full thickness skin taken from the lateral aspect of left metatarsal region of the same animal. Plaster cast was used to immobilise the grafted area after completing the preliminary dressing. No post-operative complication was noticed beyond the area wrapped in plaster cast.

On fourteenth post-operative day when the plaster cast and bandage were removed for change of dressing and removal of stitches the graft showed healthy signs of healing. The appearance of the grafted skin was almost the same as seen in experiment No. 21, except that the blistering was confined more to the central part of the graft only. Observations made both on twentyfirst and twentyeighth post-operative days were almost similar to the preceeding experiment. The graft was successful and wound healed uneventfully.

Buffalo calf No. 12 :

The animal recovered well from the effect of chloral hydrate narcosis. Temperature, pulse and respiration did not show any deviation from the normal.

Experiment No. 23 :

In this particular experiment a surgical wound measuring 2x2½ inches was created on the dorsal surface of the left forearm and grafted with whole skin taken from the leteral aspect of right forearm. In this case the adhesive tape was used to immobilise the grafted area.

Gross examination on the fourteenth post-operative day revealed, the signs of necrosis in the grafted skin. The central part of which appeared ischaemic with cynotic margins. Immediately on removal of stitches, the graft completely separated from the host bed. Thus the graft failed to "take", and the wound healed up by second intention.

Experiment No. 24 :

In this experiment the donor area of experiment No. 23 was utilised as recipient bed. The full thickness skin graft was taken from the right thoracic wall to transplant on an area measuring 2½x3 inches in size.

On fourteenth post-operative day, when the wound was opened for renewal of dressing and removal of stitches the graft appeared almost nonviable and met with the same fate as in the preceeding experiment No. 23.

Out of four animals, three were sacrificed on thirtieth post-operative day to collect the tissue for histopathological study, whereas the fourth one in which the graft did not take was not sacrificed for histopathological examination.

R E S U L T

G R O U P - III

Full thickness skin grafting were performed on eight surgically prepared wounds, out of which three grafts (i.e. experiment Nos. 19, 23 and 24) failed to "take" and slaughed off on fourteenth post-operative day when the stitches were removed. The remaining five grafts which succeeded to "take", showed perfect union at the line of junction and appeared smart cosmetically. The growth of hairs were better than pinch and split grafts. Blistering with desquamations of superficial surface of the grafted skin was noticed in almost all the experi-

-ments. In course of time the desquamated epithelium was restored to the normal. The grafted area was found resistant to friction and stretching. The pliability and texture of the skin were almost similar to normal skin. The wound healed up uneventfully.

Microscopically, the epidermis showed distinct differentiation between two characteristic layers i.e. stratum germinativum and stratum corneum at the line of junction. However, this zone was devoid of epidermal pegs and it showed straight disposition of the epidermis at this point. The fibrosis was marked in the stratum papillaire as well as in reticularis, but the number of fibroblast cells were appreciably more in the former than in the later. These changes on the dermis showed a clear cut tendency of the papillary layer to be more cellular and the reticular layer to be more fibrous which was characteristically in consonance with the normal skin. Wide meshed capillaries and small blood vessels were noticed in the area of fibrosis.

...

G R O U P - IV

In this group, the pedicle graft technique of skin transplantation was studied on four animals. In all, eight experiments were performed on the limbs of the experimental animals. Braided silk, size 4/0 was used to suture the grafts and to prepare the tube. The gross observations were recorded on 14th, 21st and 28th days post-operatively.

Buffalo calf No. 13 :

The animal recovered uneventfully from the action of chloral hydrate within two hours after operation. Temperature, pulse and respirations were recorded almost normal.

Experiment No. 25 :

A surgically prepared wound measuring 1¼x2 inches, and located on right forearm was grafted with tubed pedicle graft. After completing the preliminary dressings, the grafted site was immobilised with adhesive tape.

On fourteenth post-operative day when the wound was opened for removal of sutures, the superficial layer of grafted skin appeared as hard crust which came away with the Jelonet gauze leaving a shining surface beneath. The line of junction showed perfect union with the host skin. The sutures were removed and pedicle was severed from its attachment to the graft. By twentyfirst day, the graft was found covered uniformly with small

hairs and it was found strong enough to bear friction or stretching. On twentyeighth day, there was no marked difference between the grafted area and normal surrounding skin. The wound healed uneventfully without contraction.

Experiment No. 26 :

In this experiment, a surgically created wound measuring 1½x2 inches on lateral aspect of left forearm was covered with tubed pedicle graft prepared on the posteromedial surface of the same region.

No untoward post-operative complications were observed. On fourteenth post-operative day, when the wound was opened for renewal of dressings and removal of sutures, the grafted area appeared slightly puffy. A thin sheet of dry scale came off with the Jelonet as in experiment No.25. By twentyfirst day, the grafted area was found uniformly covered with small hairs. The line of junction showed strong union. By twentyeighth day following surgery, the colour of grafted skin closely matched the surrounding skin. The grafted skin was found strong and pliable.

Buffalo calf No. 14 :

The animal recovered well from the effect of chloral hydrate. The temperature, pulse and respiration remained almost normal. The animal showed slight limping from its right hind limb, which continued for 3 days post-operatively.

Experiment No. 27 :

In this experiment a surgically prepared wound measuring 1½x2 inches on the lateral aspect of right tibial region was grafted after sliding the tubed pedicle graft from the medial aspect of the same region. The grafted site was immobilised with adhesive tape after preliminary dressings.

By fourteenth post-operative day, after removal of bandage it was observed that the grafted skin had taken well. The line of junction with the host skin showed perfect union. Other observations were almost similar to the experiment No. 26. The wound healed up by first intention.

Experiment No. 28 :

An experimental wound measuring 1½x2 inches on the lateral aspect of right forearm was covered with tubed pedicle graft. After completing the preliminary dressings, the grafted area was immobilised with adhesive tape. No untoward symtoms were observed in this limb.

When the bandages were removed on fourteenth post-operative day to severe the pedicle and to change the dressings, the external surface of the graft showed considerable degree of desquamation of the surface epithelium. But the graft was found quite viable and healthy. The union between the transplanted graft and host skin was also found quite strong and perfect. By twentyfirst day the entire grafted area was found covered with small hairs. The texture of the grafted skin closely matched

with the surrounding skin by twentyeighth post-operative day. The grafted area was found pliable and resistant to trauma.

Buffalo calf No. 15 :

No untoward post-operative complications were found in this particular animal. The temperature, pulse and respiration were recorded almost normal.

Experiment No. 29 :

In this experiment a surgically prepared circular wound on dorsal aspect of left forearm was grafted. No complications were observed in this case post-operatively. When the wound was opened for renewal of dressings and removal of sutures on fourteenth post-operative day, it was observed that the desquamation of surface epithelium was very negligible in this case. The upper surface of graft gave shiny appearance. In this case, the healing was found perfect and strong. By twenty-first day, the surface of the graft showed uniform and regular hair growth. By twentyeighth day, it closely matched with the surrounding skin in texture and appearance. The wound healed uneventfully and without contraction.

Experiment No. 30 :

In this case a surgically prepared circular wound, about two inches in diameter on the lateral aspect of the right forearm was grafted with tubed pedicle graft slided from the medial aspect of the same region.

No post-operative complications were noticed in this experiment. Other findings were almost similar to the experiment No. 29. The graft took successfully and the wound healed uneventfully.

Buffalo calf No. 16 :

The animal showed no post-operative complications and recovered well from the effect of chloral hydrate. The temperature, pulse and respirations were recorded almost normal.

Experiment No. 31 :

In this experiment the pedicle graft was applied on the dorsal aspect of thigh in left hind limb. A surgically prepared wound measuring 1¼x1½ inches was covered with the tubed flap slided from the medial aspect of the same region.

On fourteenth post-operative day when the bandages were removed to disconnect the pedicle and simultaneously to remove the sutures, then the graft was found viable and healthy with minimal desquamation of surface epithelia. The surface of the graft along with pedicle appeared shiny with no change of colour. By twentyfirst post-operative day, the entire surface of the grafted skin was found covered with uniform small hairs. By twentyeighth day, it closely resembled the surrounding skin. The pliability and resistant to trauma were found comparatively better than the other types of grafting.

Experiment No. 32 :

In this case the tubed flap was formed on the dorsal aspect of the left forearm and slided to cover an wound measuring 1½x1½ inches on the lateral aspect of the same limb.

No post-operative complications were noticed in this experiment as well. In this case the desquamation of surface epithelium was noticed to a lesser extent by fourteenth post-operative day. The line of junction between the host skin and grafted flap showed perfect union. The other findings were similar to those found in experiment no. 31. The graft took successfully and wound healed without any complication.

R E S U L T

G R O U P - IV.

The percentage of "take" obtained in this type of grafting was 100%. All the wounds on which the grafts were applied healed without showing any complications. The desquamation of surface epithelium was observed in almost all cases to a lesser degree except in case No. 25, where desquamation was found comparatively more. In buffalo calf No. 14, symptoms of limping was observed due to discomfort caused by the pedicle graft. Uniform hair growth with better pliability of graft was observed in almost all cases. The resistant against trauma was also comparatively better in this type but it was experienced that the surgery required careful and skilfull design and it was

tidious as well as a lengthy procedure.

Microscopically the desquamation of stratum corneum was found specially at the line of junction. There was also absence of interpapillary pegs. The epidermis as a whole was found almost stretched and thin at the line of junction. The underlying dermis showed massive encrochment by the fibroblast cells ascending from the underlying hypodermis at the line of union. Fair amount of leucocytic infiltration was noticed. Hair follicles with characteristic cells of epithelial and connective tissue sheaths were present, however the collagen fibers were found to be more in connective tissue sheath. Hair shafts with normal cortical and medullary cells were noticed but those in the process of degeneration or completely decayed were also not uncommon.

*****
***
*

DISCUSSION

D I S C U S S I O N

The repair of injuries involving an extensive loss of skin has long been recognised to be a surgical problem in bovine species. Medawar (1944) described that the "natural" process of wound healing is always necessary but not always sufficient to secure an efficient functional repair of damaged tissue. To achieve functional repair in extensive skin loss, the operation of skin grafting is a fully adequate solution.

The patient himself offers a handy and effective material in his skin and fascia, to relieve his own misery (Brenizer, 1940).

The auto-transplantation of skin in animals is now well established, but the clinical application is still not very much in vogue in bovine species due to certain limitations. From the review of literatures it appeared that this skin grafting method of treatment for extensive skin damage has not been tried adequately so far in bovine. The successes attained with skin grafting in man, horse, dog and in other experimental animals stimulated an effort to apply these techniques in bovine.

A surgeon is increasingly anxious to know about the changes taking place in different types of skin grafting in bovine. He sometime wants to take it as one of the surest means of treatment for incurable extensive skin lesions, where the possibility of epithelization of the denuded area by ingrowth occuring from the border of the wound is remote. The grafting

methods are intimately concerned with the changes brought about in gross and histopathological examinations at the grafted sites.

The surgical technique has under gone revolutionary changes and many surgeons (Reverdin, 1869; Ollier, 1872; Thiersch, 1874; Wolfe, 1875; Filatoff, 1916; Gillies, 1917; Blair, 1924; Davis, 1925; Douglas, 1930; Dragstedt, 1937; Davis and Kitlowski, 1938; Medawar, 1944; Keef, 1946; Billingham and Medawar, 1951; Woolsey and Schaffer, 1952; Ammann, 1952; Schebitz, 1955; Uberreiter, 1956; Neal, 1958, 1961; Jensen, 1959; Spreull, 1962; Bromberg, 1964; Boyd, 1967), both in human and veterinary surgery have described different techniques and methods of skin grafting to overcome various difficulties and to achieve success by this valuable and unparallel method of extensive wound treatment.

Prior to undertake the skin grafting operation one must keep in mind some common causes of its failure as suggested by King (1945). They are as follows :-

(a) Infection.

(b) Blood and serum pocket beneath the graft.

(c) Inadequate contact between the grafts and its bed.

(d) Improper or inadequate anchorage of the grafts so as to allow movement during the healing period.

In this present series, thirytwo operations of skin grafting on buffalo calves (eight pinch graft, eight split graft, eight full thickness graft and eight pedicle graft) were performed

on surgically created wounds. Grossly the grafts were observed for viability, pliability, hair growth, resistant to trauma and cosmetic appearance on 14th, 21st and 28th post-operative days. In addition, the histopathological changes of the grafted skin were also studied under light microscope.

Pinch graft :

In this study, pinch graft operations were performed on four animals at two different sites, thus the total experiments were added to eight. The success obtained for complete epithelization of wound by this method of grafting was very encouraging. Almost all the wounds healed uneventfully and were found covered completely with new growth of epithelium from the seeded pinch grafts. Though in experiment Nos. 1, 2, 5, 6 and 7, some seeded grafts lost their viability and casted off, yet the remaining viable grafts proved capable of covering the entire wound. This finding upheld the idea of Neal (1961), who described that the pinch grafts which had "taken", formed islands of skin in the raw areas, from which epithelium grew outwardly coalescing with that of neighbouring grafts which eventually covered the entire raw area.

It appeared from the present experiment that this method of grafting was simple and usually resulted in high percentage of "takes", as well as gave good functional repair which was in agreement with Davis (1940). He named this technique as small deep graft and said that it gave very encouraging result as in this type the healing was observed strong, stable and permanent.

In his own works, he used this technique with full satisfaction and found it indispensable while dealing with large losses of cutaneous tissues and in solving some of the complicated problems.

Ballingham and Medawar (1951) after performing pinch graft on laboratory animals opined that, though the pinch grafts took longer time to heal soundly but gave cosmetically and functionally better results. So far the cosmetic appearance was concerned, the authors findings in bovine remained contradictory to aforesaid experience.

Deokiouliyar (1967) performed pinch grafting in dog and observed that this method of skin grafting was easy to perform but it did not provide a smart appearance at donor as well as recipient sites, but this graft appeared resistant to infection and gave good results even on infected wounds.

So far the cosmetic appearance is concerned, it is of little significance in the case of bovine, where function is a dominating factor. Although the cosmetic appearance was not very smart in this study yet it provided perfect healing to the wounds, and at the same time the donor wounds were managed comfortably. With the elapse of time, the thickness of the graft and its pliability were found increasing. So, in authors opinion, this technique of pinch grafting could be performed very safely and easily for covering the bovine wounds.

The pinch grafts owing to their small size appeared to be the least susceptible to the damaging effects of movement and this fact together with the high percentage of "takes"

obtained made it a particularly attractive method for grafting in the bovine.

Split grafting :

By split graft technique, prepared wounds were grafted, using the procedure deviced by Blair and Brown (1929) and achieved success in 75% cases. Uberreiter (1956) also got successful result by using this technique in horse, dog, and cat.

In present study, the viable grafts showed sparce hair growth. The grafted area remained scaly, leathery and cosmetically it gave unsmart appearance. It was found pliable to some extent. The above findings are in agreement with the findings of Hogle et al (1959). They grafted split skin 0.1 to 0.03 inches thick and found that the thinner sections suffered less necrosis and yet transferred surprising numbers of hair follicles, where as Billingham and Medawar (1951) performed split thickness graft in laboratory animals and reported that split thickness grafts being devoid of hair follicles failed to regenerate normal crop of hairs.

Hogle et al (1959) observed in horse that the area grafted with split thickness skin remained scaly for months, owing to lack of functional sebaceous glands. Microscopically, the author also did not observe sebaceous glands in the grafted area. Boyd (1967) achieved only 66% success in horse by this method of grafting where as in present study, 75% success was achieved in bovine.

The experiences obtained in this study showed that the split thickness grafts were difficult to harvest by free hand in absence of a special instrument "Dermatome". It has also been observed by various workers that this type of grafts did not give the desired cosmetic appearance, which is in accordance with experiences of Ross (1968) and Deokiouliyar (1967).

Though the percentage of "take" was obtained comparatively better in this type of grafting, yet difficulty was felt in maintaining the graft in position where proper bandaging of the wound was not feasible. Due to this trouble, the grafts of experiment Nos. 12 and 15 did not "take" and came away as dried scab with the protective gauze. Smith and Marks (1968) experienced the same difficulty and found split grafting generally unsatisfactory in the horse.

Neal (1961) described that the most important factor governing the out come of skin grafting was whether or not the wound was in such a position that firm and prolonged pressure bandaging could be applied. This statement of Neal was found true by the author in all most all types of grafting. The anatomical conformation of bovine is such that at various sites prolonged pressure bandage can not be applied and this fact becomes an obstacle in the way of achieving success in skin grafting operations in bovine. But from the present study it is concluded that the split grafting due to its good percentage of "take", and not unduly susceptible to trauma, can be used on the wounds of limbs of bovine, in which the functional repair is of value in comparison to cosmetic appearance.

Full thickness graft :

Nitolitchi (1879), Lowson (1871), Lefort (1872), preceded Wolfe (1875) in the transplantation of whole skin as cited by Padgett (1948). Wolfe, whose name along with Krause (1876) has been associated with this particular type of skin grafting, used the method for ectropion of the eyelid in human patients. The Wolfe-Krause technique of whole skin graft was used in this study and success was achieved only in 62.5% of cases.

In this present study, eight surgically prepared wounds were grafted with full thickness skin grafts taken from different sites. The results obtained were not very much encouraging. Out of eight grafts applied, three failed to "take" without showing any apparent cause of failure. Blair (1924) obtained same type of result while summerising his routine methods of skin grafting in human cases. He described that though the result of full thickness graft was uncertain, but it gave better result than pedicle or the split thickness grafts.

Remaining five grafts, which succeeded to "take" showed perfect union at the line of junction and appeared smart cosmetically. As regards growth of hair, pliability and texture of the grafted skin it closely matched with the surrounding host skin in course of time. Contraction was not marked in any of the wounds healed by this method of grafting. Boyd (1967) and Ross (1968) obtained similar results in equine and canine respectively. Boyd (1967) found most desirable cosmetic effect with

full thickness skin transplants. Deokiouliyar (1967) found full thickness graft relatively successful with good cosmetic results in canine. Ross (1968) found, free full thickness graft most useful type for canine wound closure as they were easily placed on any wound and were tough, grew hairs well, and gave cosmetically satisfactory result. Where as, Jensen (1959) who performed 98 experimental grafts in canine with different techniques observed that no single type of skin graft was uniformly successful for all areas of the dog's body, nor for all kinds of skin lesions. He found free full thickness graft was relatively successful for lesions free from infection and excessive granulation tissue.

Blistering with desquamation of superficial surface was marked in almost all cases of this present experiment of full thickness grafts, which required very careful attention towards dressings to save it from being infected. In authors opinion, the necrosis of supperficial layer seemed to occur due to non-availability of nutrition to the upper layer of cells as the graft being whole skin was thicker and its maintenance by osmosis and diffusion from the fluids bathing the inner surface from the recipient bed was not possible. The authors observation in buffalo calves was in agreement with the observation made by Hogle et al (1959) in horses. They described that the graft was actually a parasitic structure until it established its own nutrition, until, that time, it must be maintained by osmosis and diffusion from the fluids of the recipient bed. For this reason, the thinner section of grafts suffered less necrosis than the thicker grafts.

Neal (1961) also hold the same opinion that the full thickness grafts were unlikely to survive except under idal condition owing to their inability to absorb adequate nutrition during the first few critical days. As regard blistering of upper surface, Padgett (1948) opined that some superficial loss from blisting in full thickness graft was often a feature. Depending upon the depth blistering may endanger the final appearance. Less often, the grafted skin might show some focal necrosis. In this particular study the grafted surface of experiment No. 20 also showed few necrotic focci.

The greatest inconveniences encountered in full thickness grafting were the time, consumed in performing the operation, the repair of donor area when large piece of skin was taken, as well as complete immobilisation of the limb. Some degree of movement of the grafted area and the overlying dressings inevitably occured, which endangered the survival of the grafts. Therefore, it is unlikely, in authors opinion that whole thickness graft which required optimal conditions for its survival would be easy and much applicable for clinical cases in bovine.

To achieve greater success in application of full thickness grafts, Surgeons (Douglas, 1930; Dragsted, 1937; Boyd and Hansleka, 1971; Goel and Nayak, 1971) both in human as well as Veterinary surgery have developed certain modifications in technique and instruments which still stand investigation in cases of bovine.

<u>Pedicle Graft</u> :

From review of literatures it appeared that several

workers viz., Filatoff (1916), Gillies (1917), Blair (1921), Davis and Kitlowski (1938), Keef (1946), Cowley and Francis (1958), Jensen (1959), Converse (1962), Unwin (1962), Deokiouliyar (1967), Ross (1968), Doganeli (1969), Pullen (1969), Sahu and Singh (1971), described the successful use of pedicle grafting in several species of animals including human beings. As quoted by Padget (1948) the origin of the tubed pedicle graft is usually ascribed to Gillies (1917). However, Filatoff used this method on a case in 1916. But Gillies and his Co-workers popularised this method of skin grafting.

In this study eight surgically prepared wound on the limbs of buffalo calves were grafted with this technique of tubed pedicle graft. The percentage of "take" obtained in this type of grafting was 100%. This achievement was fully in agreement with the opinion of Ross (1968), who described, the pedicle grafts maintain at least one attachment to the donor site during graft healing. This attachment supplies nutrition to the graft and increases the success rate.

Neal (1961) described that pedicle grafts involved the transference of an area of skin and subcutaneous tissue from the donor site to the wounded area, the blood supply to the graft being maintained by means of a tube or pedicle of skin which was severed when the graft was established. By this means the nutrition of the graft is ensured during the critical first few days.

The desquamation of the surface epithelium was observed to a negligible degree in almost all cases of this present study.

Uniform hair growth, with better pliability of grafted skin was observed. Resistant to trauma was comparatively better in this type than any other type of grafting which was in concord with the findings of Wallace et al (1962), in canine. They reported that pedicle and full thickness grafts were the two methods for sound repair of major defects. Spreull (1962) was fully in agreement with the opinion of Wallace.

Doganeli (1969) performed experimental skin grafting on 10 teats of three cows. Four of the five teats with tube grafts showed good results and were suitable for milking after 12 days.

Unwin (1962) reconstructed successfully left two teats in a cow by mobilising pedicles from the lateral aspect of the udder. More recently Sahu and Singh (1971) treated successfully a large denuded area in bullock by covering it with pedicle full thickness skin graft and obtained sound and uneventful healing.

The greatest inconveniences encountered in this present study of the said type were the longer time it took during operation, it required very careful and skilful design to cover the defects. In author's opinion it was tedious, cumbersome and a lengthy procedure. Moreover, the surgery required, caused considerable discomfort to the animal, which was manifested in experiment No. 14 by limping. Spreull (1962) also expeirenced these difficulties in dogs.

The other difficulties experienced in buffalo calves with this type of grafting were the limited sites of its applica-

-tion. It can be used to cover the wounds of those areas only where there is abundent skin, available to form tube and still sufficient skin left to close the donor site. These difficulties are also experienced by Neal (1961) in horses. He described that lack of loose skin about the horses limbs would make the provision of a pedicle of suitable size a serious if not insuperable difficulty. Spreull (1962) recommended tube grafts for repairing defects on the trunk, neck, and extremities of dogs. Deokiouliyar (1967) found tubed pedicle graft most suitable for the lesions of the extremities of dogs, but lack of losse skin to cover the area from where skin was used for preparation of tube limited this method to small areas. The author found these observations true in the case of bovine also. From this study it was concluded that this type of grafting could be used with success on limited sites and on small defects in bovine species too.

Histopathology of the healed skin grafts :

Padgett (1948) observed that the histologic picture of the full thickness graft did not differ materially from that of the thinner grafts. Chanana et al (1966) studied the skin grafts reaction in calves by light microscope and observed that in all grafts the superficial portion of the epidermis seperated as a "ghost" graft. In autografts there was minimal vacuolization of epithelium some Karyorrhaxis and slight to moderate proliferation of connective tissue around hair follicles. Whereas, in this present study the histologic picture revealed

epidermal cell differentiation in almost all types of grafting used for experimental study. Epidermal pegs showed straight disposition.

In pinch grafts, fibrosis was clearly marked but not to much extent. Hair follicles and sebaceous glands were noticed throughout the whole extent.

In split thickness grafts the meshes of stratum pepillaire were found heavily laden with fibroblasts and leucocytic infiltration. The fibrosis was seen to be continued from the hypodermis to the epidermis at the line of junction and under the epidermis of the grafted part. Sebaceous and sweat glands were however not noticed.

In full thickness grafts, the papillary layer of the dermis was found more cellular and reticular layer less cellular, which is characteristically seen in normal skin. However, fibrosis and leucocytic infiltration were marked more in stratum papillaire.

In pedicle grafts, the underlying dermis showed massive encrochment by the fibroblast cells ascending from underlying hypodermis at the line of junction. Fair amount of leucocytic infiltration were noticed and the hair follicles with characteristic cells of epithelial and connective tissue were present. However, the collagen fibers were found to be more in connective tissue sheath as found by Chanana et al (1966).

*****
***
*

SUMMARY & CONCLUSION

SIONS

ic damages to certain
larger wounds, due to
re is insufficient skin
by granulation is slow
hich hampers the func-
kin grafting procedures
objections.

present work to find out
grafting in bovine,
s.

in grafts namely, pinch
ness graft and pedicle
repared wounds in 16 male

in different techniques,
ations, upto a period of
or viability, resistant
ction and pliability of
ove gross observations,
grafted site were also

found easy to perform
s, even without much care.

SUMMARY AND CONCLUSIONS

In bovine, the risk of traumatic damages to certain parts of the body is high. In cases of larger wounds, due to accidental injury or tumour removal, there is insufficient skin available for primary closure. Healing by granulation is slow and results in cicatricial contraction which hampers the functional utility of the part concerned. Skin grafting procedures can easily be performed to prevent these objections.

The author has undertaken the present work to find out an easy, and satisfactory method of skin grafting in bovine, taking buffalo calves as the type species.

In this study four types of skin grafts namely, pinch graft, split thickness graft, full thickness graft and pedicle graft, were attempted on 32 surgically prepared wounds in 16 male buffalo calves.

The success of the skin grafts in different techniques, were assessed from the results of observations, upto a period of 28 days post operatively, particularly for viability, resistant to trauma, hair growth, degree of contraction and pliability of the grafted skin. In addition to the above gross observations, the histological changes occured at the grafted site were also studied.

On the whole pinch grafts were found easy to perform and offered the most satisfactory results, even without much care.

through some of the pinch grafts lost their viability and came away with the bandage, the remaining viable grafts proved capable of epithelizing the entire wound. Cosmetically it provided unsmart appearance at the recipient site and it was not much resistant to trauma. But from this comparative study on different techniques of skin grafts it was infered that pinch graft is a suitable technique of skin grafting in working animals like bovine where cosmetic appearance is of little value.

GROSS PERCENTAGE OF SUCCESS IN DIFFERENT TECHNIQUES OF SKIN GRAFTING IS AS FOLLOWING.

Types of grafting.	No. of animal	No. of wounds covered.	No. of failure.	Successful result		Percentage of unsuccessful grafts.
				No. of viable graft.	Percentage of viable graft.	
PINCH GRAFT.	4	8	-	8	100	-
SPLIT THICKNESS GRAFT.	4	8	2	6	75	25
FULL THICKNESS GRAFT.	4	8	3	5	62.5	27.5
PEDICLE GRAFT.	4	8	-	-	100	-

The split thickness graft provided encouraging percentage of success. The grafted area showed sparce hair growth, remained scaly and leathery due to lack of sebaceous glands but was pliable and resistant to trauma to a greater extent. Difficulty was faced in cutting the graft of uniform thickness by free

hand in absence of special instrument (Dermatome). Inspite of these objections it is concluded that owing to its high percentage of "take" and not very much susceptible to trauma, it can be a useful method of skin grafting for bovine wounds under field conditions.

The results obtained in full thickness grafts were not satisfactory as anticipated for bovine wounds. Only 62.5% success could be achieved in this study and that too after maximum care. Though this type of grafting provided strong repair, cosmetically better appearance in all respect, but it required optimal condition for its "take" which is a difficult, if not impossible task, to achieve in bovine. The other disadvantage encountered was the management of donor wound when larger piece of graft was taken. So in authors opinion this method can be useful for smaller wounds and that too on such sites only where perfect immobilisation of the part is possible.

The success achieved by pedicle grafting was cent percent. As the graft received its nutrition through the attached pedicle its survival seemed to present no problem. All the grafts applied in this study healed well and offered sound, strong and cosmetically better result in all respect. But the availability of loose skin for tube formation, limited this method to some selected sites only.

*****
***
*

TABLE NO. 1

Details of pinch grafts performed on surgically prepared wounds.

Buffalo calf No.	Experiment No.	Donor site	Recipient site	Size of wound to be grafted (inches)	No. of pinch graft seeded.	No. of pinch graft survived.	Percentage of success obtained.
1	1	Right thoracic wall ventral surface.	Lateral aspect of right forearm.	2x3	10	7	
	2	Right thoracic wall ventral surface.	Posteromedial surface of left forearm.	2x3	10	9	
2	3	Left thoracic wall lateral aspect.	Lateral aspect of left forearm.	1½x2½	8	8	
	4	Left thoracic wall lateral aspect.	Medial aspect of right forearm.	1½x2½	8	8	100
3	5	Left thoracic wall lateral aspect.	Dorsal metacarpel region of left forelimb.	1½x2	7	7	
	6	Left thoracic wall lateral aspect.	Posteromedial aspect of right forearm.	1½x2	7	6	
4	7	Right thoracic wall lateral aspect.	Lateral aspect of right forearm.	2x2½	9	7	
	8	Right thoracic wall lateral aspect.	Medial aspect of left forearm.	2x2½	8	8	

TABLE NO. 2.

Details of split graft performed on surgically prepared wound.

Buffalo Calf No.	Experiment No.	Donor site	Recipient site	Size of wound to be grafted (inches)	Fate of graft.	Percentage of success obtained.
5	9	Medial aspect of left thigh.	Lateral aspect of right forearm.	1½x2	Taken	
	10	Medial aspect of right thigh.	Lateral aspect of left forearm.	1½x2	Taken.	
6	11	Medial aspect of right forearm.	Lateral aspect of the left forearm.	1½x2	Taken.	
	12	Medial aspect of left thigh.	Lateral aspect of right thigh.	2x2½	Failed	
7	13	Lateral aspect of right forearm.	Medial aspect of left forearm.	1½x2	Taken	75
	14	Medial aspect of left thigh.	Lower third lateral aspect of right thigh.	2x2½	Taken	
8	15	Medial aspect of left forearm.	Lateral aspect of right forearm.	1x2	Failed	
	16	Medial aspect of left thigh.	Lateral aspect of right thigh.	1½x2½	Taken	

TABLE NO. 3.

Details of full thickness graft performed on surgically prepared wound.

Buffalo calf No.	Experiment No.	Donor site	Recipient site	Size of wound to be grafted (inches).	Rate of graft.	Percentage of success obtained.
9	17	Medial aspect of the left forearm.	Lateral aspect of the right forearm.	2x3	Taken.	
	18	Right lateral thoracic wall.	Medial aspect of the left forearm.	2¼x3¼	Taken.	
10	19	Lateral aspect of right forearm.	Lateral tibial region of right hind limb.	2x2½	Failed.	
	20	Right side of the Thorax.	Lateral aspect of right forearm.	2¼x3	Taken	62.5
11	21	Medial aspect of right metacarpal region.	Lateral aspect of left metacarpal.	1x1½	Taken.	
	22	Lateral aspect of left metatarsal region.	Medial aspect of right metacarpal.	1¼x2	Taken.	
12	23	Lateral aspect of right forearm.	Dorsal surface of the left forearm.	2x2½	Failed.	
	24	Right side of thoracic wall.	Lateral aspect of right forearm.	2½x3	Failed.	

TABLE NO. 4.

Details of pedicle graft performed on surgically prepared wound.

Buffalo calf No.	Experiment No.	Donor site	Recipient site	Size of wound to be grafted (inches).	Fate of graft.	Percentage of success obtained.
13	25	Posteromedial aspect of right forearm.	Lateral aspect of right	1½x2	Taken.	
	26	Posteromedial aspect of left forearm.	Lateral aspect of left forearm.	1½x2	Taken.	
14	27	Medial aspect of the right tibial region.	Lateral aspect of right tibial region.	1½x2	Taken.	
	28	Medial aspect of the right forearm.	Lateral aspect of the right forearm.	1½x2	Taken.	100
15	29	Posteromateral aspect of left forearm.	Dorsal aspect of left forearm.	Circular 2 inches diameter.	Taken.	
	30	Medial aspect of the right forearm.	Lateral aspect of right forearm.	,,	Taken	
16	31	Medial aspect of the thigh left hand limb.	Dorsal aspect of the tigh left hand limb.	1½x1½	Taken.	
	32	Lateral aspect of the left forearm.	Dorsal aspect of left forearm.	1½x1½	Taken.	

TABLE NO. 5

Total, differential counts and Hb % of the experimental animals.

Group No.	Buffalo calf No.	Hb. %	Total count R.B.C. million/cmm.	Total count W.B.C. Thousand/cmm.	Differential count Lymphocyte %	Differential count Monocyte %	Differential count Neutrophil %	Differential count Eosinophil %	Differential count Basophil %
I	1	9.6	4.6	9452	68	3	25	4	Nil.
	2	10.2	5.4	10050	66	5	26	3	Nil
	3	10.5	5.6	9231	67	5	23	4	1
	4	11.0	5.8	8795	69	4	24	3	Nil
II	5	11.2	6.5	10040	70	3	22	4	1
	6	10.5	5.5	10252	68	4	26	2	Nil.
	7	9.8	4.8	9660	66	5	27	2	Nil.
	8	11.0	6.0	8975	69	3	23	4	1
III	9	9.8	5.0	9892	65	4	26	4	1
	10	11.6	6.2	10005	67	3	27	3	Nil.
	11	10.8	5.6	10201	66	5	25	4	Nil.
	12	11.2	5.8	9754	68	4	26	2	Nil.
IV	13	12.0	7.11	9960	71	3	22	3	1
	14	10.5	5.2	10008	68	5	23	4	Nil
	15	11.5	6.0	9795	65	4	28	2	1
	16	9.6	5.8	10735	66	5	27	2	Nil.

TABLE NO. 6.

Average temperature, pulse and respiration of the different groups of experimental animals pre-operatively.

Days	Time	Group-I.			Group-II			Group-III			Group-IV.		
		Tempe-rature	Pulse	Respi-ration	Tempe-rature	Pulse	Respi-ration	Tempe-rature	Pulse	Respi-ration	Tempe-rature	Pulse	Respira-tion.
1	M	100.4	50	12	100.5	49	13	100.5	49	12	100.8	50	11
	E	100.8	52	14	100.8	51	14	101.2	52	14	101.0	51	13
2	M	100.2	50	12	100.8	50	12	100.8	48	13	100.5	49	12
	E	101.0	54	15	101.5	54	15	101.0	52	15	101.2	52	15
3	M	100.5	52	13	100.6	48	11	100.4	47	12	100.4	48	13
	E	101.2	55	15	101.2	51	13	101.2	49	13	100.8	50	15
4	M	100.5	50	12	100.2	49	12	100.8	48	11	100.2	47	12
	E	101.0	52	14	100.8	52	14	101.5	52	14	101.0	49	13
5	M	100.8	50	11	100.2	46	12	100.4	49	12	100.5	51	14
	E	101.5	54	13	101.4	50	15	101.5	55	15	101.2	53	15
6	M	100.6	49	12	100.5	45	13	100.2	48	11	100.8	49	13
	E	101.0	54	15	101.0	49	15	100.8	50	15	101.5	55	16
7	M	100.2	50	13	100.2	49	12	100.8	51	12	100.2	48	11
	E	101.4	55	15	101.0	51	14	101.4	55	15	100.8	52	13

M = morning. E = evening.

The above average figures are obtained from the daily recordings of temperature, pulse and respiration of experimental animals till 7th pre-operative days.

TABLE NO. 7.

Average temperature, pulse and respiration of different groups of experimental animals post-operatively.

Days	Time	Group-I.			Group-II.			Group-III.			Group-IV.		
		Tempe-rature	Pulse	Respi-ration	Tempe-rature	Pulse	Respi-ration	Tempe-rature	Pulse	Respi-ration	Tempe-rature	Pulse	Respi-ration.
1	M	100.8	51	13	101.4	53	14	100.6	52	12	100.8	50	12
	E	101.6	56	15	101.8	55	14	100.8	56	13	101.2	54	13
2	M	101.0	54	12	102.0	57	15	100.5	50	14	101.4	53	14
	E	101.8	56	14	102.2	58	16	101.2	54	16	101.6	56	16
3	M	100.8	50	11	101.0	54	12	101.0	55	15	101.0	52	12
	E	101.2	53	14	101.4	56	14	101.8	58	16	101.5	54	13
4	M	100.5	49	12	100.5	53	12	101.2	54	13	100.8	51	11
	E	100.8	50	15	101.2	55	14	101.6	56	15	101.4	56	14
5	M	100.2	48	13	100.0	50	11	100.8	52	12	100.2	49	12
	E	100.8	50	14	100.5	54	13	101.2	55	14	100.8	51	13
6	M	100.4	53	12	100.0	49	12	100.8	50	11	101.0	53	14
	E	101.2	56	15	100.5	52	14	101.5	56	15	101.2	53	14
7	M	100.4	52	11	100.5	50	13	100.4	51	12	100.6	50	11
	E	101.0	55	13	101.0	54	15	100.8	54	14	101.0	54	13

M = morning. E = evening.

The above average figures are obtained from the daily recordings of temperature, pulse and respiration of experimental animals till 7th day post-operative days.

BAR DIAGRAM SHOWING PERCENTAGE OF SUCCESS IN DIFFERENT TYPES OF SKIN GRAFTING



15 Small Sq. = 10%

AVERAGE TEMPERATURE, PULSE AND RESPIRATION OF THE DIFFERENT GROUPS OF EXPERIMENTAL ANIMALS PRE-OPERATIVELY

GROUP I GROUP II

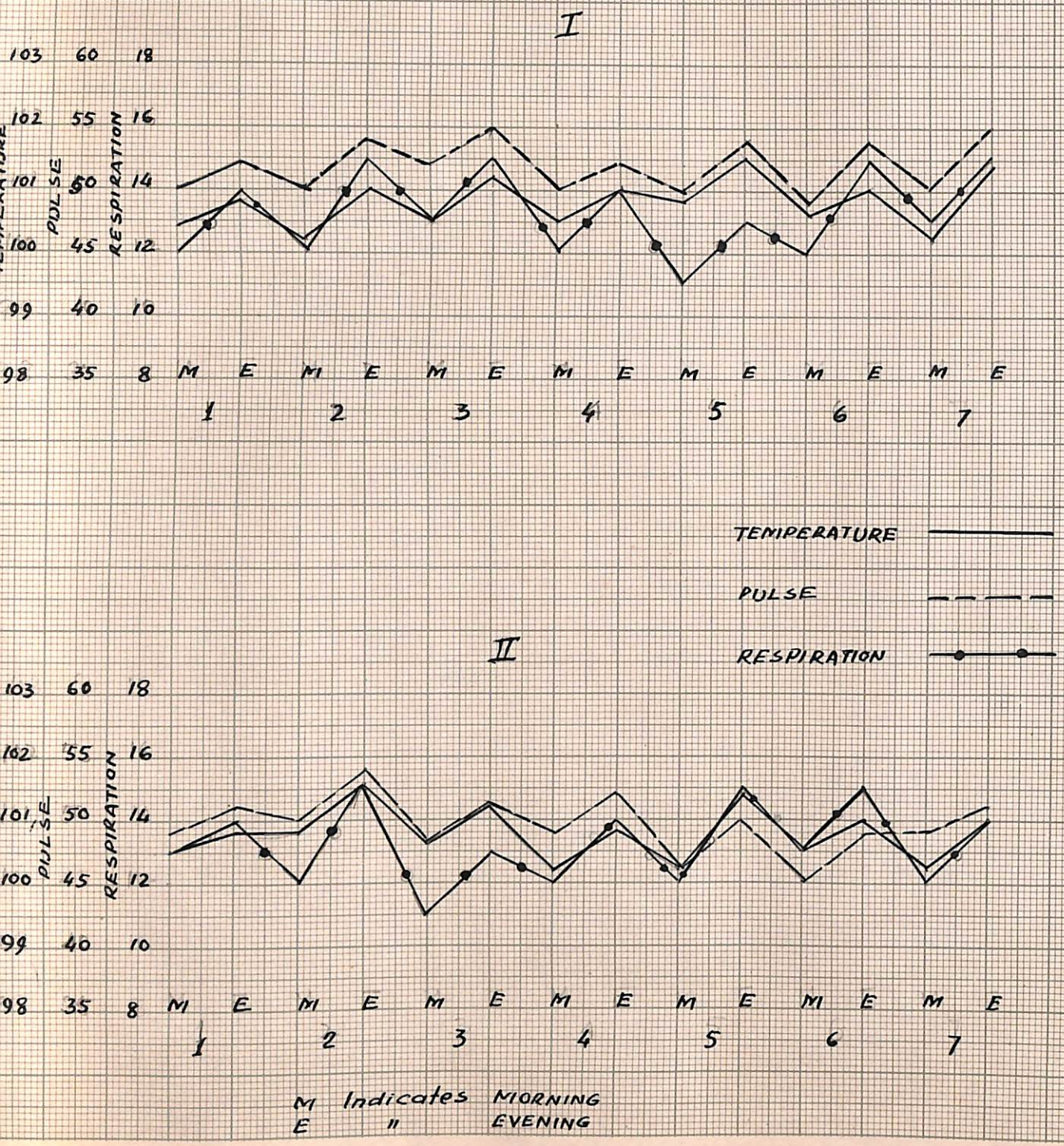

M Indicates MORNING
E " EVENING

AVERAGE TEMPERATURE, PULSE AND RESPIRATION OF THE DIFFERENT GROUPS OF EXPERIMENTAL ANIMALS PRE-OPERATIVELY

GROUP III GROUP IV

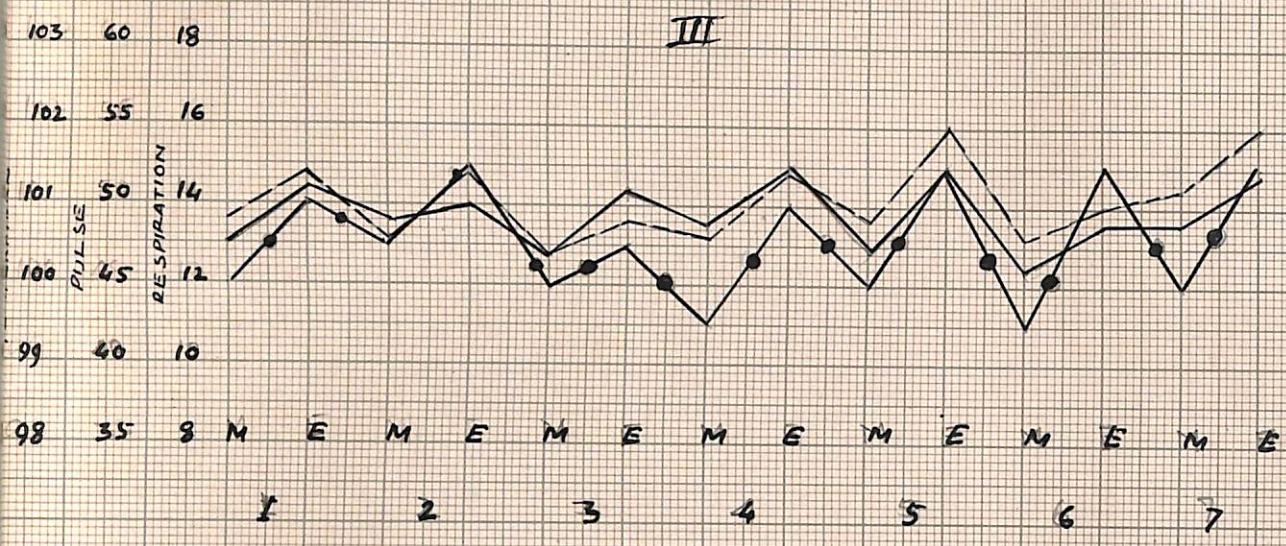

TEMPERATURE ———

PULSE — — — —

RESPIRATION —●—●—

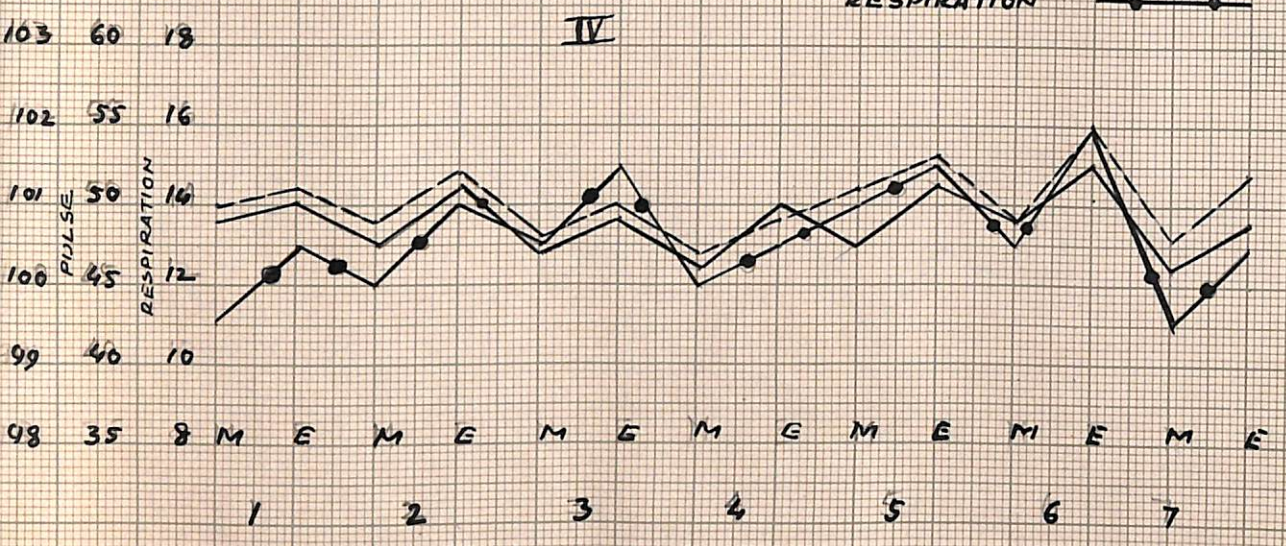

M Indicates MORNING
E " EVENING

AVERAGE TEMPERATURE, PULSE AND RESPIRATION OF DIFFERENT GROUPS OF EXPERIMENTAL ANIMALS POST OPERATIVELY

GROUP I - GROUP II

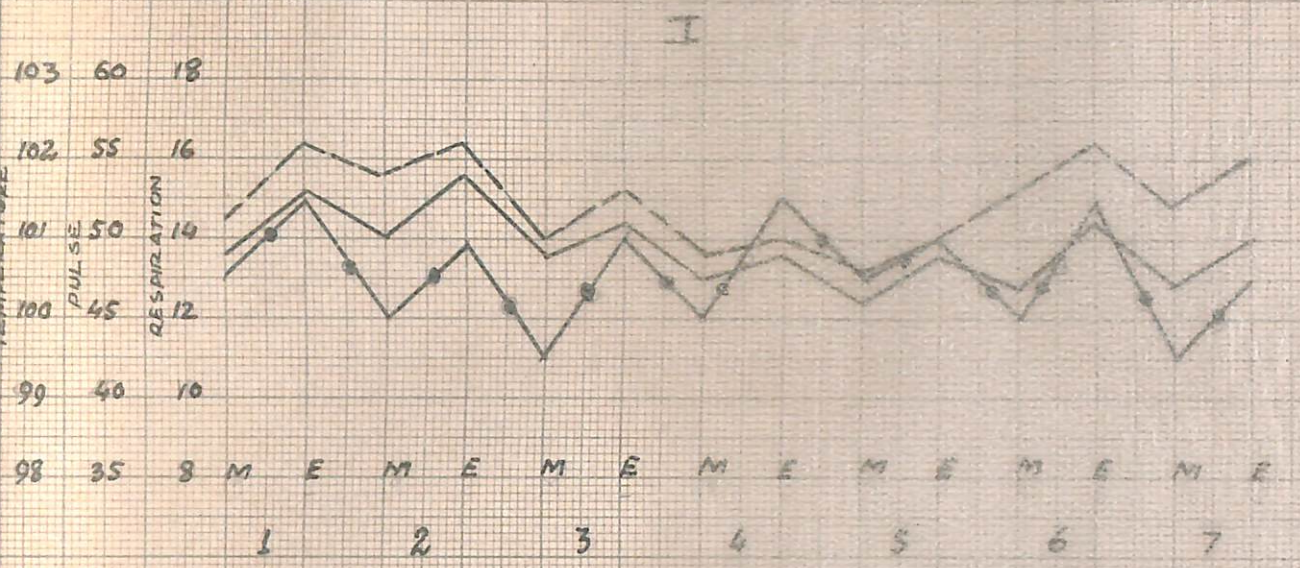

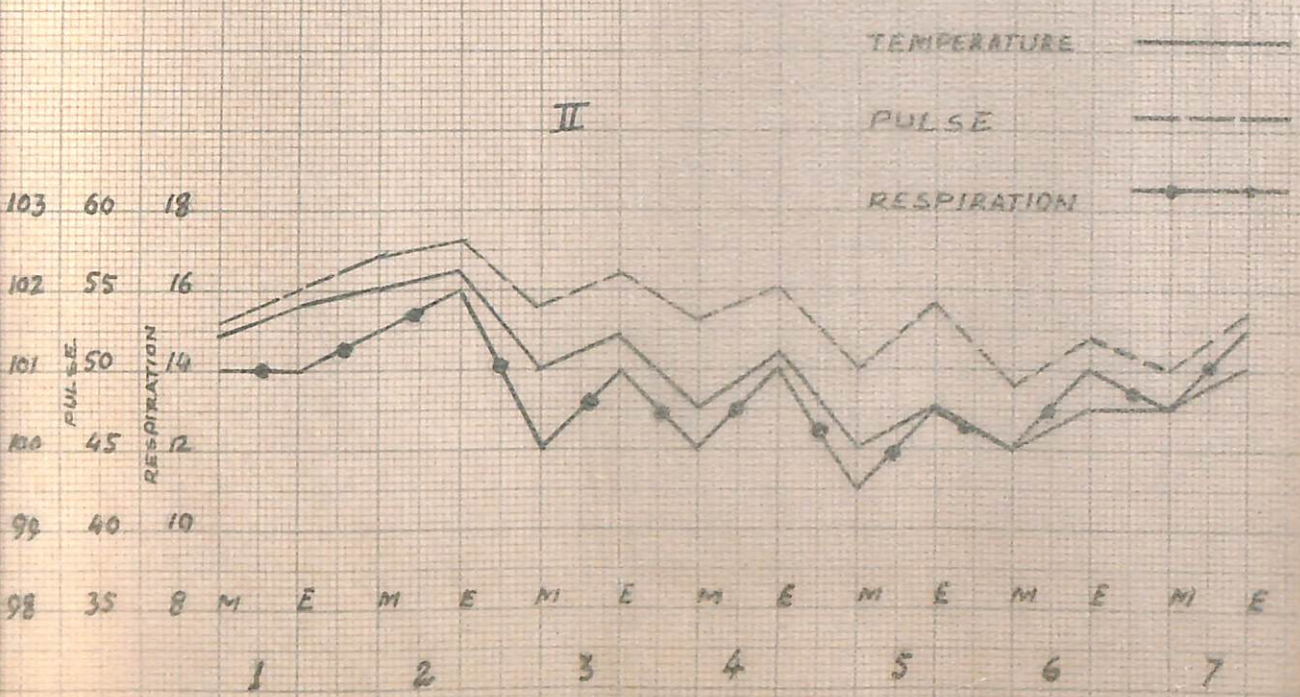

M Indicates MORNING
E " EVENING

AVERAGE TEMPERATURE, PULSE AND RESPIRATION OF DIFFERENT GROUPS OF EXPERIMENTAL ANIMALS POST OPERATIVELY

GROUP I - GROUP II

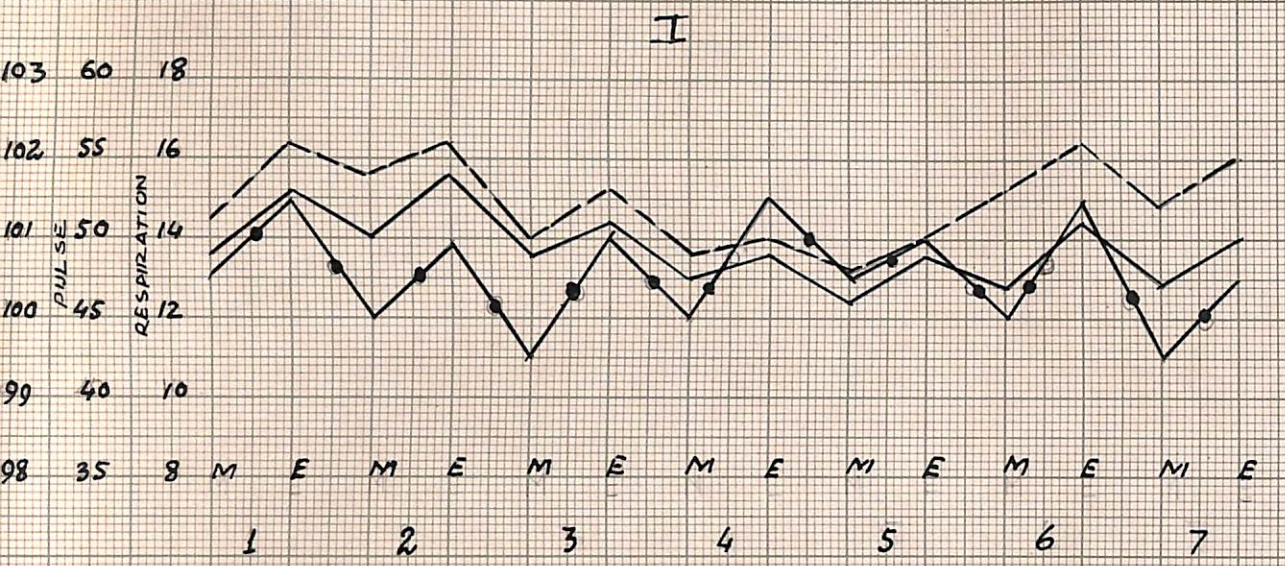

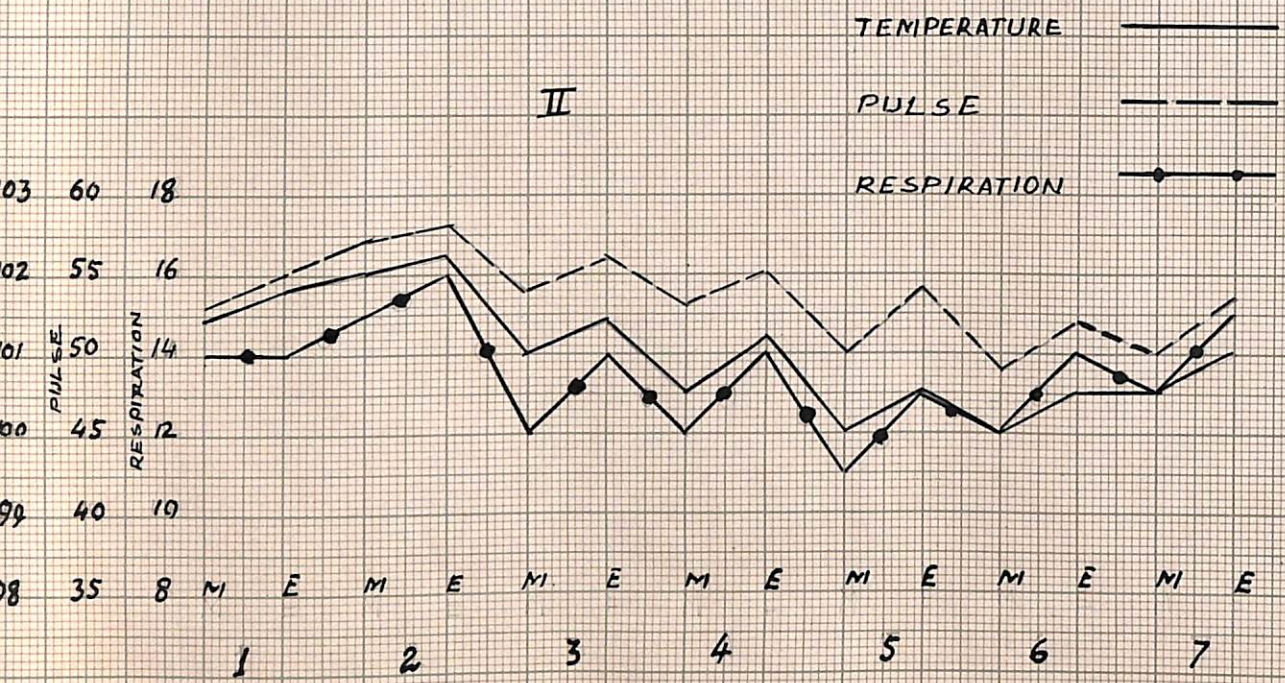

M Indicates MORNING
E " EVENING

AVERAGE TEMPERATURE, PULSE AND RESPIRATION OF DIFFERENT GROUPS OF EXPERIMENTAL ANIMALS POST OPERATIVELY

GROUP III GROUP IV

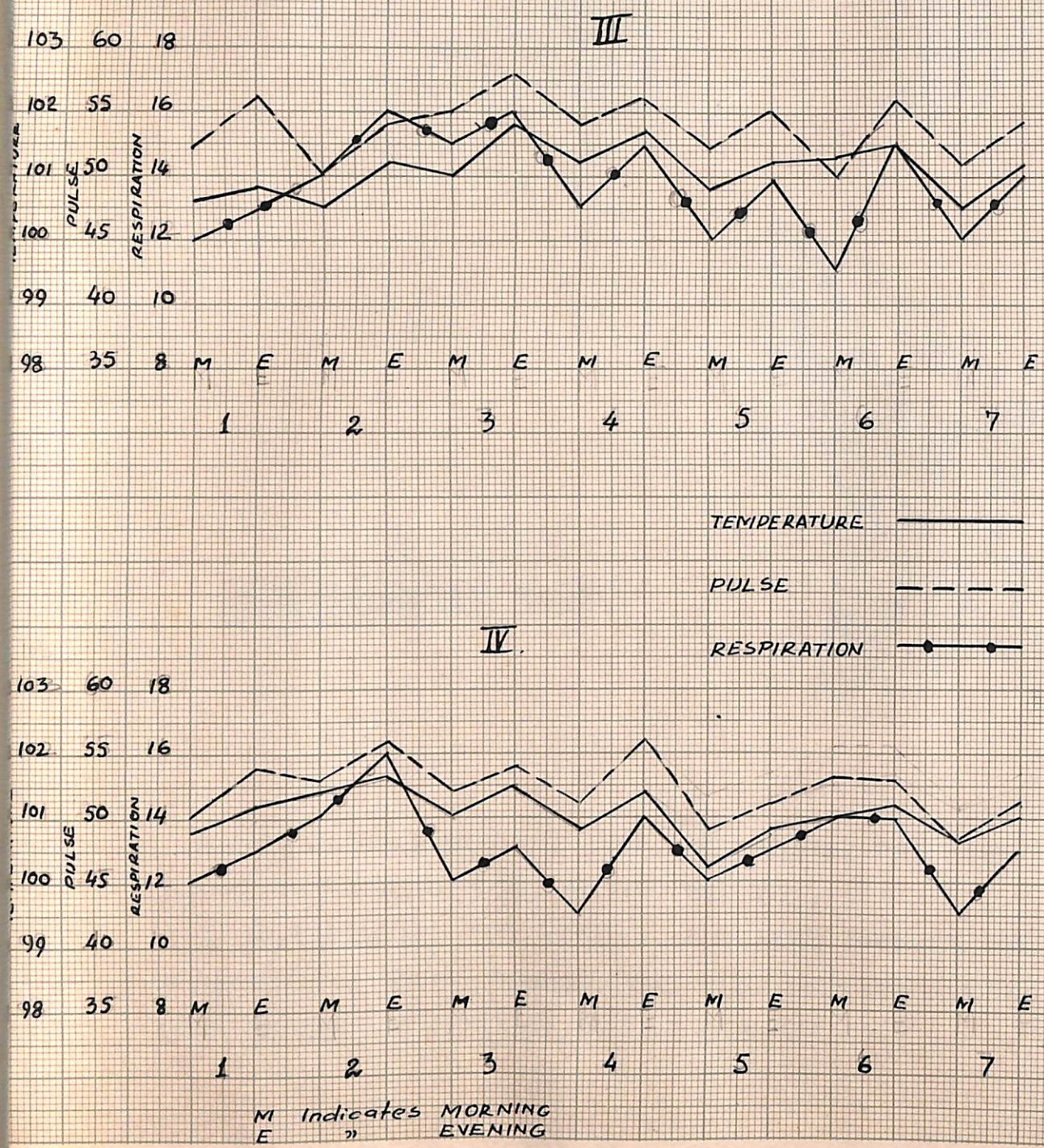

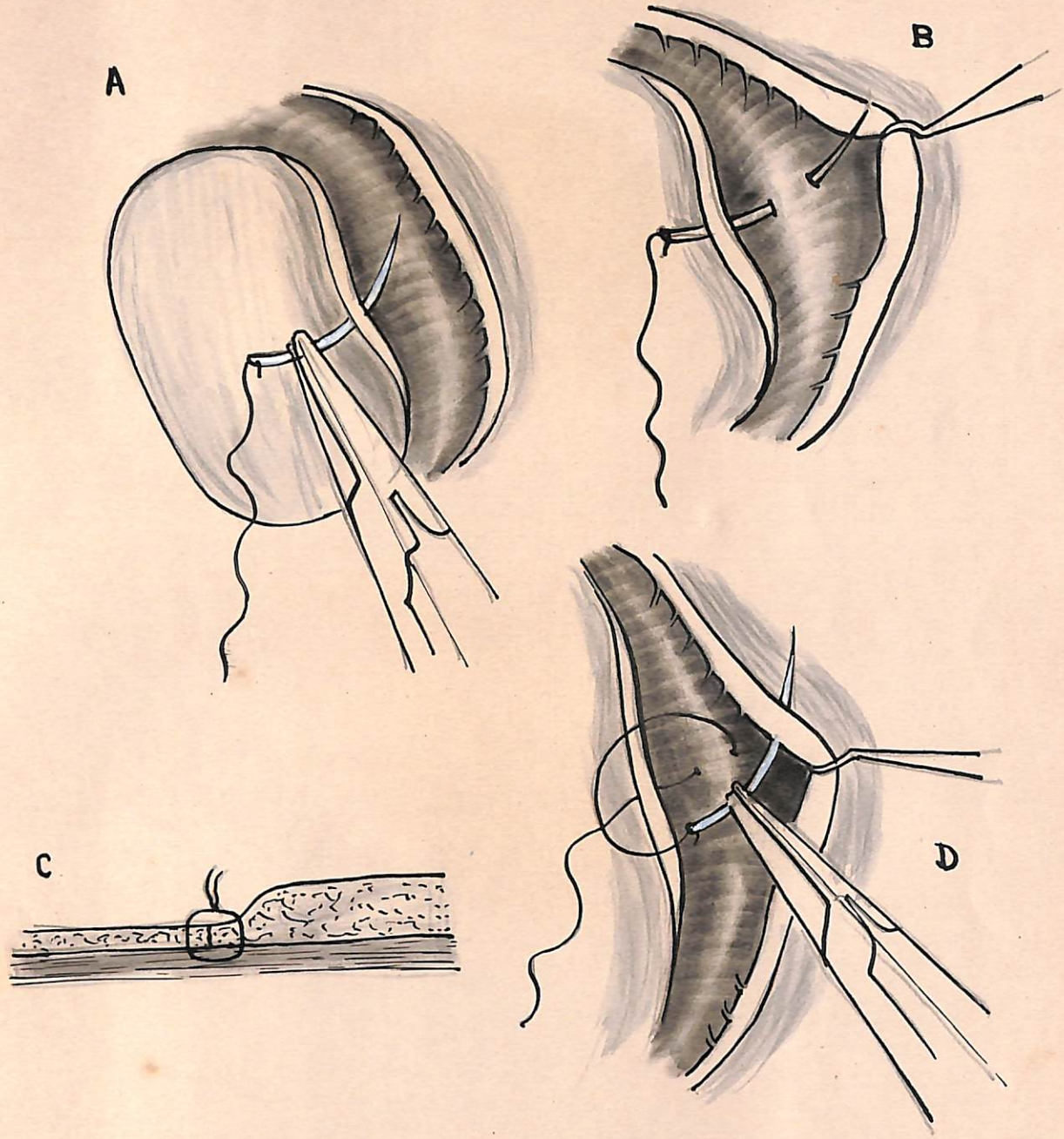

THREE-POINT SUTURE FOR ANCHORING THE EDGE OF THE SKIN GRAFT TO THE EDGE OF THE DEFECT.

A, B, C AND D. THE NEEDLE IS PLACED THROUGH THE EDGE OF THE SKIN GRAFT, THROUGH THE TISSUE IN THE RECIPIENT BED, THEN THROUGH THE EDGE OF THE DEFECT.

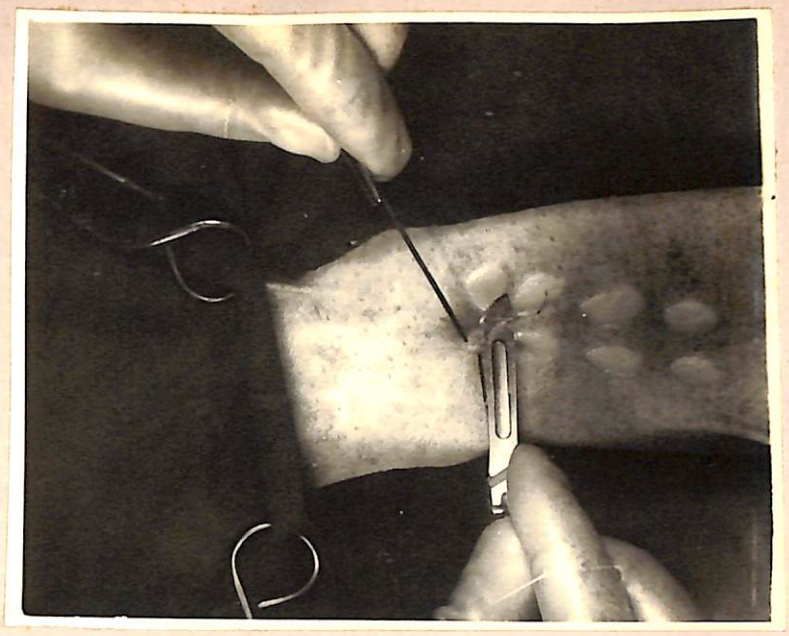

Plate No. 1

Method of cutting pinch grafts.

Plate No. 2

Method of transplantation of pinch grafts.

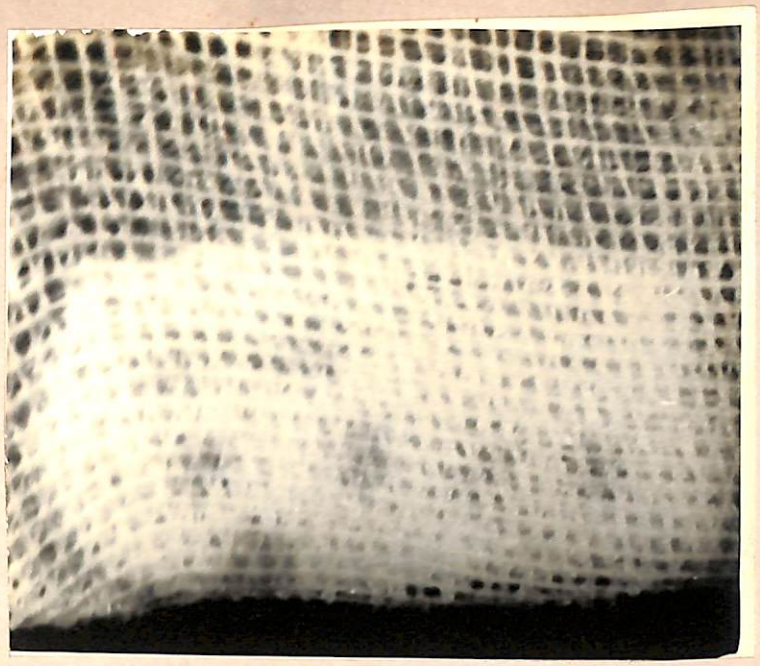

Plate No. 3

The grafted site covered with Jelonet after operation.

Plate No. 4

Showing completely healed pinch grafts.

Plate No. 5

Healed pinch grafts giving "Cobble stone" appearance.

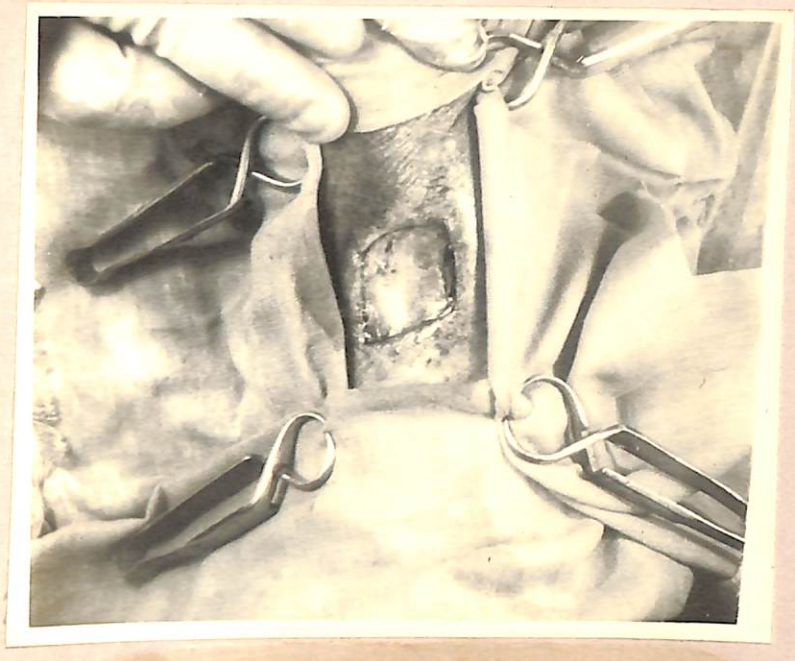

Plate No. 6

Recipient wound before grafting with split graft.

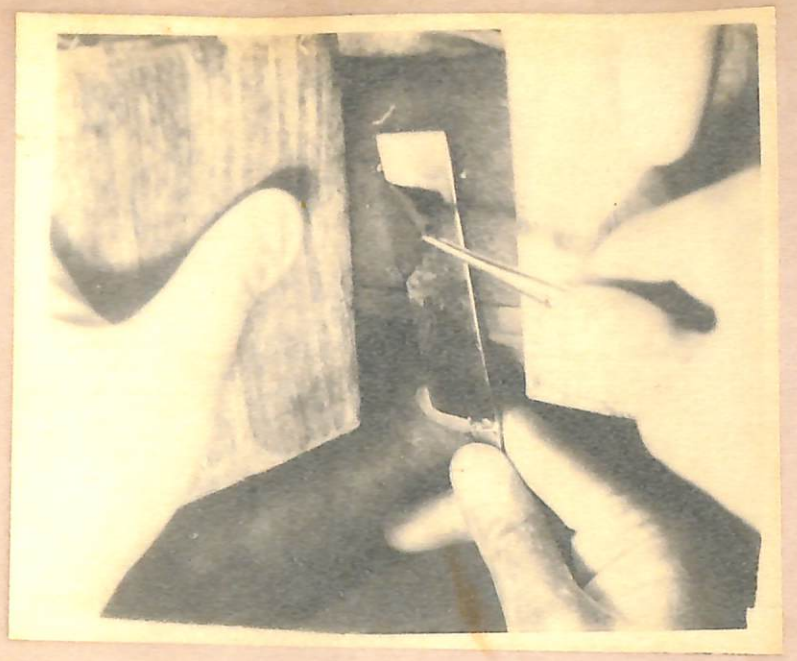

Plate No. 7

Method of cutting split graft.

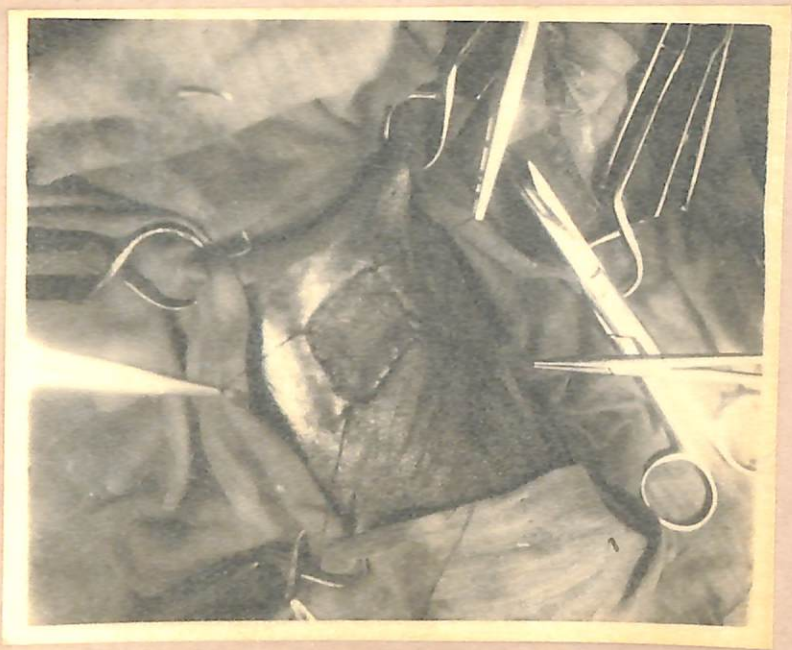

Plate No. 8

Showing split graft anchored at four points after transplantation.

Plate No. 9

Completely healed split thickness graft showing scalyness on grafted area.

Plate No. 10

Prepared recipient wound for full thickness graft.

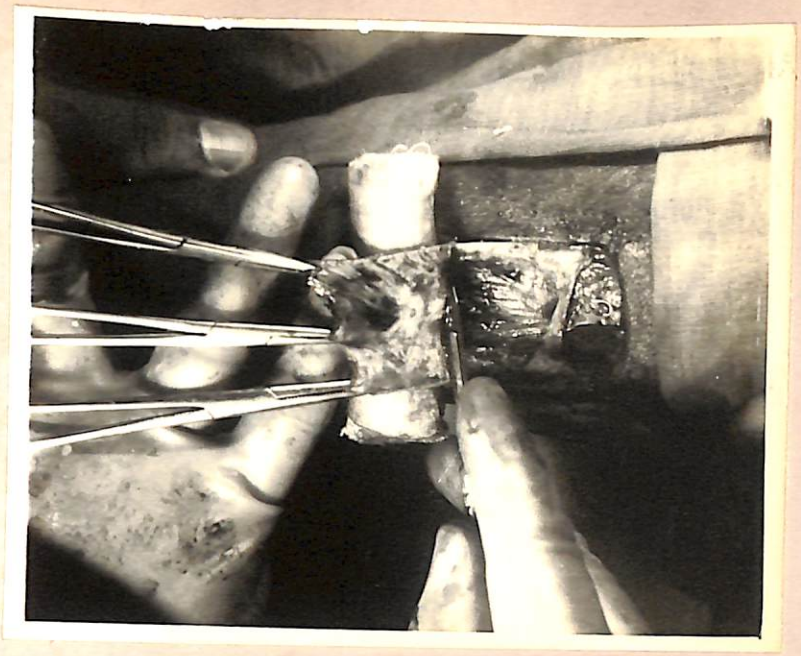

Plate No. 11

Showing the technique of cutting full thickness graft.

Plate No. 12

Full thickness skin grafted and anchored at four corners with intrupted sutures.

Plate No. 13

Showing the edge of the graft approximated with the wound margin with several interrupted sutures. Photo also showing three stab wounds on graft surface meant for drainage.

Plate No. 14

A completely healed full thickness graft. The grafted area showing no marked difference in colour with the surrounding skin.

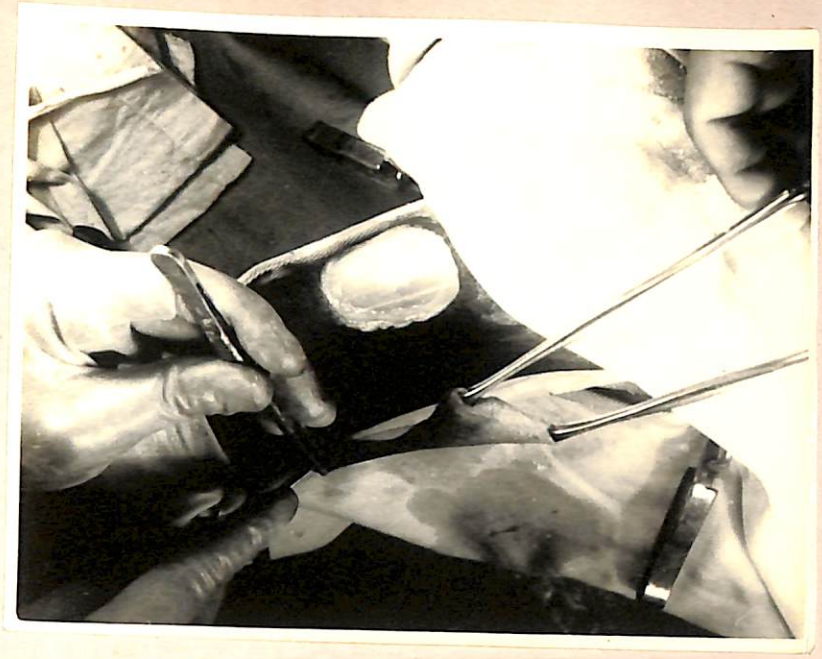

Plate No. 15

Showing the pedicle flap and the recipient wound to be grafted.

Plate No. 16

The prepared tube and flap before grafting.

Plate No. 15

Showing the pedicle flap and the recipient wound to be grafted.

Plate No. 16

The prepared tube and flap before grafting.

Plate No. 17

Showing the tubed flap approximated with the wound margin with several intermupted sutures.

Plate No. 18

Healed pedicle graft on fourteenth day, after removal of sutures and before severing the pedicle.

Plate No. 19

Section of normal skin. Note the normal epidermal pegs, sweat glands, sebaceous glands and hair follicles. (H. & E., 10x10).

Plate No.20

Section of pinch graft. Note the sebaceous gland, sweat gland and hair follicle in grafted area. (H.& E. 10x10).

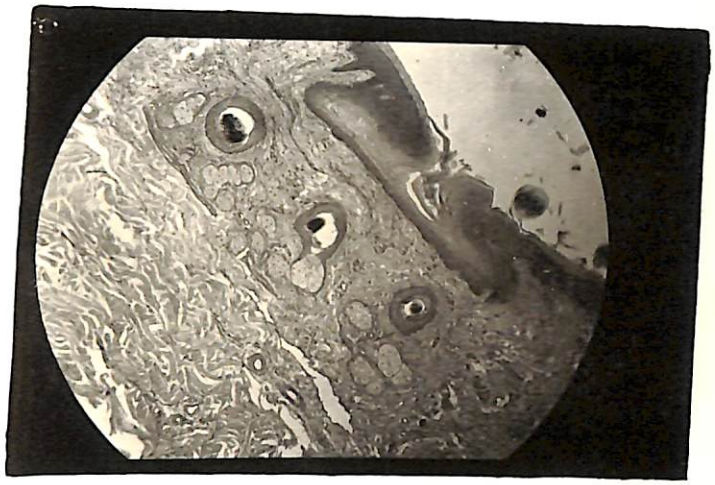

Plate No. 21

Section of pinch graft at the junction showing a row of sebaceous glands, hair follicles under the line of union.(H. & E. 10x10).

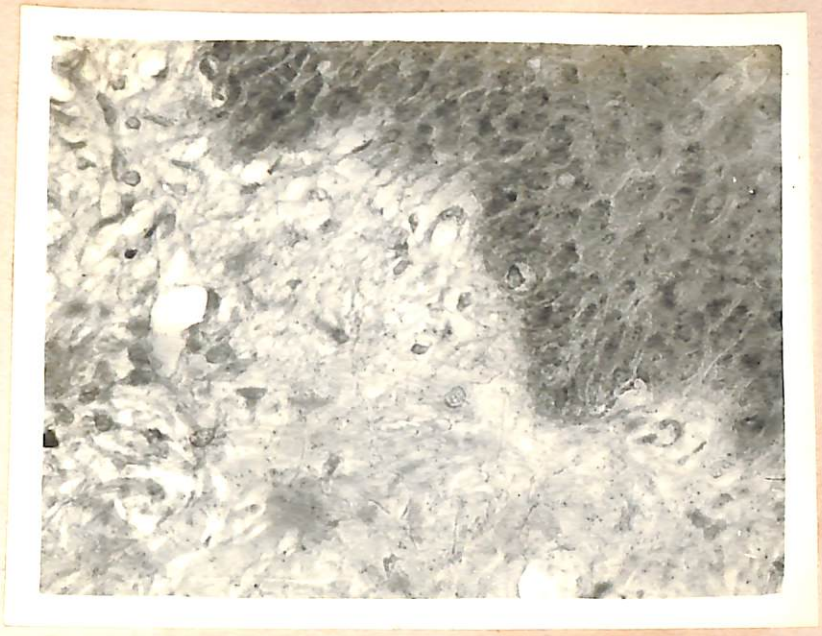

Plate No. 22

Section of pinch graft under high magnification showing fibrous tissue growth. (H. & E. 10x40).

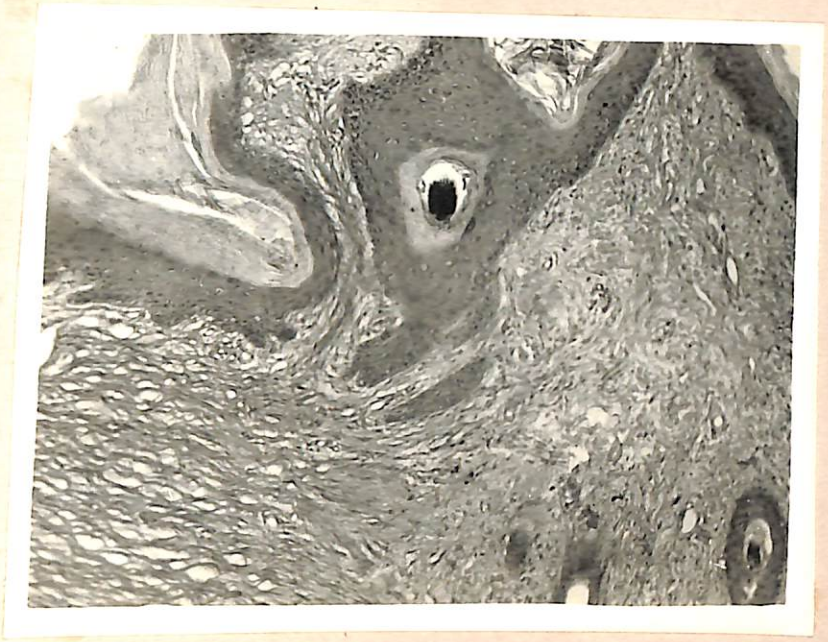

Plate No. 23

Section of split graft. Note epidermal cell differentiation, absence of epidermal pegs, large number of fibroblasts cells, fibrous tissue and hair follicles. (H.&.E. 10x10).

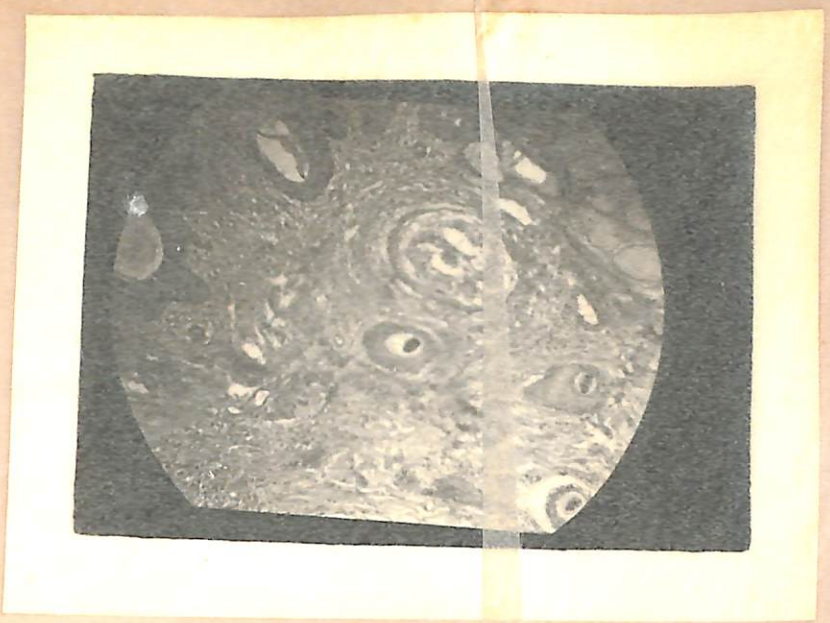

Plate No. 24

Section of split graft showing fibrous tissue and hair follicles. (H. & E. 10x10).

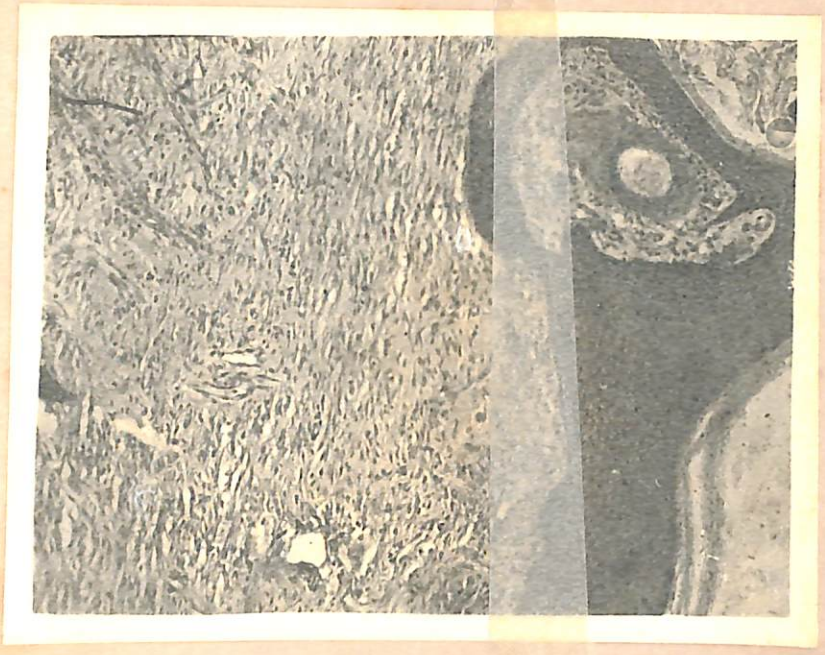

Plate No. 25

Section of full thickness graft showing straight disposition of epidermis at the line of junction. Note hair follicle and fibrous tissue with leucocytic infiltration. (H. & E. 10x10).

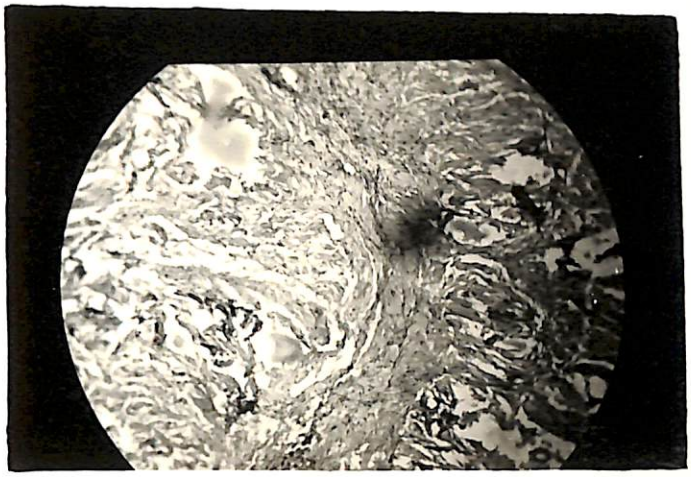

Plate No. 26

Section of full thickness graft (deeper layer) showing large number of fibroblasts cells with fibrous connective tissue at the line of junction. The collagen bundles are seen towards normal side. (H.& E. 10x10).

Plate No. 27

Section of full thickness graft showing large number of fibrous tissue and fibroblast cells with leucocytic infiltration and wide meshed capillaries.(H.& E. 10x10).

Plate No. 28

Section of pedicle graft showing straight disposition of epidermis at the junction with marked fibrous tissue and leucocytic infiltration. (H. & E. 5x10).

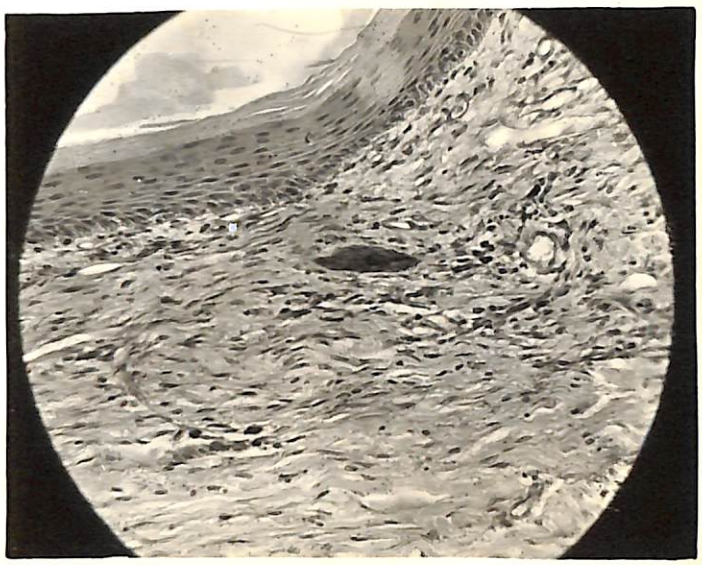

Plate No. 29

Photomicrograph of pedicle graft showing clear cut epidermal cell differentiation with straight disposition of epidermis. Note very pronounced leucocytic infiltration at the line of junction. (H. & E. 5x40).

REFERENCES

R E F E R E N C E S

Ammann, K. (1952) Cited by Wallace, A.B., Spreull, J.S. and Hamilton, H.A. (1962). The use of autologous free full thickness skin graft in the treatment of chronic inflammatory skin lesions in dog. Vet.Record, 74 : 286.

Archibald, J. (1965) Procedure in plastic surgery. J.Am.Vet.Med.Assoc., 147:1461.

Barsky, A.J. (1950) Principles and practice of plastic surgery, pp. 26. The Williams & Wilkins Company, Baltimore.

Baronio, G. (1804) Cited by Rogers, B.O. (1959). Transplantation of tissues.Vol.II pp.73. Edited by Peer, L.A. The Williams & Wilkin Company, Baltimore.

Billingham, R.E., and Medawar, P.B. (1951) The techniques of free skin grafting in mammals. J.Exp. Biol., 28: 385.

Blair, V.P. (1921) The delayed transfer of long pedicle flaps in plastic surgery. Surg., Gynec. & Obst., 33 : 261.

Blair, V.P. (1924) Full thickness skin grafts. Ann. Surg., 80 : 298.

Blair, V.P., and Brown, J.B. (1929) The use and uses of large split skin grafts of intermediate thickness. Surg., Gynec & Obst., 49 : 82.

Boyd, C. L. (1967) Equine skin transplants. S.West.Vet., 20 : 265. (Vet.Bull., 38 ; Abs., 835.)

Boyd, C.L. and Hanselka, D.V. (1971) Skin punch technique for equine skin grafting. J.Am.Vet.Med.Assoc., 158 : 82.

Brown, J.B. and McDowell, F. (1941) Persistence of functions of skin grafts through long periods of growth. Surg., Gynec. & Obst., 72:848.

Brown, J.B. and McDowell, F. (1942) Massive repairs of burns with thick split skin grafts, Emergency Dressings with Homografts. Ann. Surg., 115: 658.

Brown, J.B. and McDowell, F. (1942) Epithelial healding and the transplantation of skin. Ann. Surg., 115: 1166.

Brenizer, A.G. (1940) Skin and fascia grafting. Am. J. Surg., 47 : 265.

Bromberg, B.E., Song, J., Kochnlein, E. and Mohn, M.P. (1964) Non suture fixation of split thickness skin graft. Surg., 55 : 846.

Bunger, C. (1823). Cited by Rogers, B.O. (1959). Transplantation of tissues, Vol.II, pp. 73. Edited by Peer, L.A. The Williams & Wilkins Company, Baltimore.

Cannon, B. and Murray, J.E. (1957) Physiologic principles of surgery, pp. 81. Edited by Zimmerman, L.M. and Levine, R., W.B. Saunders Company, Philadelphia & London.

Carpue, J.C. (1816) Cited by Koch, S.L. (1941). The transplantation of skin and subcutaneous tissue to the hand. Surg., Gynec. & Obst., 72:1.

Chanana, A.D., Brecher, G. and Cronkite, E.P. (1966) Histologic observation on skin autografts, isografts and allografts in cattle. Am.J. Path., 49 : 1125.

Cowley, A.J. and Francis, S.M.	(1958)	Cited by Wallace, A.B., Spreull, J.S. and Hamilton, H.A.(1962). The use of autogenous free full thickness skin grafts in the treatment of chornic inflammatory skin lesions in dog. Vet.Record, 74 : 286.
Cowley, A.J.	(1965)	Canine Surgery. Edited by Archibald, J., 1st Ed., pp. 149. American Vet.Publication INC., Illinois.
Converse, J.M.	(1942)	Early skin grafting in war wounds of the extremities. Ann. Surg., 115 : 321.
Converse, J.M.	(1962)	Skin Surgery. By Epstein, E., 1st Ed., pp. 92. Lea & Febiger, Philadelphia.
Copenhaver, W.M.	(1964)	Bailey's Text book of Histology, 5th Ed., pp. 332. The Williams and Wilking Company, Baltimore.
Davis, J.S. and Kitlowski, E.A.	(1938)	Cited by Padgett, E.C.(1948). Plastic and Reconstructive surgery, 1st Ed., pp. 18. Charles C Thomas, Publisher Springfield, Illinois, U.S.A.
Davis, J.S. and Traut, H.F.	(1925)	Origin and development of blood supply of whole thickness skin grafts. Ann.Surg., 82 : 871.
Davis, J.S.	(1940)	Use of small deep grafts in the repair of surface defects. Am.J.Surgery, 47 : 280.

okiouliyar, U.K. (1967) Autogenous skin grafting in canine. M.V.Sc.Dissertation No. 121, Madras University, Department of Suggery, Southern Regional Institute of Post-Graduate Studies and Research.

effenbach, J.F. (1824). Cited by Koch, S.L. (1941). The transplantation of skin and subcutaneous tissue to the hand. Surg., Gynec. & Obst., 72:1.

oganeli, M.Z. (1969) An experimental study on skin grafting of large superficial wounds on dairy cow's teat. Vet.Fak.Derg.Ankara Univ., 16:207. (Vet.Bull., 40 : Abs., 4675).

ouglas, B. (1930) Sieve graft. Surg., Gynec.& Obst., 50:1018.

ragstedt, L.R. nd Wilson, H. (1937) A modified sieve grafts. A full thickness graft for covering large defects. Surg., Gynec.& Obst., 65:104.

ilatoff, W. (1916) Cited by Padgett, C.E. (1948). Plastic and Reconstructive Surgery, 1st Ed., pp.18 Charles C Thomas. Publisher Springfield, Illinois, U.S.A.

ranklin, L.A. and obert, F.S. (1959) Technique of homotransplantation of skin in mice and rats. Vet. Med., 54 : 470.

ibbens, R. (1957) Patellectomy and a variation of paatsama's operation on the Anterior cruciate ligament of dog. J.Am.Vet.Med.Assoc., 131:557.

Gius, J.A. (1962) Fundamentals of general surgery, 2nd Ed., pp.56. Oxford and I.B.H.Publishing Co., New Delhi.

Gillies, H.D. (1917) Cited by Padgett,E.C.(1948). Plastic and reconstructive surgery, 1st Ed., pp. 18 Charles C Thomas. Publisher Springfield. Illinois,U.S.A.

Goel, H.C. and Nayak, N.A. (1971) A trephine for skin transplantation. Indian J.Med.Res., 59 :1578

Graham-Jones, O. (1967) Some thoughts on transplantation and the Veterinary surgeon. Vet. Record, 80 : 65.

Ham, A.W. (1965) Histology. 6th Ed., pp.638 J.B.Lippincott Company. Igakushoin Ltd.Philadelphia and Toronto, Tokyo.

Hanfied-Jones, R.M. and Porrit, A.E. (1948) The essentials of modern surgey, 3rd Ed., pp.173. E. & S.Livingstone Ltd., 16 & 17 Teviot place, Edinburgh.

Hickman, J.L., Rudall, K.M. and Wickham,G.A. (1962) Storage of foetal sheep skin and its growth as an autografts on lamb. Nature. Lond., 194 : 394 (Vet.Bull.,32 ; Abs., 3950.

Higgins,G.A. and Orr, T.G. (1958) Orr's operation of general surgery, 3rd Ed., pp.69 W.B. Saunders Company, Philadelphia and London.

Hogle, R., Kingrey, B.W. and Jensen, E.C. (1959) Skin grafting in horse. J.Am.Vet.Med.Assoc., 135:165.

Hughes, H.V. (1960) The skin of the dog. Brit.Vet.J., 116: 340.

Jensen, E.C. (1959) Canine autogenous skin grafting. Am. J.Vet.Res., 20:898.

Keef, F. (1946) Skin grafting in cat. J.Am.Vet.Med.Assoc., 108: 43.

King, M.K. (1945) Immediate skin grafting following injuries. Surg., Gynec. & Obst., 81:75

Koch, S.L. (1941) The transplantation of skin and subcutaneous tissue to the hand. Surg., Gynec. & Obst., 72:157.

Kraus, F. (1876) Cited by Padgett, E.C. (1948) Plastic and Reconstructive surgery, 1st Ed., pp. 41. Charles C. Thomas. Publisher Springfield. Illinois. U.S.A.

Lefort, L. (1872) Cited by Padgett, E.C. (1948). Plastic and reconstructive surgery, 1st Ed., pp.41 Charles C Thomas, Publisher. Springfield. Illinois. U.S.A.

Lowson. (1872) Cited by Rogers, B.O. (1959). Transplantation of tissues Vol. II, pp. 73. Edited by Peer, L.A. The Williams and Wilkins Company Baltimore.

Markowitz, J., Archibald, J. and Downie, A.G.	(1959)	Experimental surgery, 5th Ed., pp. 292. The Williams & Wilkins Company. Baltimore.
Medawar, P.B.	(1944)	The Behaviour and fate of skin autografts and skin homografts in Rabbits. J. Ant., 78 : 176.
Moraes, C.C. and Ribeino, F.M.	(1953)	Skin grafts in treatment of hernia and ewentration of abdominal wall. Rev.Brasil.Cir., 26 : 273. (September, 1953). J.A.M.A., (1954), 155: 520.
Neal, P.A.	(1958)	Skin grafting in horses - A report of 3 cases. Vet. Record, 70 : 401.
Neal, P.A.	(1961)	Skin grafting in the treatment of granulating wounds of the horse's legs. Vet.Record, 73 : 1399
Nitolitchi.	(1879)	Cited by Padgett, E.C.(1948). Plastic and Reconstructive surgery, 1st Ed., pp. 41 Charles C Thomas. Publisher Springfield. Illinois. U.S.A.
Odland, G.F.	(1966)	Skin Histology, 2nd Ed., pp.420 By R.O. Greep. 2nd Ed., pp.420. The Blackiston Division, McGraw Hill Book Company, New York.
Ollier, L.X.E.L.	(1872)	Cited by Rogers, B.O.(1969) Transplantation of tissues, Vol.II, pp. 73. Edited by Peer, L.A. The williams and Wilkins Company, Baltimore.

Padgett, E.C. (1948) Plastic and reconstructive surgery, 1st Ed.,pp. 18. Charles, C. Thomas. Publisher. Springfield. Illinois. U.S.A.

Pullen, C.M. (1969) Surgical repair of skin defects by full thickness sliding flap. Veterinary Medicine/Small Animal Clinican,64:589.

Raghavan, D. (1964) Anatomy of ox. pp. 695. I.C.A.R., New Delhi.

Reverdin, J.L. (1869) Cited by Koch, S.L. (1941). The transplantation of skin and subcutenous tissue to hand. Surg.,Gynec. & Obst.,72: 1.

Ross, G.E.,Jr. (1968) Clinical canine skin grafting. J.Am.Vet.Med.Assoc.,153:1759.

Rogers, B.B. (1959) Transplantation of tissues, Vol.II, pp. 73. Edited by Peer,L.A. (1959). The Williams and Wilkins Company. Baltimore.

Sahu, S. and Singh, S.C. (1971) Full thickness skin grafting in bullock. Ind.Vet.J., 48 : 1070.

Schebitz. (1955) Cited by Wallace, A.B., Spreull,J.S. and Hamilton, H.A. (1962). The use of autologous free full thickness skin grats in the treatment of chronic inflammatory skin lesions in dog. Vet. Record, 74 : 286.

Singh, L.P., Prasad, G. and Yadava, R.C.P.	(1971)	Microscopic studies on the skin of dorsal region of Indian buffalo calves. Unpublished Article. (Through personal communication).
Self, R.A.	(1934)	Skin grafting in canine practice. J.Am.Vet.Med.Assoc., 84:163.
Sisson, S. and Grossman, J.D.	(1962)	The anatomy of the Domestic Animals. 4th Ed. pp. 906. W.B.Saunders Co. Philadelphia and London. Charles E.Tuttle Co. Tokyo.
Smith, M.P., Marks, D.	(1968)	A skin grafting techniques in horses. J.Am.Vet.Med.Assoc., 152:1633.
Spreull, J.S.	(1962)	The clinical use and value of skin transplantation in dog. Advances in small animal Practice IV. pp.41. Pragmon Press, Oxford.
Thiersch, K.	(1874)	Cited by Converse, J.M.(1962). Skin Surgery by Epstein, E. 2nd Ed. pp.92 Lea & Febiger Philadelphia.
Trautman, A. and Fiebiger, J.	(1957)	Fundamentals of the Histology of Domestic Animals. Revised and translated by Habel, R.E. and Biberstein, E.L. from 8th and 9th Ed.(1949) pp. 334. Comstock Publishing Associates, ITHACA, NEW YORK.

Ubereiter, O.	(1956)	Cited by Neal, P.A.(1961). Skin grafting in the treatment of the horses legs. Vet. Record, 73 : 1399.
Unwin, David,D.	(1962)	Case report of skin grafting in cow. Vet.Record, 74 : 995.
Vaughan, L.C. and Scott, M.G.A.D.	(1966)	An experimental study of the fate of autografts of whole thickness skin used to replace the anterior cruciate ligament. Vet.Record, 79 : 412.
Vrubel, J., Hejnal, J. and Hrdlicka,Z.	(1959)	The influence of chlortetracycline on the take of skin autografts. Folio. Bio. (Prague), 5 : 223. (Bio.Abst.,35: 421). Abs., 16299.
Wallace, A.B., Spreull, J.S. and Hamilton, H.A.	(1962)	The use of autogenous free full thickness skin grafts in the treatment of chronic inflammatory skin lesions in dog. Vet.Record, 74: 286.
Warren, J.M.	(1840)	Cited by Converse, J.M. (1962). Skin Surgery. by Epstein, E. 2nd Ed. pp.92. Lea & Febiger Philadelphia.
Woolsey,J.H.,Jr. and Schaffer,M.H.	(1952)	Treatment of granulating wound in horses by means of skin grafting. J.Am.Vet.Med.Assoc.,121:173.

Wolfe, J.R. (875) Cited by Padgett, E.C. (1948) Plastic and Reconstructive Surgery. 1st Ed. pp. 41. Charles C. Thomas. Publisher. Springfield. Illinois. U.S.A.

*****
***
*