Studies On
The use of different prosthetic materials In the repair of abdominal hernias In Buffalo calves

Thesis
Submitted to the
Rajendra Agricultural University
IN
partial fulfilment of the requirements
for the degree of
MASTER OF SCIENCE (VETERINARY)
1971

BY
Nata Raj Joshi
B. V. Sc. & A. H. (Pat.)
COLOMBO PLAN FELLOW FROM NEPAL.
Post-Graduate Department of Surgery
BIHAR VETERINARY COLLEGE
PATNA.

Studies On
The use of different prosthetic materials In the repair of abdominal hernias In Buffalo calves

Thesis
Submitted to the
Rajendra Agricultural University
IN
partial fulfilment of the requirements
for the degree of
MASTER OF SCIENCE (VETERINARY)
1971

6094
15.5.72.

BY
Nata Raj Joshi
B. V. Sc. & A. H., (Pat.),
COLOMBO PLAN FELLOW FROM NEPAL.
Post-Graduate Department of Surgery
BIHAR VETERINARY COLLEGE,
P A T N A.

Dr. A.A. Khan,
B.V.Sc. & A.H.,M.V.Sc.(Madras),F.R.V.A.C.(Denmark),
Professor incharge and Head,
Post-Graduate Department of Surgery,
Bihar Veterinary College,
PATNA.

PATNA

Dated, the 7th March, 1972.

I certify that this Thesis has been prepared under my supervision by Dr. Nata Raj Joshi a candidate for the degree of M.Sc.(Vet), with Surgery as Major subject, and it incorporates the results of his independent study.

A. Khan

(A.A. KHAN).

RAJENDRA AGRICULTURAL UNIVERSITY M. Sc. (VET.) THESIS 1971

ACKNOWLEDGEMENTS

I express deepest gratitude to my teacher Dr.A.A.Khan, B.V.Sc. & A.H.(Pat), M.V.Sc.(Madras), F.R.V.A.C. (Denmark), Head of the Department of Surgery and Professor incharge, Bihar Veterinary College, Patna, for keen and constant interest, inspiring genuine suggestions and invaluable guidance, throughout the course of study.

I sincerely thank Dr. R.C.P. Yadava, M. Sc., Ph.D. (Mich.,U.S.A.), Principal, Bihar Veterinary College, Patna, for providing the facilities for the study.

I am grateful to Dr. S.M.Ishaque, G.B.V.C.(Pat.), P.G. (Germany), F.R.V.C.S. (Sweden), Ex-Principal, Bihar Veterinary College, Patna for providing facilities to conduct this study during the tenure of his Principalship.

My warmest thanks are to Dr. K.B.P. Agrawal, B.V.Sc. & A.H., M.V.Sc. and Dr. P.N.Sahay, B.V.Sc. & A.H. (Pat.) and M.V.Sc. (Previous Year), Assistant Lecturers and the staffs of the Department of Surgery for their invaluable help.

Special thanks are due to Dr. Lalan Prasad Singh and Dr. Jagannath Prasad for their assistance in Histopathological work.

Thanks are also due to the staffs of Art and Photograph Section for their cooperation and help.

I am greatly thankful to my colleagues Dr. Damodar

Prasad Singh, Dr. Prabhat Kumar Samanta and Dr. M.N. Nassimi for their utmost cooperation and help throughout the work.

Special gratitudes go to my parents under whose kind shelter I could carry out my study smoothly.

I am sincerely thankful to my Government and Government of India for awarding Fellowship for higher studies.

Last but not the least I express my sincere feelings to my wife Smt. Ram Badan Joshi for her patience, endurance and constant encouragement to complete this study.

N.R. Joshi

(N.R. JOSHI)

RAJENDRA AGRICULTURAL UNIVERSITY M. Sc. (VET.) THESIS 1971

C O N T E N T S

CHAPTER		PAGE
I	INTRODUCTION.	1- 3
II	REVIEW OF LITERATURE.	4-24
III	MATERIALS AND METHODS.	25-35
IV	OBSERVATION AND RESULTS... ...	36-45
V	DISCUSSION.	46-54
VI	SUMMARY AND CONCLUSION.... ...	55-56
VII	REFERENCES.	57-70
	Number of Tables.	2
	Number of Graphs.	3
	Number of Photographs	

*****
***
*

RAJENDRA AGRICULTURAL UNIVERSITY M. Sc. (VET.) THESIS 1971

INTRODUCTION

INTRODUCTION

Farm livestocks are of a great help to agriculture. To a country like India, which is predominantly an agriculturally rich country, livestock as a whole has a great role in aiding the agriculture output of the country, however the cattle has to play even a more vital functions. A good and improved cattle is thus a boon to the country's agricultural performances and thereby contributes in making the country economically solid. A poor cattle wealth is a liabilities, a burden on the economy and an impediment in the progress of the country.

A good and healthy cattle serves as a source of milk and meat, thereby supply animal protein a most vital lacking in human nutrition. Neverthless, our agriculture is totally dependent on the cattle, as our economy still do not permit for mechanical farming.

It is unfortunate that large number of cattle heads perish every year because of various factors, several of which is due to surgical inadequacy and approach to the animal.

Among the surgical conditions met with in domestic animals, hernia is considered to be a common problem for the veterinarians. Abdominal and ventral hernias are most commonly found in all animals especially in farm animals like bovines. They are usually of traumatic origin, although congenital openings of the abdominal walls may turn into hernial rings

RAJENDRA AGRICULTURAL UNIVERSITY M. Sc. (VET.) THESIS 1971

resulting into ventral hernia. Even simple cases, sometimes, become so acute and complicated that the management of hernial repair, in order to save the life of the animal, becomes a challange to the surgeons. No-doubt, hernia can be repaired by employing various methods but among them herniorrhaphy can afford greater amount of success, where the hernia is of moderate size. But the hernioplasty has lately gained its importance in the field of veterinary surgery. Its usefulness can not be underestimated while comparing the superiority over the usual conventional method of treatment in practice. It is needless to emphasize that it has always been a hardly pressing problem both for human as well as veterinary surgeons. Even after the repair chances of recurrence cannot be ruled out completely. In cases of larger and irregular rings, the improved technique of hernioplasty in combination with different prosthetic materials may prove to be of greater value.

It is known from the earliest history that Petronius (1565) for the first time attempted the implantation of gold plating in the repair of abdominal defects. Since then materials like silver, platinum, aluminum, brass, nickel, and many other metals and alloys were used by various investigators in the field of surgery for hernial repairs. Later on, physiologically inactive metals like vitallium, tantalum and a special kind of stainless steel were used as prosthetic materials for the hernial repairs. Now, synthetic materials like nylon mesh, plastic mesh, marlex mesh, fabrics of ivalon, fortisan, orlon and dacron have been used with encouraging results in case of

RAJENDRA AGRICULTURAL UNIVERSITY M. Sc. (VET.) THESIS 1971

herniopl asty.

In cases of hernia where larger defects of the abdominal wall, traumatic avulsion of the abdominal wall, loss of substance due to infection and necrosis, resection of the abdominal wall tumours are so great that prosthetic materials are desirable for a permanent repair. Some still prefer s fascia, fascia lata or cutis grafts instead of using foreign prostheses. The use of prosthetic materials for hernial repair have not been fully investigated in India and only a few sporadic informations are available in this regard. This paucity stimulated the author to determine the possibility of their application for hernial repair and to develop a suitable technique for it.

Considering the importance of hernial repair in farm animals by employing different prosthetic materials, in which very limited works have so far been done. The present experimental plan was designed to study and evaluate the use of different prosthetic materials (synthetic) and different techniques in herniopl asty. In addition to that the clinical, gross and histopathological studies were also made in young Bos bubalis (Buffalo calves).

*****
***
*

RAJENDRA AGRICULTURAL UNIVERSITY M. Sc. (VET.) THESIS 1971

RAJENDRA AGRICULTURAL UNIVERSITY M. Sc. (VET.) THESIS 1971

REVIEW OF LITERATURE.

RAJENDRA AGRICULTURAL UNIVERSITY M. Sc. (VET.) THESIS 1971

REVIEW OF LITERATURE

Different authors have different views regarding hernia. Frank (1939) defined that " a hernia is formed by the passage of some of the abdominal organs through a natural or artificial opening in the abdominal wall to form a swelling covered by skin and usually peritoneum."

Broadly speaking, hernias are of two types reducible and irreducible. But according to their location they are named as umbilical, inguinal, scrotal, ventral, perineal, diaphragmatic hernias and so on. Among them ventral abdominal types are most commonly met with in our farm animals. Ventral abdominal hernias other than scrotal or inguinal hernias usually result from trauma.

To treat ventral abdominal hernias, a variety of surgical procedures have been developed to appose the edges of the hernial ring, permitting healing and closure. Where a particularly large hernial ring exists, the results of surgery are often disappointing because prolapses, due to excessive pressure on the abdominal wall and tearing out of sutures usually occur.

1 Now, it is considered that the use of alloplastic material reduces tension and consequent tearing, cutting, or splitting of the suture region resulting from abdominal pressure during and after the operation. Success with alloplasty is not dependent on the size of the hernial orifices. Many investi-

-gators have reported successful surgical repairs in farm animals using alloplasty.

Materials made of metals and synthetic for sutures or prosthetic use have found wide application in reconstructive surgery.

HERNIOPLASTY:

The term ' hernioplasty ' means the repair of hernia by reconstructing the abdominal wall. But it, sometimes, so happened recurrence may occur after repair of hernia. Surgeons should always think to prevent such accidents. As time and knowledge increased, so the methods of hernial repairs improved. Man eventually discovered metals, synthetic materials and almost immediately employed them to the old problem of hernia repairs.

Metallic meshes of tantalum and stainless steel wire have been quite popular, but objections have been raised to their use because of the fragmentation of the wire mesh that occurs within two to three months following implantation.

Synthetic fabrics of ivalon, fortisan, nylon, orlon and dacron have been used, but all have been shown to be intolerant to infection, resulting in slough of the graft.

Fabrics of teflon, marlex (new high density polythylene) have also been tried experimentally in dogs.

RAJENDRA AGRICULTURAL UNIVERSITY M. Sc. (VET.) THESIS 1971

METALS:

Petronius (1565) attempted the implantation of gold plate in the repair of abdominal wall defects.

Phelps (1894) credited with introduction of coiled silver wire into the field of herniorrhaphy. The coils were placed on the floor of the inguinal canal, and the layers of the abdominal wall were approximated over it.

Later Whitzel and Goepel (1900) employed ready-made metallic filigrees (silver wire mesh) in hernia repair.

Bartlett (1903) used an improved filigree for the repair of large defects in the abdominal wall.

Mc Gavin (1909) cited by Doran et al (1961) advocated the insertion of a silver wire filigree into the inguinal canal which was later adopted by Cole (1941), and Ball (1958).

Burke (1940) was the first to introduce tantalum in the field of surgery which was later followed by Carney and Burch (1942).

Throckmorton (1948), and Burnell (1954) cited by Doran et al (1961) introduced tantalum wire mesh in the repair of inguinal hernias.

Koontz (1948) employed tantalum wire gauze on four experimental dogs and reported months after the operation that the hernial rings in each case had become completely closed by

RAJENDRA AGRICULTURAL UNIVERSITY M. Sc. (VET.) THESIS 1971

metal gauze with the tissue growing all around the meshes.

Douglas (1948) described the usefulness of tantalum gauze for the repair of large hernias. He adopted it in 32 experiments and the results obtained were accepted by Koontz.

Lamb et al (1948) repaired tissue defects with tantalum mesh in ten dogs and reported that there was better fibrous tissue infiltration in the meshes after 6 to 8 months. Furthermore they followed this technique in 24 clinical cases with satisfactory results.

Koontz (1949) further discussed his experiences with the use of tantalum mesh in the repair of large ventral hernias and reported that it was quite useful in the presence of infection, because the results obtained were satisfactory.

Mc Nearly and Glassman (1950) employed vitallium plate in hernial repairs.

Koontz and Kimberly (1950) implanted tantalum mesh and stainless steel wire mesh on experimental dogs and rabbits and studied the tissue reaction to tantalum mesh and wire. They reported that tissue reaction to tantalum mesh and steel mesh were entirely different. Tantalum mesh produced a normal fibroblastic reaction, and a soft pliable wound. Steel mesh was surrounded with dense scar tissue, which did not infiltrate the mesh, and which produced a hard tumour like effect. In addition to this, they noticed that immediately upon the impla-

RAJENDRA AGRICULTURAL UNIVERSITY M. Sc. (VET.) THESIS 1971

-ntation of tantalum mesh, fibrous tissue started growing around and through the mesh. Under favourable conditions this process was complete in about 2 weeks but by that time the growth of the fibrous tissue was not profuse. It became more profuse as time passed and was very dense at the end of two months. They further reported that tantalum mesh implanted in puppies caused no contracture as the puppies grew well.

Koontz and Kimberly (1953) used tantalum and stainless steel gauze in hernial repair and compared the tissue reactions. They noticed good fibrous tissue infiltration in the tantalum gauze.

Koontz and Coxe (1953) implanted tantalum gauze in pups and studied its tolerance. They found that the puppies grew well without any contracture.

Douglas (1953) presented the late results of the repair of 36 cases of large or recurrent hernias with tantalum mesh and concluded that the mesh was of little value in inguinal hernia but may be used with confidence in large incisional and paraumbilical hernias.

Lattimore and Koontz (1954) reported that after implantation of tantalum gauze sheet for the repair of hernia, it was necessary to fit suction drainage in order to evacuate the serum, accumulated in the wound after operation. This serum can be drained out either by aspiration or by implanting a indwelling catheter, thereby the wounds were kept completely

RAJENDRA AGRICULTURAL UNIVERSITY M. Sc. (VET.) THESIS 1971

dry. Such drainage method produces satisfactory results in the acceptance of the implant and helps in hernia repairs.

Whitcomb (1955) reported the successful use of a tantalum mesh for the repair of abdominal hernias in the horse and cow.

Haas et al (1958) recomended the use of stainless steel ring chain net (Goepel) to cover and reinforce the defective and atrophic fascia in operations of large recurrent and long standing hernias of the abdominal wall. They reported five cases of large hernias of the anterior abdominal wall in which the Goepel stainless steel ring chain net was implanted over atrophic and defective deep fascia in the repair of massive hernia of the abdominal wall.

Koontz and Kimberly (1959) further employed tantalum mesh as prosthesis for hernia repair and reported that tantalum, though a metal,did not produce any trouble in the presence of infection. They proved that tantalum gauze was an ideal prosthesis although it had few minor disadvantages, however, in spite of its good qualities, in that occasionally it might break and protrude through the skin.

SYNTHETIC MATERIALS:

Handley (1918) cited by Doran et al (1961) darned the posterior wall of the inguinal canal with silk. Later Abel and Hunt (1948) did the same with stainless steel wire.

RAJENDRA AGRICULTURAL UNIVERSITY M. Sc. (VET.) THESIS 1971

Acquativa and Bourret (1944) for the first time employed nylon in hernia repairs.

Moloney et al (1948) used nylon as a darning material to repair various kinds of herniae, particularly direct and indirect inguinal herniae, both simple and strangulated. They found that it had given general satisfaction, especially in strangulated herniae.

Thompson (1948) described a new method of curing inguinal hernia using plastic inerts of polyethylene instead of the silver filigree wires. This operation was based on Mc Gavin's (1909).

Stretton (1948) employed a hand made silk net for the repair of tissue defects.

Yeager and Cowley (1948) in their study of cellophane as fibrous tissue stimulant suggested that cellophane and cellophane polythene (polyethylene) was possibly useful in the treatment of large herniae.

Since 1948 at the Barbados General Hospital, Teacock and Rowley had followed up the standard method of monofilament nylon darn in the inguinal hernia repairs after Moloney et al.

Grindley and Clagett (1949) described the experimental use of larger block of polyvinyl sponge which were placed in the hemithorak following pneumonectomy in dogs.

RAJENDRA AGRICULTURAL UNIVERSITY M. Sc. (VET.) THESIS 1971

Testa (1951) repaired the experimentally created abdominal wall defects by using nylon and later on he corrected musculo facial defects in nine rabbits with a wide mesh monofilament nylon which was found to produce only a mechanical tissue reaction.

Aghina (1951) described the use of nylon in 30 cases of hernia repairs which followed upto two years.

Morriston et al (1951) used polythene pack, 17 out of 102 had to removed on account of sepsis and effusion. Polythene was certainly more irritant and was incapable of absorbing any of the tissue fluid, unlike polyvinyl alcohol sponge.

Narat and Khedroo (1952) created bilateral musculo fascial defects, with or without excision of the underlying peritoneum in the abdominal wall of ten dogs. The defects were bridged on one side with Fortisan cloth, a biologically inert brand of regenerated cellulose, and on the other side with tantalum mesh or with stainless steel mesh.

Biopsies, autopsies and histologic examinations showed that Fortisan fabric served as efficient trellis for the growth of connective tissue and that, as far as tolerance by tissue was concerned, it compared favourably with tantalum mesh and was superior to stainless steel mesh.

They concluded that Fortisan cloth was useful in

RAJENDRA AGRICULTURAL UNIVERSITY M. Sc. (VET.) THESIS 1971

surgical reconstruction of large hernias or large defects of the abdominal wall because of the ease of handling, economic consideration and avoidance of certain complications which occasionally follow the employment of tantalum mesh.

Moraes and Ribiro (1953) used whole skin grafts in the treatment of primary or recurrent hernia for eventration of the abdominal wall in 103 cases and concluded that whole skin grafting gives the best results in hernia and eventration of the abdominal wall.

Koger (1954) found that polyethylene sponge was an ideal prosthesis in perineal hernia repair owing to its non-irritating, non-absorbable qualities. It could be cut and shaped to fit in any cavity and readily sterilized. Neither it supported bacterial growth nor was decomposed by bacteria and molds.

Schofield (1954, 1955) reported the use of polyvinyl sponge as a prosthesis in the repair of large hernia and found that it was a suitable foreign body prosthesis for strengthening the repair of larger defects of the abdominal wall. The material expanded well enough with better elasticity and fair amount of tissue infiltration.

Schofield et al (1954) first tested the efficacy of polyvinyl sponge in hernia repair in animals. They obtained successful repair in the experimentally produced defects in the abdominal wall of dogs and rabbits. The tests of tensile

RAJENDRA AGRICULTURAL UNIVERSITY M. Sc. (VET.) THESIS 1971

strength were also carried out to asses the strength of the repaired tissue.

Stock (1954) pointed out the successful use of a nylon mesh in ten cases of hernia, one with a ventral hernia, and one after excision of a large area of internal oblique and transversus abdominis muscles for a cellular fibroma.

Koontz and Kimberly (1954) employed fortisan fabric as prosthesis in hernia repair in dogs and found to be satisfactory.

Sen and Kothare (1954) studied the tissue reaction of cellophane implanted in the inguinal canal and anterior abdominal wall of rabbits. They noticed progressive and localised fibrosis around the cellophane without much inflammation. Controls of implanted silk suture showed less fibrosis and much infiltration and inflammation. They suggested that cellophane strips was useful in hernia repair as reinforcement around the silk or linen sutures which were used routinely, to promote dense localised fibrosis, mimicking the effect.

Noon (1954) used anterior rectus sheath flap in the repair of inguinal hernias (134 cases) and reported that this method was used in all cases in which the anterior rectus sheath was of sufficiently good material.

Melick, cited by Moore and Siderny (1955) found that nylon produced less tissue reaction than any of the other

RAJENDRA AGRICULTURAL UNIVERSITY M. SC. (VET.) THESIS 1971

suture materials tested. He also discovered that the monofilament nylon was tolerated better than the multifilament variety.

Moore and Siderny (1955) used two types of plastic grafts, out of which the first was one layer fine mesh nylon, and the second a three layers impervious sheet of fused nylon and polyethylene for the repair of abdominal wall defect in dogs. The impervious nylon polyethylene graft appeared to be unsuitable due to excessive tissue reaction with fluid accumulation and the high incidence of suture line disruption. On the other hand, the single layer fine mesh nylon graft was tolerated quite well. There was no fluid accumulation and no adverse tissue reaction to the graft. In addition, there was a high degree of suture line stability. The strength and pliability of the nylon graft, with its fine mesh and small filament, seemed to provide a maximum security of repair with a minimum risk of damage to adjacent structure.

Blakely (1955) described the use of sponges in the repair of perineal hernia. He found that the results were excellent.

Wion (1957) stated that closure of the hernial ring with steel wire mattress sutures was not completely satisfactory because wire did not possess the elasticity needed to minimize tearing of the tissue. So, he used nylon thread, which had sufficient tensile strength, instead of wire in closing the hernial ring with mattress sutures to appose the edges as close

RAJENDRA AGRICULTURAL UNIVERSITY M. Sc. (VET.) THESIS 1971

as possible. The results obtained were satisfactory.

Harrison (1957) used two types of teflon weaves TF-41-30 and TF-204 in the repair of abdominal wall defects. Tantalum wire was used as a control. He found that there was good healing with all materials in the clean and fresh wound. Although open weave of teflon (TF-41-30) proved superior over other teflon weaves and tantalum on account of its more pliability and maintaining its strength over a longer period of time. The teflon prostheses had good functional support in the abdomen and diaphragm.

Horwich (1958) repaired the defects of the inguinal canal with pieces of nylon.

Adler and Firme (1957, 1959) employed nylon mesh alone as prosthesis for the repiar of diaphragmatic defects and further they used nylon mesh with interlocked fibre juncture, knitted nylon mesh, dermalon nylon mesh and a woven mesh prepared from teflon (synthetic plastic) in the repair of hernias and tissue defects. They reported that the knitted plastic mesh with interlocked fibre junctures function satisfactorily when properly employed.

Higgins and Orr (1958) described about the use of grafts in the repair of inguinal hernia. They cited that grafts of hernial sac, cutis, tantalum wire mesh or other foreign materials were used to reinforce the repair of inguinal hernias.

Usher et al (1958, 1959) injected pellets of the

polypropylene mesh (marlex mesh) into the abdominal cavity of dogs and studied its reaction to the tissue. Later, they used the mesh in abdominal wall defects. They, also, conducted infection studies in dogs by injecting a diluted fecal solution into the surgical wound immediately after the mesh implantation, and found that the dogs, survived with the infection, showed the mesh was not rejected by the tissue. At necropsy, macroscopic and microscopic examination of both infected and noninfected dogs revealed minimal tissue reaction with the polypropylene mesh.

Brock (1959) agreed with Blakely's technique of perineal hernial repair which was greately enhanced by the use of V-drape i.e. the plastic sheeting that adhered to the surgical site. Mesh patches of flexible Mersiline (Ethicon) also added satisfactory strength in this type of hernia repair.

Usher (1959) studied experimentally the use of marlex mesh in dogs and found that the mesh was infiltrated with a thin, pliable layer of fibrous tissue when used to replace defects of the abdominal wall, chest wall and diaphragm. Wound that had been purposely infected in dogs in which the marlex mesh had been employed healed by secondary intention. Marlex mesh had been used to repair tissue defects in fifty nine clinical cases with no recurrence to date.

Koontz and Kimberly (1959) studied experimentally and te-sted the value of the following materials in order to determine their usefulness as prostheses in the repair of

RAJENDRA AGRICULTURAL UNIVERSITY M. Sc. (VET.) THESIS 1971

abdominal defects. They used dacron fabric, dacron and nylon cloth, fibre glass, mylar, fortisan thread, nylon mesh, orlon cloth, orlon thread, polyethylene, polyvinyl sponge, woven stainless steel mesh, teflon fabric, teflon and nylon cloth, vinyon-N cloth, marlex mesh as prostheses and concluded that in the absence of infection, orlon cloth showed the most promising result than any of the plastic materials used. It was better infiltrated with fibroblasts and gave a stronger end result than the rest of the materials. Although there were good fibroblasts infiltration in the dacron fibric, fibre glass and nylon mesh yet the end results were not so strong as in the case of orlon cloth.

The use of loosely woven stainless steel mesh resulted in a very weak abdominal wall repair.

None of the materials except the loosely woven steel mesh could with stand infection, and in the case of infection implanted material was found floating in an abscess cavity in periods of varying from 2 to 32 weeks at the site of implantation. The stainless steel caused no trouble in presence of infection.

The search for a non-metallic suture material which would not give trouble in the presence of infection led to the experiment with fortisan thread and orlon thread. Both of these gave just as much trouble in the presence of infection as did silk. It should be pointed out, however, that occasionally good healing without infection occurs when most of these

RAJENDRA AGRICULTURAL UNIVERSITY M. Sc. (VET.) THESIS 1971

materials were used, even in the presence of gross contamination.

Stapp (1960) utilized the plastic screen in umbilical hernioplasty and found that the plastic screen was excellent material as it affords immediate strength. He recommended both in calves and colts for its application. The plastic screen produced desired result without any recurrence of hernia.

Koontz and Kimberly (1960) proved that marlex was useful in the repair of artificially made defects in the abdominal wall of dogs. There was excellent infiltration of the mesh with fibroblasts, but not quite as much infiltration as in the case of tantalum. The closure was, therefore, not quite as strong as closure with tantalum.

They stated that neither marlex mesh nor marlex thread cause trouble in the presence of infection, as have all other plastic which were tried.

Doran et al (1961) reported that 313 inguinal herniae were repaired with nylon nets. They used three types of net (thin, thick and medium) and concluded that the medium (hand made) nylon net proved to be useful in the repair of inguinal herniae though the nylon was an inert substance which did not damage the living tissue owing to a noxious chemical interaction.

Usher (1961) adopted a new technique for repairing large abdominal wall defects by implanting two layers of mesh instead of single layer mesh and stated that this technique

RAJENDRA AGRICULTURAL UNIVERSITY M. Sc. (VET.) THESIS 1971

offered the best chance to success in repairing large abdominal wall defects in which tension did not permit repair with the tissues at hand.

Adler et al (1962) developed a new prosthesis made of collagen fibres of beaf tendon. This new prosthesis had been found to be stronger than synthetic dacron mesh because it was easily absorbed by 80 to 120 days.

Wintzer (1962) implanted nylon 6-polymer mesh in 184 cattle in the repair of umbilical or ventral hernias over the course of almost five years and got satisfactory results in 177 cases. Out of 7 unsuccessful cases, 2 failures were due to the result of partial loosing of the mesh, a few days after the operation. The other five failures were the result of massive wound infection accompanied by acute or chronic peritonitis which necessitated eventual slaughter.

Usher (1962) reported 541 hernias repaired with marlex mesh and pointed out that marlex mesh was useful in the repair of large and difficult hernias.

Johnson (1963) reported the repair of umbilical hernia in horse with sliding fascial flaps. In this fascial flap method the fascia of the abdominal tunic was used to repiar the defects and maintained the obliteration of the ring. If the defect was unusually larger and when it was felt that additional strength was needed, metallic or plastic gauze might be sutured over the repair.

Bullard and Johnson (1963) stated about the surgical correction of hernias by employing different materials and techniques. They lastly preferred and emphasized the use of metallic or plastic gauze over the repair where the hernial ring was unusually large, and the additional strength was needed.

Numans and Wintzer (1964) implanted three types of net (mersilene, nylon and polyamide fibre i.e. perlon) in 299 abdominal hernias in animals and found extensive fibroblast proliferation through the mersilene mesh than the nylon and polyamide mesh. They concluded that mersilene was found to be best of the three implanted materials.

Collin (1965) used interwoven polyethylene mesh for the repair of three cases of inguinal hernia in canine. The results were encouraging as the mesh did not cause any discomfort to the patient.

According to Ellett and Archibald (1965) many types of prosthetic materials were used to facilitate closure and to provide more support to weak or incomplete muscle in hernial repairs. Fascia, skin, metal wire and plastic wire mesh are the examples. But among these materials metal wire mesh and plastic mesh were the two most widely used prosthetic devices for the repair of hernias in animals, because these materials cause minimal tissue reaction and provide adequate strength.

Vayre and Petil (1965) used a leaf of the aponeurotic port ion of the rectus muscle of the abdomen in the surgical

RAJENDRA AGRICULTURAL UNIVERSITY M.Sc. (VET.) THESIS 1971

repair of direct inguinal hernia in men. Here the authors w used cloth as prosthesis to cover the base of the area on the rectus muscle left by reflection of the fascial leaf medially.

Elias et al (1965) reported their experiences with knitted marlex mesh in the repair of difficult ventral hernias in 20 clinical cases over the period of 5 years. They found that marlex is the material of choice in the repair of large defects, in which primary closure cannot be accomplished owing to its permanent strength, ine-rtness and resistance to infection.

Watson and MacInnis (1966) employed polyvinyl alcohol foam preserved in 0.5 percent formaldehyde solution for hernia repair in a 12 hours old foal and found to be quite useful in hernia repair.

Larsen (1966) reported the successful application of plastic mesh for the surgical repair of perineal hernia in 14 dogs.

Berge and Westhues (1966) closed the hernial ring by means of a nylon net where the hernial orifices were unusually large. The internal hernial sac was dissected and inverted and the trimmed net was then embedded over the ring. Finally anchored, under the moderate tension with nylon thread, to the external rectus sheath.

Thoust et al (1967) reported three cases of diaphragmatic hernia in bovines. Out of three cases one was successfully

corrected. A paramedian incision was performed and the diaphragmatic defect was repaired by suturing nylon mesh over the defect.

Schmitt and Grinnan (1967) described the use of marlex mesh (polypropylene) to replace large tissue defects in already infected or contaminated abdominal war wound in man. They further stated that marlex was allowed to be infiltrated with granulation tissue and covered by a split thickness skin graft.

Rives et al (1968) used dacron mesh in the surgical repair of inguinal hernia in 65 clinical cases. They reported that dacron was well tolerated and its use as a socalled reinforcement patch was indicated in patients where there exist large inguinal hernias as well as having poor tissue or in patients with fascial and easily torn tissues in those the conventional techniques of hernial repair would not be satisfactory.

Weaver (1968) reported a clinical case of inguinal hernia in the ewe in which nylon mesh was successfully used to close the defect immediately exterior to the peritoneum. The mesh was sutured to the edge of the ring using braided nylon and was buried with no. 1 chromic catgut in two layers. He found that nylon mesh was good to close the small hernial ring because it does not produce reaction during the process of hernia repair.

Johnson (1969) surgically implanted the polypropylene

RAJENDRA AGRICULTURAL UNIVERSITY M. Sc. (VET.) THESIS 1971

teffeta weave knitted mesh (marlex mesh) in the abdominal wall of ponies to repair the tissue defects and evaluated it. He reported that the mesh, which responded well to surgical manipulation and implantation, became incorporated in the tissue with minimal foreign body reaction. All skin incisions healed by first intension. Grossly, the abdominal wall at the implant site was slightly thickened on a cross section.

Philip (1970), cited by Tadkod (1971) conducted his experiments in 47 experimental dogs regarding repair of hernia by different techniques using different prosthetic materials. He reported that regarding techniques, overlapping body wall t-echnique was the ideal method for anatomic closure. For herniopiasty marlex mesh among the synthetic materials, autologous dermis graft among the biological implants and stainless mesh among the metals proved to be better. Comparing different repair techniques of herniopiasty he found better results in reinforcement and inlay graft techniques with artificial materials and in onlay graft wit h biological implants. He further reported that plastic and celluloid sheet, autologous whole skin and heterologous fascial sheet grafts were not suitable for herniopiasty.

Tadkod (1971) implanted cotton, silk, terylene cloth, polyethylene mesh and nylon net in the abdominal wall of experimental calves and studied the tissue response produced by these materials. He observed cotton and silk caused severe inflammatory reaction and was followed by infect ion or extensive fibrosis. The rest three materials produced lesser reaction but

RAJENDRA AGRICULTURAL UNIVERSITY M. Sc. (VET.) THESIS 1971

were tolerated. Then he created hernia in 20 experimental calves at different sites on the abdomen and employed terylene cloth, polyethylene mesh and nylon net as prostheses for hernial repairs by three different techniques. He observed that polyethylene was suitable for prosthetic material because chance of infection with polyethylene was less compared with nylon and terylene cloth and reinforcement technique was better in herniopLasty in bovines than onlay and inlay graft techniques.

*****
***
*

MATERIALS AND METHODS

RAJENDRA AGRICULTURAL UNIVERSITY M. Sc. (VET.) THESIS 1977

MATERIALS AND METHODS

Selection of animals :

Fifteen apparently healthy male buffalo calves aged about one or one and half years old, weighing about 100 lbs. to 150 lbs. were selected in this present experiment. These animals were divided intoa three groups.

All the selected animals were kept in indoor wards under personal keen observation. They were kept mainly on green grasses and paddy straw supplemented with frequent grazing. They were maintained till 16th, 24th, and 32nd days after reduction.

Suture materials and prostheses :

Braided silk thread No. 3 (Ethicon) and vetafil medium 0.3 mm. were the two sutures used for suturing in this present experiment. Fine nylon net, plastic net and vetafil medium 0.3 mm. were selected and used as prostheses in the surgical repair of ventral abdominal hernias.

Design of the experiment :

The buffalo calves were divided at random in three groups consisting of six in Group I, five in Group II, and four in Group III.

Three different techniques (onlay graft, inlay graft and reinforcement graft) were used to conduct this experiment.

Group I : In the first group of animals fine nylon net was used as prosthesis.

Group II : In the second group plastic net was implanted as prosthesis.

Group III : In the last and third group ventral abdominal hernias were repaired by using vetafil dawn.

Site of herniation :

Hernias were produced in experimental buffalo calves at four different sites. Mid ventral, paramedian, paracostal and lower flank were the choice of site for creating hernia. Right side was preferred better than the left side.

METHODS

A. Clinical examination :

Before proceeding with the final operation, all the buffalo calves were clinically examined to ensure that they were free from diseases.

Recording body temperature, pulse, and respirations:

Temperature, pulse, and respirations were daily recorded morning and evening.

Haematological studies:

Appraisement of the blood constituents (haemoglobin

RAJENDRA AGRICULTURAL UNIVERSITY M. SC. (VET.) THESIS 1977

percentage, total R. B. C. and W. B. C. count and differential count of W. B. C.) was carried to rule out anaemia as well as any blood borne parasite. No abnormalities were detected (Table - 1).

B. Preparation a day prior to operation :

Fasting of the animal :

Food was withheld for 24 hours prior to operation. Water was allowed to drink adlib.

Preparation of the site of herniation :

The hairs were clipped with scissors and saved with razor. The site was scrubbed well with soap and water, then dried with sterile towel and again sterilized with savlon (ICI) lotion, sponged, dried and finally swabbed with spiritus Mercurochrome one percent and bandaged.

C. Preparation on the operation day :

The operation was conducted in the morning to get maximum time for observation during the rest of the day.

Preparation of the animal :

The temperature, pulse and respirations of the animal were taken. Prior to operation the shaved area was thoroughly scrubbed with soap and water, sponged, dried and finally swabbed with one percent spiritus Mercurochrome.

RAJENDRA AGRICULTURAL UNIVERSITY M. Sc. (VET.) THESIS 1977

Sterilization :

The instruments and appliances required for operation like drapes, towel, gauzes, vetafil, silk thread and other necessary things were autoclaved under 15 lbs. pressure for 30 minutes. B.P. blade was sterilized with detol lotion.

Anaesthesia :

The animals (buffalo calves) were narcotised with chloral hydrate crystal diluted in mucilage water (4 grams per 5 0 kg. body weight) as drench. The local anaesthesia was induced by infiltrating 2 percent sevicaine (Glaxo) in the line of incision.

Positioning of the animals :

The animals were laid in the lateral recumbent position.

Technique for experimental production of hernias :

The sites mentioned for herniation were prepared by thorough application of one percent spiritus mercurochrome. Careful asepsis was observed throughout the procedure. About 12 cm. to 18 cm. long incision was made and the skin was reflected. Thus the external obliques abdominis muscle was exposed adequetly from the underlying tissue by blunt dissection. The hernial opening was created by tearing the abdominal muscles and the parietal peritoneum with the aid of artery forceps and a pair of scissors or with the fingers.

RAJENDRA AGRICULTURAL UNIVERSITY M.Sc. (VET.) THESIS 1971

Bleeding points were checked with forci-pressure and mopped off. The large bleeding vessels were ligated with silk thread. The edges of the abdominal muscles were retracted with Allis forceps to explose the peritoneum. Thereafter, the peritoneum was grasped with tissue forceps and nicked with scalpel. Through the nick the blunt pointed blade of scissors was inserted with a finger of the other hand beneath it to prevent injury of the underlying viscera and the peritoneal incision was completed. The peritoneum was also retracted along with the muscles with the Allis forceps and the abdominal cavity was exposed. The fat filled omentum was visible covering the intestines and other visceral organs. The skin incision was closed by vertical mattr-ess suture using vetafil or braided silk thread placed 1.5 cm. apart. The suture line was cleaned and a sterile piece of rectangular gauze was fixed by stay suture. Herniation was revealed as soon as the animals gained their feet.

Pronapen (Pfizer) 10 lacs was given intramuscularly daily for 5 days. The suture line was cleaned with 70 percent absolute alcohol, dried and terramycin ointment (Pfizer) was applied daily till the wound healed up.

The animals were kept on observation for eight to ten days. The hernial swelling appeared larger at the mid ventral and paramedian regions than the lower flank and paracostal regions. Four hernias at the paracostal site, five at the lower flank site, three at the paramedian site, and three at the

RAJENDRA AGRICULTURAL UNIVERSITY M. Sc. (VET.) THESIS 1971

midventral site were produced, adopting the above described procedure.

Synthetic materials were used as prostheses for the repair of experimentally produced hernias by three different methods.

(i) Fine nylon thread net was implanted in six buffalo calves. One out of six was implanted by inlay graft technique, two by reinforcement technique and three by onlay graft technique.

(ii) Plastic thread net was embedded in five animals. One out of five buffalo calves was embedded by reinforcement technique, two by inlay graft technique, and two by onlay graft technique.

(iii) In the rest four animals the hernias were repaired by using vetafil darn as prosthesis. Only one technique i.e. reinforcement was applied in this group.

P R O C E D U R E :

Preparation of the prosthetic materials :

The prosthetic materials were washed with soap and water, then in running tap water and dried. They were rolled in surgical gauze and autoclaved under 15 lbs. pressure for 30 minutes.

Preparation of the animals, anaesthesia and restraint

RAJENDRA AGRICULTURAL UNIVERSITY M. Sc. (VET.) THESIS 1971

were carried out by the same method as applied during herniation.

Surgical technique :

The animals were placed in the left lateral recumbency after adequately preparing the site for aseptic surgery. With all aseptic precautions an elliptical skin incision about 15 cm. to 18 cm. in length including the old suture line was made over the hernial swelling cutting through the skin and subcutis. To permit adequate exposure, the incision was enlarged. All adhesions formed between the skin and hernial sac were broken down by blunt dissection with the fingers. Some of the strong adhesions were cut and bleeding points were controlled by haemostats. The hernial contents were carefully and gently reduced into the abdominal cavity by manual pressure. The hernial ring was exposed more by further retracting the undermined skin and was closed with prosthetic materials by three different techniques separately.

Three different techniques of closing hernial ring with prosthesis :

(a) Reinforcement technique :

The prosthetic material to be embedded was cut 1 to 1½ cm. longer than the hernial ring with its border rounded off. After freshening the edges, the hernial ring was closed using interrupted mattress suture of vetafil or braided silk thread No.3. Sections of mesh or vetafil darn were used as implants. Vetafil or

braided silk suture was used to hold the mesh in position and to close the incision in all animals.

(b) Inlay graft technique:

After carefully reducing the hernial contents, the prosthesis, prepared a bit bigger than the hernial ring, was placed inside the abdominal cavity under the parietal peritoneum & positioned to conform with the outline of the abdominal opening. The sutures, attached to the four corners of the prosthesis, were then fixed. The suture needle, attached to one of the free end of the suture, was inserted into the abdominal cavity through the peritoneum and out through the abdominal wall. The other free end was fixed in the same manner and the ends were tied making a mattress suture including the prosthesis and abdominal wall. The lateral sutures were then placed and fied.

(c) Onlay graft techniques

After completely replacing the hernial contents inside the abdominal cavity, the prosthesis, prepared 1 to 1½ cm. larger than the hernial orifice with rounded off border, was implanted over the hernial ring. Same suture technique was applied to fix the prosthesis as in inlay graft technique.

In all the experiments, the skin wound was apposed with a row of vertical mattress sutures using braided silk thread or vetafil. After cleaning the skin, the suture line was painted with terramycin liquid (Pfizer) and protected

the suture line with sterile gauze fixed by stay suture.

Post-operative care and management:

Recovery from anaesthesia was uneventful. All the animals except one were able to stand and walk on their feet after operation. He was narcotised a bit more than the rest. That is why, he was able to stand and walk after eight hours.

Temperature, pulse, and respirations were noted morning and evening till the 8th post-operative days.

Post-operative treatment:

All the experimental animals were given intramuscular injection of 10 lacs procaine penicillin daily for 7 days. The sutured wound was dressed with 70 percent absolute alcohol and the wound was painted with the terramycin liquid (Pfizer) till the removal of sutures. The sterile gauze was replaced if necessary. Very few animals were given intravenous injection of 5 percent dextrose solution after the 2nd post-operative day.

In two animals serous exudation from one or two stitches was observed on the 6th post-operative days. The stitches were removed and the wound was dressed daily with terramycin liquid as open wound till the wound healed up.

Removal of sutures:

The stitches were removed on the 8th and 10th post-

operative days respectively and terramycin ointment (Pfizer) was applied on the suture line for a few days.

Management and feeding :

All the experimental animalswere kept in individual stall after operation. General healthm and daily activities were also noted.

The animals were maintained on green grasses, paddy straw but occasionally feeding was supplemented with grazing.

SURGICAL PATHOLOGY

The experimental animals were sacrificed on the 16th, 24th and 32rd post-operative days respectively. A piece of tissue including prosthesis was collected from all animals and preserved in 10 percent formaline solution for gross and histopathological studies.

M E T H O D S :

Gross examination :

On postmortem every animal was thoroughly examined for adhesion and other abnormalities.

Microscopic examination:

Small pieces of tissue were cut from the preserved specimen and paraffin blocks of the tissues were prepared by a standard method. Sections were cut and the slides were stained with standard techniques (Haematoxylin and Eosin, Weigert Van Geison) and mounted. Then the slides were examined under microscope for histopathological changes.

*****
***
*

RAJENDRA AGRICULTURAL UNIVERSITY M.Sc. (VET.) THESIS 1971

OBSERVATION AND RESULTS.

OBSERVATION AND RESULTS

Fifteen buffalo calves were used for the present study. They were divided into three groups. These animals were kept on observation for 16th, 24th and 32nd days respectively after the application of prosthetic materials at the site of herniation and the results obtained during that period were studied under the following headings :

(i) Clinical changes observed from the day of operation till the date of euthanasia.

(ii) Macroscopic appearance at necropsy, and

(iii) Microscopic appearance of the tissue repair.

The clinical changes observed during hernia repair included inflammation, accumulation of serous fluid and mortality. The macroscopic observations were confined to adhesion, abscess formation and covering of implanted prosthetic materials with fibrous tissues. The microscopic examination included histopathological changes which had taken place during the time of tissue repair.

G R O U P - I.

In this group of animals fine nylon mesh was used as prosthesis by three different techniques using vetafil or braided silk thread (Ethicon) as suturing material.

BUFFALO CALF NO. 1:

During the first week following surgery, there was considerable inflammatory swelling at the implanted site. This gradually subsided, and at 10th day post-operatively there was no sign of inflammation.

The animal made un-eventful recovery. On autopsy, the implanted area showed marked fibrous tissue infiltration. The nylon mesh was fully incorporated with the tissue which practically ruled out the possibility of separating it from the grafted site. The abdominal wall at the implant site was slightly thickened on a cross-section.

BUFFALO CALF NO. 2:

Slight swelling started at the site of grafted area and lasted for a week. Post-operative collection of fluid was noticed and it was aspirated with the sterile syringe and needle for 2 days. The swelling then gradually subsided and no sign of inflammatory swelling was seen at 7th post-operative day.

The animal could recovered satisfactorily and was sacrificed on the 24th day following surgery. On postmortem examination, there was slight omental adhesion at the repaired site of hernia and there appeared a remarkable fibrous tissue infiltration at the implanted area. An uniform healing was observed in this case.

BUFFALO CALF NO. 3 :

There appeared moderate inflammatory swelling from the second post-operative day and lasted for 6 days. Serous exudate was drained out from the swelling for two sucessive days.

Recovery was uneventful without any untoward incident. The animal was destroyed on the 24th day post-operatively. Gross examination of the tissues showed that the net was sandwiched between two soft, delicate, whitish layers of fibrous tissues. The net had become incorporated in the fascia by the growth of the fibrous tissue through the openings of the net. The union being so intimate that an attempt to dissect out the net failed completely.

BUFFALO CALF NO. 4 :

Inflammatory swelling was observed after the second day of operation and continued upto 5th day, then gradually reduced in size. Seepage of serous fluid from two stitches was noticed. The stitches were removed and the wound was dressed with terramycin liquid (Pfizer) till the wound healed up completely. The animal was sacrificed on 32nd day. On gross examination, the implanted material was fully covered with fibrous tissue. No omental adhesion was found at the repaired site.

BUFFALO CALF NO. 5 :

The buffalo calf recovered without any complication except a slight post-operative swelling at the site of implantation which disappeared within a week. Periodic clinical examinations showed a strong repair of the abdominal wall and there was no evidence of herniation. Gross examination and careful dissection showed that the mesh was thoroughly infiltrated with fibrous tissue and was very difficult to remove.

BUFFALO CALF NO. 6 :

Marked inflammatory swelling was noticed which subsided subsequently within a week. Serous exudate was aspirated with a sterile syringe and needle only on second day of operation.

The buffalo calf recovered uneventfully. On post-mortem examination, the nylon mesh was well integrated into the adjacent tissues and nearly inseparable from them.

HISTOPATHOLOGICAL CHANGES :

Microscopically, the area around the mesh was marked with comparatively more vascularity. The capillaries bed and the dilated small blood vessels were seen to a much greater extent around the nylon mesh. Numerous fibroblasts along with their fibres were seen at the brim of the mesh running parallel

to each other. The fibroblast cells were more of flattened type. Leucocytic infiltration as well as appreciable number of netrophils were found at the close visinity of the mesh which showed more inflammatory processes involved in the tissues with the mesh.

G R O U P - II.

In this group of animals, the hernia was repaired by using plastic mesh as a prosthesis. Three different techniques were applied to implant the material.

BUFFALO CALF NO. 7 :

Slight inflammatory swelling was observed from the second to fourth post-operative day and thereafter it gradually subsided. The implanted plastic prosthesis could easily be palpated through the skin at the grafted site. The wound healed up satisfactorily.

The graft was examined at necropsy on 32nd day following operation. A mild tissue reaction, in the form of increased fibrosis and thickening of the tissues adjacent to the graft, was observed.

BUFFALO CALF NO. 8 :

The animal did not show any post-operative complication

except there was slight inflammatory swelling at the site of herniorrahphy. The swelling lasted for 3 days and by fifth post-operative day it became normal.

The wound healed up without any complication. On autopsy, the implanted area revealed slight thickness in comparison to the normal abdominal wall. The prosthetic material was completely covered with fibrous tissue.

BUFFALO CALF NO. 9 :

Moderate inflammatory swelling was noticed from the second day of operation. It continued upto 5th day, then subsequently subsided.

The wound healed up by first intention. On gross examination, there were only loose adhesions between omentum and implanted material. Apparently the adhesions did not interfere with the normal functions of the intestinal tract. An appreciable amount of fibrous tissue infiltration was found in the mesh.

BUFFALO CALF NO. 10 :

There developed a considerable inflammatory swelling at the site of graft during the first week after operation, then gradually subsided. Post-operative collection of fluid at the grafted site was also observed. The fluid was drained

out with sterile syringe and needle daily for 3 days. The seepage of serous exudate from one stitch was noticed. The particular stitch was removed and the wound was dressed with terramycin liquid as an open wound.

The animal was sacrificed on 32nd day after surgery. The postmortem examination showed a small cavity containing pus at the site of repair. It showed strong fibrous tissue infiltration on its edges. In comparison to the normal wall, the implanted area was thickened and the implanted material wrinkled to form ridges.

BUFFALO CALF NO. 11 :

During the first two days no inflammatory swelling was observed at the site of herniorrhaphy but it only appeared on the third day after surgery. On manipulation, it was found that the swelling contained some serous exudate and as such it was aspirated by means of sterile needle and syringe so as to avoid pressure on the suture line. Thereafter the swelling subsided and the wound healed up by the 12th post-operative day.

The animal was sacrificed and on gross examination, considerable amount of fibrosis was observed at the grafted area.

HISTOPATHOLOGICAL CHANGES:

The microscopical examination showed marked fibrosis

RAJENDRA AGRICULTURAL UNIVERSITY M.SC. (VET.) THESIS 1977

around the mesh. In the vicinity of the mesh, the fibroblast cells and their fibres were seen running almost parallel to the brim of the mesh. Histiocytes were also seen amidsts the fibroblast cells. Leucocytes were present around the mesh and they engulfed in the cytoplasm. Increased number of capillaries were also noticed though a bit away from the brim of the mesh. On the whole, all these histopathological changes were explicitly suggestive of marked inflammatory reaction around the mesh.

G R O U P - III

In this group of animals, surgically produced abdominal and ventral hernias were repaired using vetafil darn as prosthetic material. Here, only one technique was applied i.e. reinforcement technique.

BUFFALO CALF NO. 12 :

Slight inflammatory swelling was observed on the darned area on the second post-operative day. No accumulation of fluid was noticed and the swelling disappeared subsequently by 5th day following surgery. Healing of the wound took place quite satisfactorily.

On autopsy, the vetafil darns were fully covered with fibrous tissue. They formed a lattice in the tissues as a permanent shield.

BUFFALO CALF NO. 13 :

Post-operative inflammatory swelling was observed which subsided within a few days time. In this case, aspiration of serous fluid was not required. The wound healed up by first intention.

On gross examination, fibrous tissues were seen uniformly present throughout the darned area.

BUFFALO CALF NO. 14 :

In this animal, very little inflammation was observed in comparison to other animals at the site of darned area. The wound healed up satisfactorily by tenth day after surgery.

On postmortem examination, fibrous tissue infiltration was observed in and around the site of darned area.

BUFFALO CALF NO. 15 :

Inflammatory swelling was noticed from the very first day of operation and subsided within a week. A little quantity of inflammatory exudate was drained out on the 2nd and 3rd day after surgery. The wound healed up with satisfaction.

Gross examination of the darned area showed marked fibrous tissue infiltration in comparison to the above three experiments (Experiment Nos. 12, 13 and 14).

HISTOPATHOLOGICAL CHANGES:

On microscopical examination, the inflammatory reaction around the vetafil darn showed the tendency of early tissue differentiation. This was evidenced with the presence of characteristic collagenic fibres interposed between the fibroblast cells. However, the leucocytic infiltration and the parallel placement of the fibroblast and their fibres were more or less similar to those of the plastic mesh. The increased vascularity was marked with the presence of wide meshed blood vessels though a bit away from the brim of the mesh.

*****
***
*
***
*****

D I S C U S S I O N

DISCUSSION

The discussion is mainly based on clinical, gross and histopathological changes brought about by the implanted materials in case of hernial repair. The present plan was designed to study the suitability of the prosthetic materials which were used as implants in the artificially produced abdominal hernias in experimental buffalo calves and the results obtained were compared with the results of the previous workers. Several workers tried various metal wire meshes and synthetically prepared meshes like plastic, nylon, dacron fabrics, teflon, etc. for herniopiasty by different techniques and reported their findings.

In the present study, three kinds of synthetic materials were used as an implant in herniopiasty. Among the synthetic materials available in the market, fine nylon mesh, plastic mesh and vetafil (Bengen) medium 0.30 mm. were preferred.

The main aim and object of employing prosthesis for hernia repair is to check up the recurrence of hernia which generally occurs due to excessive abdominal pressure upon the sutured line, if prosthesis is not employed. In long standing cases where there is large, irregular and weak hernial ring which can not be adequately repaired by using existing tissues, the search for a satisfactory reinforcing substitute continues. It is hoped that the ideal material may be developed from one or more of the increasing number of modern synthetic materials. It is a well known fact that prosthesis gives additional support

to the defective part of the abdominal wall when properly employed and it will also reduce the tension to the particular area so that disruption of the suture may not occur.

Two things are to be considered prior to use the foreign body into the living tissue. Firstly, the foreign body, which is going to be used, must be inert and secondly, it should have stimulating power to fibrous tissue proliferation.

According to Dible (1950) cited by Doran et al (1961) the process of healing occurs in two phases; first, the physio-chemical inflammatory stage, when the irritation due to the damaged cells initiates the process of autolysis and phago-cytosis by which they are removed, the second stage is the process of repair. In an aseptic incised wound these two phases are completed in about fourteen days.

Doran et al (1961) implanted strips of the thin nylon net into the erector spinae muscles of four rabbits under aseptic surgical conditions and reported that nylon was almost inert and did not interact with living tissue. They agreed with the report of Aries, 1941; Localio and others; Blaine, 1946 who have reported that nylon produces hardly any inflamma-tory response in living tissues.

According to Johnson (1969) a material that is used in implant surgery must be inert but must produce enough irri-tation to stimulate fibroplasia. Some materials do not stimulate sufficient fibroplasia for the material to be incorporated in

the tissue. These materials are not rejected but remain encapsulated and do not strengthen the area of implantation.

He reported, plastic mesh is relatively inert and fibroblasts proliferate through the weave of the mesh fibers. The mesh is pliable and will not fragment as is the case with metals. This mesh can be cut to fit the incision at the time of surgery, and the unused mesh can be resterilized and used.

Utility of the fine nylon mesh in the repair of hernia:

From the previous reports it appears that several workers, Acquaviva and Bourret (1944), Moloney et al (1948), Testa (1951), Stock (1954), Moore and Siderys (1955), Melick (1955), Adler and Firme (1959), Wion (1957), Horwich (1958), Koontz and Kimberly (1959), Doran et al (1961), Leacock and Rowly (1962), Wintzer (1962), Numan and Wintzer (1964), Berge and Westhues (1966), Thoust et al (1967), Weaver (1968), Tadkod (1971) used nylon in the form of thread, mesh or cloth as a prosthesis or darning agents for the repair of various types of hernia in different species of animals including human beings.

The use of nylon in hernia repairs was first suggested and carried out in 1944 by Acquaviva and Bourret. They published the results of their further experiences in 1948. Lateron, other workers used nylon as sutures or prosthetic materials in reconstructive surgery. It has been shown that nylon mesh was

wholly compatible with bovine tissue.

Stock (1954), Harwich (1958), Doran et al (1961), Weaver (1968) used nylon mesh for inguinal hernia repairs, whereas Moore and Siderys (1955), Adler and Firme (1959), Konntz and Kimberly (1959), Wintzer (1962), Berge and Westhus (1966), Numan and Wintzer (1969) used the same kind of mesh for repair of ventral and abdominal hernias. They were fully satisfied with their results obtained from the nylon mesh when grafted as a prosthesis for repairing different types of hernias.

Thoust et al (1967) succeeded to repair one case of diaphragmatic defect in bovine by suturing a nylon mesh over the defect.

In the present experimental study, six apparently healthy male buffalo calves were used for determining the suitability of nylon mesh to repair the hernias. The techniques remained the same as described by Usher et al (1959) and Tadkod (1971). Out of six experiments conducted with the fine nylon mesh, five resulted quite satisfactorily without any untoward complications except post operative swelling on the implanted site. In one experiment, infection occurred due to seepage of serous exudate from two stitches. However, the animal recovered after proper treatment and care. It was the opinion of Koontz and Kimberly (1959) that nylon mesh, in the presence of infection, was entirely unreliable. This was contrary to the author's experience with the nylon mesh which

produced infection in one case but gave very encouraging results with fair amount of fibroblasts.

It was observed on gross examination of the repaired tissues that the nylon mesh was sandwiched between two soft, delicate and whitish layers of fibrous tissues. The mesh had been incorporated in the fascia by the growth of the fibrous tissues through the opennings in the mesh. The union being so intimate that the removal of mesh became very difficult.These results corroborated with the results of Moore and Siderys (1955), Adler and Firme (1959), Doran et al (1961), Wintzer (1962). Numan and Wintzer (1964), Tadkod (1971).

Utility of the plastic mesh in the Repair of hernia :

Several surgeons, Thompson (1948), Yeager and Cowley (1948), Sen and Kothare (1954), Harrison (1957), Adler and Firme (1959), Usher (1959, 1962), Koontz and Kimberly (1960), Stapp (1960), Collin (1965), Jacobs et al (1965), Larsen (1966), Schmitt and Grinnan (1967) used plastic mesh as a prosthesis in repairing hernias by applying different techniques. From their findings, plastic seems to be quite suitable for hernial repairs.

In this study, plastic mesh was implanted as prosthesis in surgically produced abdominal hernias in five experimental buffalo calves. Same techniques were adopted as in Group I.

Inflammatory swelling was observed at the grafted site in all the five experiments, which subsided subsequently within a week. Out of five experiments, two (Experiments Nos. 10 and 11) showed post-operative collection of fluid. The fluid was aspirated for one or two successive days. All skin incision healed by primary intention except in experiment No. 10, in which seepage of fluid was noticed from one stitch and healing by second intention took place without removal of prosthesis.

These animals were sacrificed between two to four and half weeks. On gross examination of a cross section of the abdominal wall, thickening at the implant site was found. In experiment No. 9 there was little adhesions between omentum and peritoneum at the site of incision. But the adhesions did not interfere with the normal function of the intestinal tract. In animal No. 10 stitch abscess was located at one of the point of the plastic mesh, which might be due to suture infection. Good amount of infiltration of the fibroblasts into the mesh was seen which prevented the easy peeling of the mesh. These results were similar to the findings of Yeager and Cowley (1948), Usher et al (1959) and Johnson (1969).

Utility of vetafil as a darning material in the repair of hernia :

Moloney et al (1948), Leacock and Rowley (1962) used nylon as a darning material to repair various kinds of herniae. It was the opinion of Moloney et al (1948) that repair of hernia

with non-absorbable material has on the whole been followed by good results. The various materials used in the past have both good and bad qualities, but the main advantage of them all is that they form a lattice which resides in the tissues as a permanent shield to a weak area. They reported that nylon has proved to be a highly satisfactory substance with which to form this lattice.

In this study, four buffalo calves were used. Vetafil was used as a darning material for the hernial repairs. Inflammatory swelling was common to all animals but not so much as in group I and II. Post operative collection of fluid was seen in one experiment (No. 15).

It was observed grossly that a lattice produced by the vetafil darn, remained in the tissue as a permanent shield.

Since, the author had seen no written reference in the literature consulted on the vetafil darn for repairing hernia. It was, therefore, thought proper to make an investigative study and to place on record the results. The author felt that the results of vetafil darn in hernia repair did not lead to any definite conclusion, because of the limited number of animals used.

Types of techniques employed in the repair of hernia:

Inlay, onlay and reinforcement were the three methods tried in this present study. Nylon mesh, plastic mesh and

vetafil were the three synthetic materials used in the prosthetic repair of hernia by the above mentioned three techniques. Among the synthetic materials, all the three were found quite suitable in the prosthetic repair of hernia. Out of fifteen experiments, abscessation developed only in one animal grafted with plastic mesh, which was seen on gross examination at the time of necropsy. Rest fourteen experiments gave quite satisfactory results.

The selection of technique is dependent upon the nature and type of hernia. From the present study, it was concluded that onlay graft and reinforcement technique were useful among the three technniques employed. Reinforcement technique was useful in all types of hernia except where the hernial ring could not be estimated due to irregularities in shape and size. It was most successful, easier to perform and associated with least complications, since this method afforded additional strength to the particular region and chances of recurrence were minimal. But, where there is irregularities in size and shape, onlay graft technique was useful. In inlay graft technique the fixation of the mesh in the defect areas was too much difficult with the possibility of visceral adhesion, whereas fixation was too easy in onlay graft in comparison to inlay graft.

HISTOPATHOLOGY OF THE HEALED TISSUE

The repaired tissue with the prosthetic materials were collected for histopathological studies. All of them showed fibrous tissues infiltration around the mesh. These findings were similar with the findings of Koontz and Kimberly (1960), Doran et al (1961), Numan and Wintzer (1964) and Johnson (1969). The area around the nylon mesh was marked with comparatively more vascularity than that of the plastic mesh. In the vicinity of the mesh the fibroblast cells and their fibres were seen running almost parallel to the brim of the mesh. Histiocytes were also seen amidst the fibroblast cells. Leucocytic infiltration and appreciable number of neutrophils were found in the close vicinity of the nylon mesh. In case of vetafil darn, the leucocytic infiltration and the parallel placement of the fibroblast and their fibres were more or less similar to those of the plastic mesh.

*****
***
*

RAJENDRA AGRICULTURAL UNIVERSITY M. Sc. (VET.) THESIS 1971

SUMMARY AND CONCLUSION.

mesh was used with a success rate of 83.3 percent.

In group II, plastic mesh was employed with a sepsis rate of 20 percent.

In group III, vetafil was employed with a cent percent satisfactory results.

Inlay, onlay and reinforcement techniques were the three methods of implantation adopted in this experiment. Among these three techniques, onlay and reinforcement were preferrable to the inlay graft technique.

Among the three synthetic materials used as prosthesis, all the three were tolerated. But nylon mesh and plastic mesh were easier to employ in comparison to vetafil darn. In vetafil darn more time and labour were required than to implant the meshes. Thus nylon and plastic mesh were the ideal prosthetic materials for herniopiasty in bovines.

*****
***
*
***
*****

TABLE - I.

Total and Differential counts and Hb. percentage of the experimental animals.

Group	Buff. calf No.	R.B.C. million/ cmm.	Hb. %	W.B.C. thousand/ cmm.	Percentage				
					Lymphocyte	Monocyte	Neutrophil	Eosinophils	Basophil
I	1	5.5	10.4	10020	67	4	26	3	Nil.
	2	5.2	11.0	10450	68	3	27	2	,,
	3	4.5	9.6	9545	70	4	25	1	,,
	4	4.9	11.6	8690	67	3	27	3	,,
	5	5.6	10.6	10030	66	4	27	2	1
	6	4.4	9.5	8564	71	4	22	3	Nil.
II	7	4.3	12.0	9578	67	3	30	Nil	Nil
	8	5.0	11.6	12338	70	5	21	4	,,
	9	6.2	8.9	9245	65	4	28	3	,,
	10	7.1	10.4	8956	72	3	21	4	,,
	11	6.5	10.3	8895	71	4	22	3	,,
III	12	5.9	11.4	9565	68	4	25	3	Nil
	13	5.4	10.8	10655	67	3	26	4	,,
	14	7.0	11.0	11678	71	4	22	3	,,
	15	7.2	10.2	12058	72	4	20	4	,,

TABLE - II

Average temperature, pulse and respiration of different groups (Pre and post operative record).

Days	Time	Group I			Group II			Group III		
		Tempera-ture	Pulse	Respi-ration	Tempe-rature	Pulse	Respi-ration	Temp-era-ture.	Pulse	Res-pira-tion.
1	M	100.4	50	12	101.2	52	13	100.8	48	11
	E	101.5	55	14	102.4	58	14	101.4	52	12
2	M	100.8	52	11	101.4	60	14	101.0	50	12
	E	102.0	55	14	102.6	59	15	102.2	56	13
3	M	101.0	54	13	102.0	60	14	102.0	55	12
	E	102.4	56	15	103.2	64	15	102.8	56	13
4	M	100.4	48	12	101.2	56	12	101.8	52	11
	E	100.8	48	11	102.2	58	13	102.6	58	12
5	M	100.2	49	10	101.2	55	12	101.0	54	11
	E	100.6	48	11	102.4	56	12	102.0	54	12
6	M	100.2	54	12	101.0	52	12	100.8	50	11
	E	100.8	56	13	102.2	54	13	101.2	56	12
7	M	101.2	50	12	100.8	52	12	100.8	54	11
	E	100.6	52	12	101.2	50	12	101.2	52	12
8	M	100.2	55	12	100.4	50	11	100.6	50	12
	E	100.6	52	12	100.8	48	12	101.2	52	12

M = Morning. E = Evening.

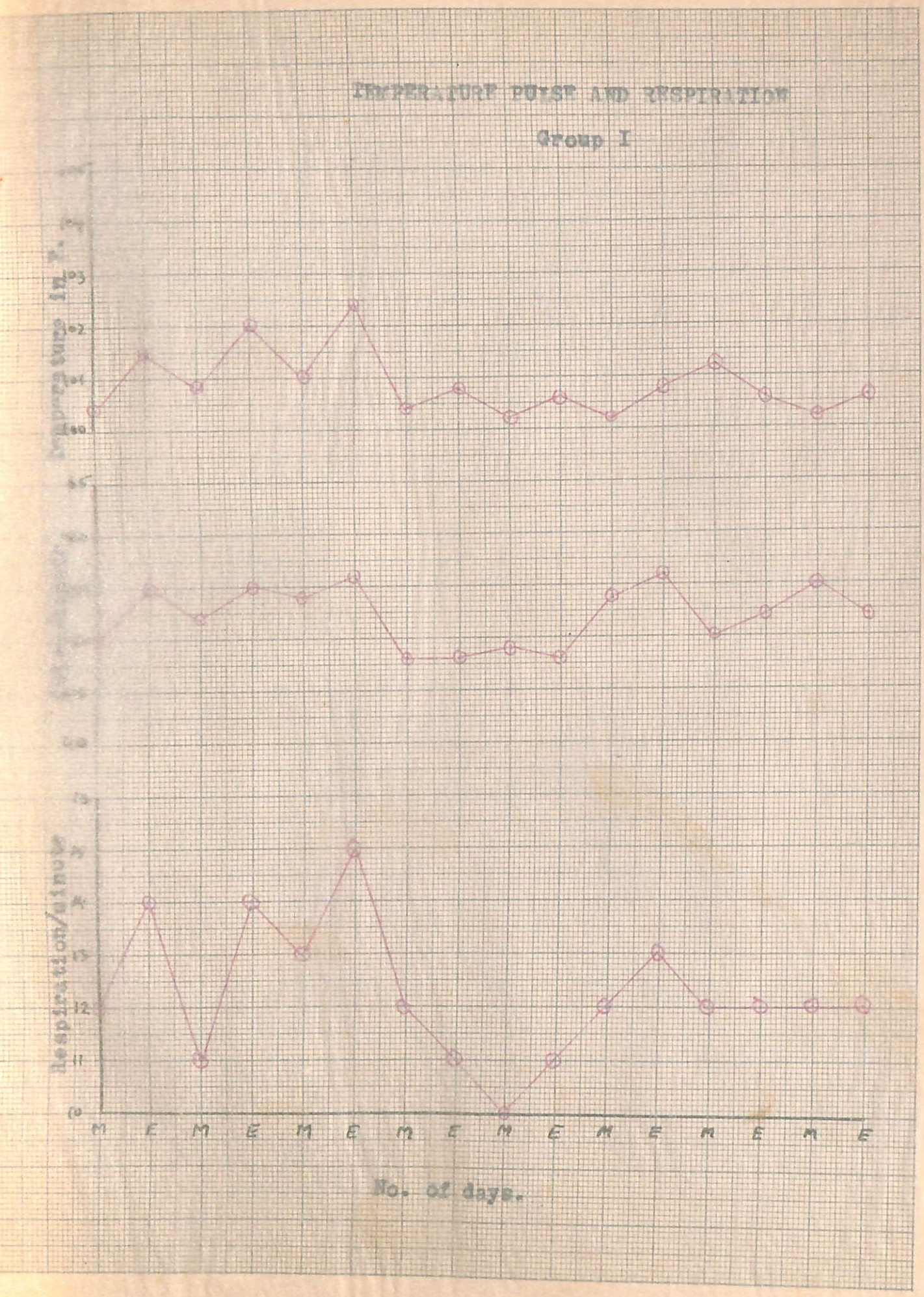
TEMPERATURE PULSE AND RESPIRATION
Group I
Temperature in F.
Respiration/minute
No. of days.

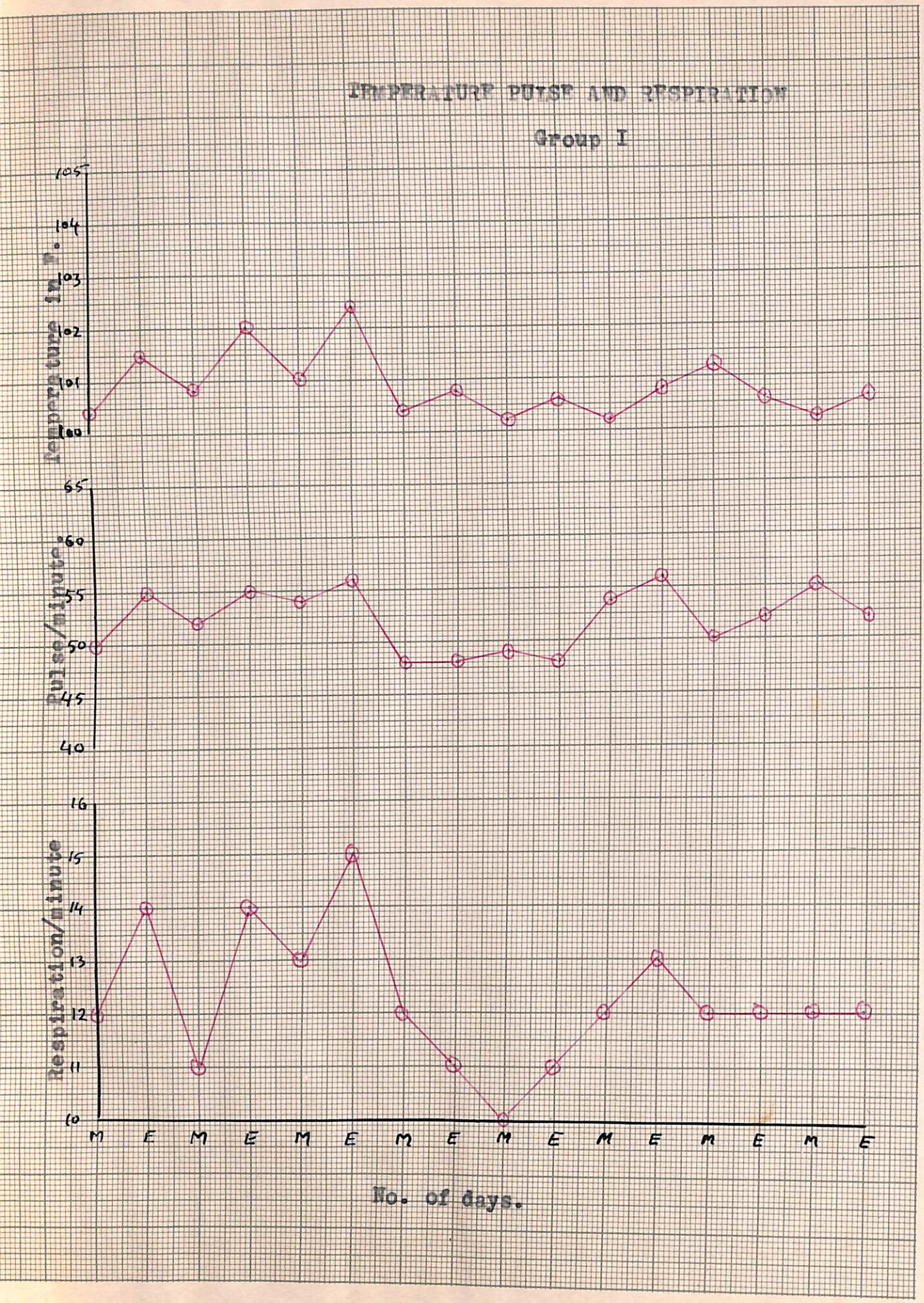
TEMPERATURE PULSE AND RESPIRATION
Group I
Temperature in F.
105
104
103
102
101
100
Pulse/minute.
65
60
55
50
45
40
Respiration/minute
16
15
14
13
12
11
10
M E M E M E M E M E M E M E M E
No. of days.

TEMPERATURE PULSE AND RESPIRATION

Group II.

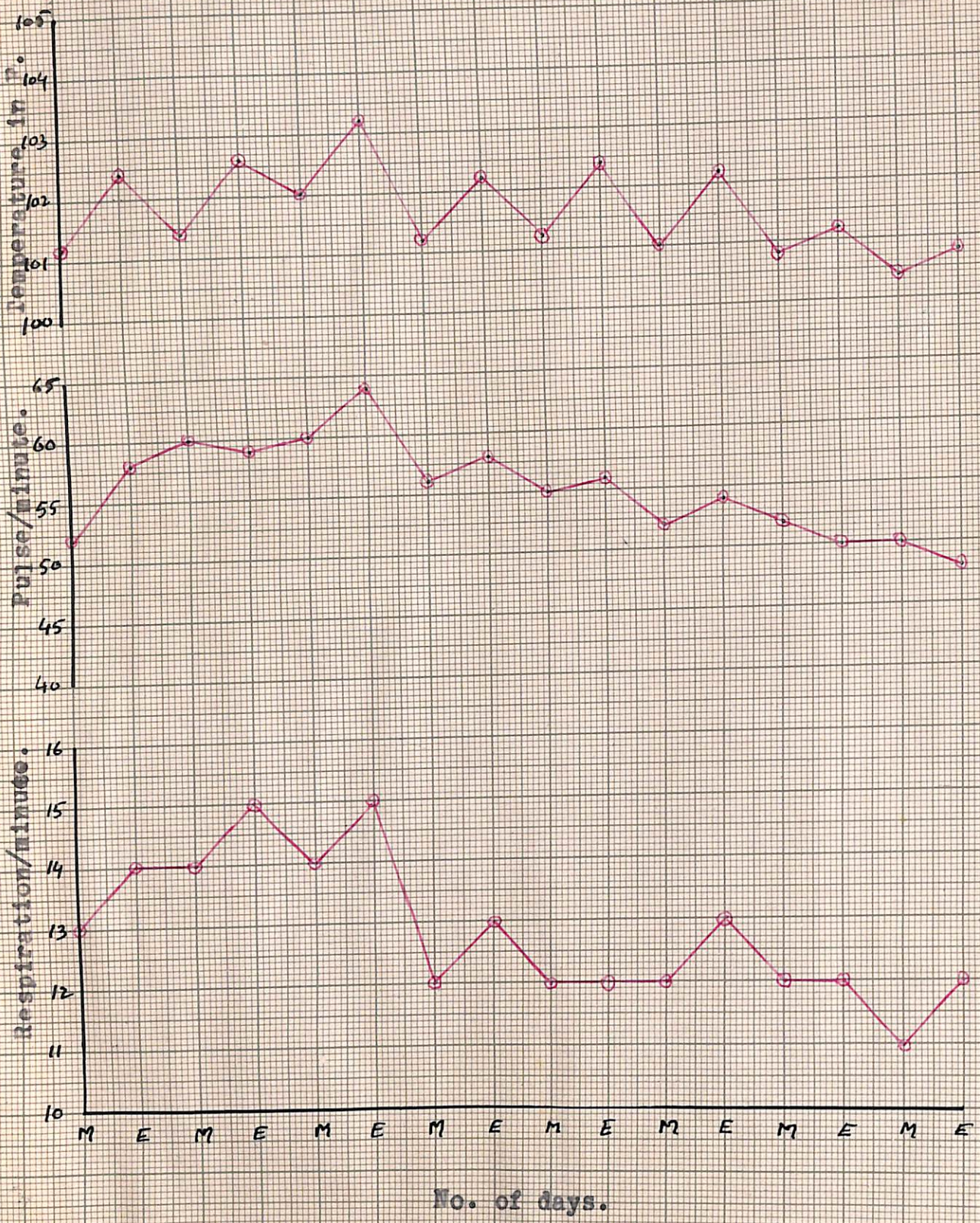

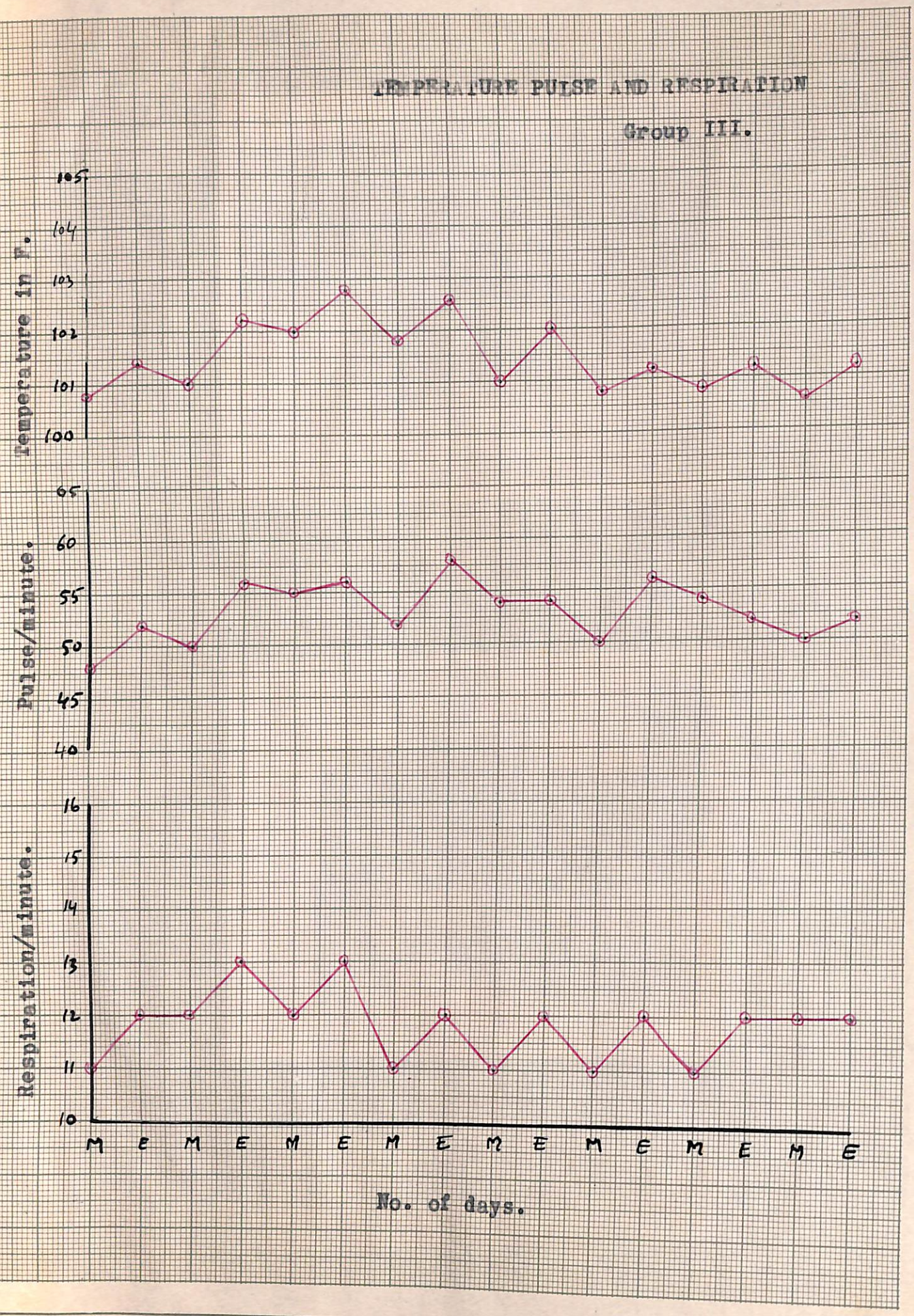
TEMPERATURE PULSE AND RESPIRATION
Group III.
Temperature in F.
105
104
103
102
101
100
Pulse/minute.
65
60
55
50
45
40
Respiration/minute.
16
15
14
13
12
11
10
M E M E M E M E M E M E M E M E
No. of days.

Fig.1

Fig.2

: Hernia created on the mid ventral site of the abdominal wall.

Fig.3

Fig.4

Hernia created on the mid ventral site of the abdominal wall.

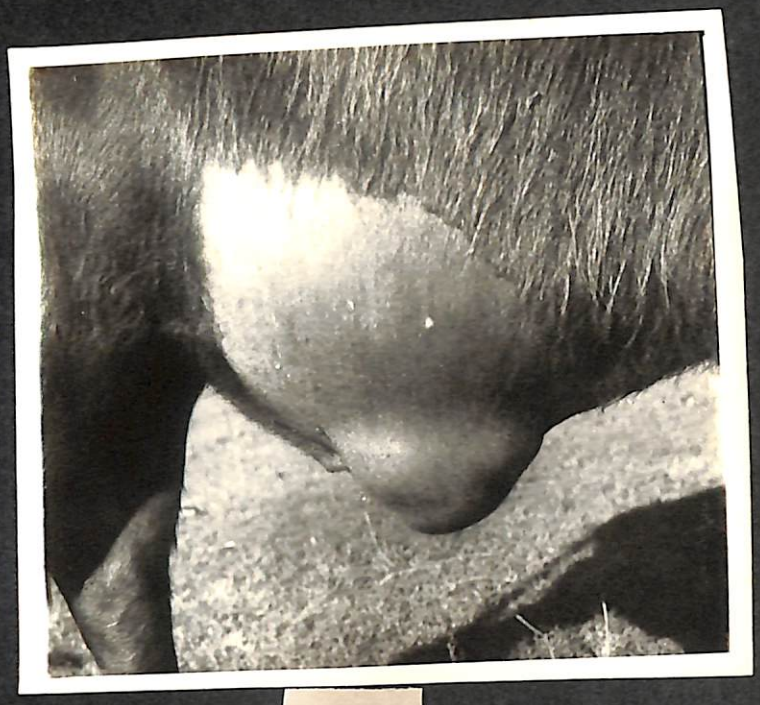

Fig.5

Fig.6

: Hernia created on the para median site of the abdominal wall.

Fig.7

Fig.8

Hernia created on the lower flank region of the abdominal wall.

Fig.9

Hernia created on the paracostal region.

Fig.10

Exposed hernial ring.

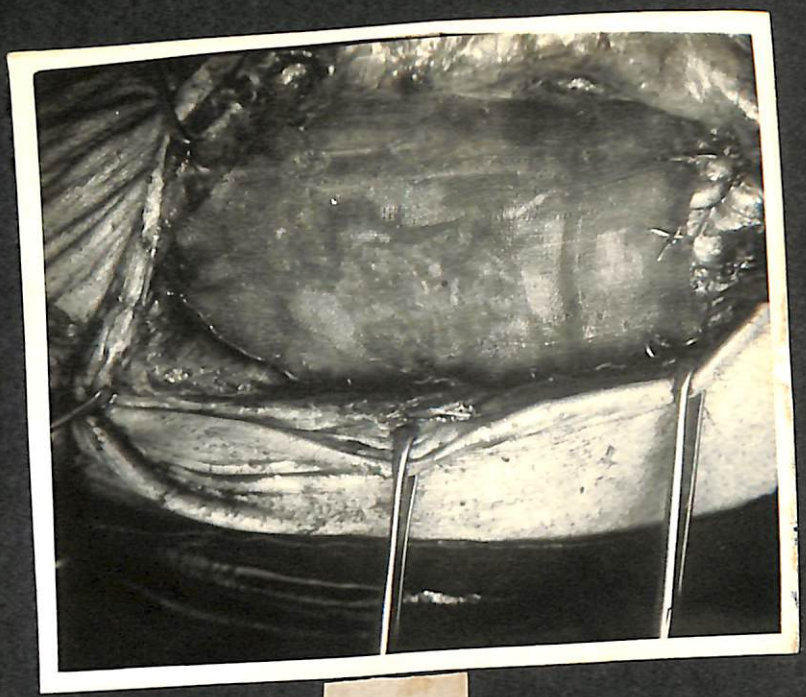

Fig.11

Photo showing nylon mesh after implantation over the hernial ring by reinforcement technique.

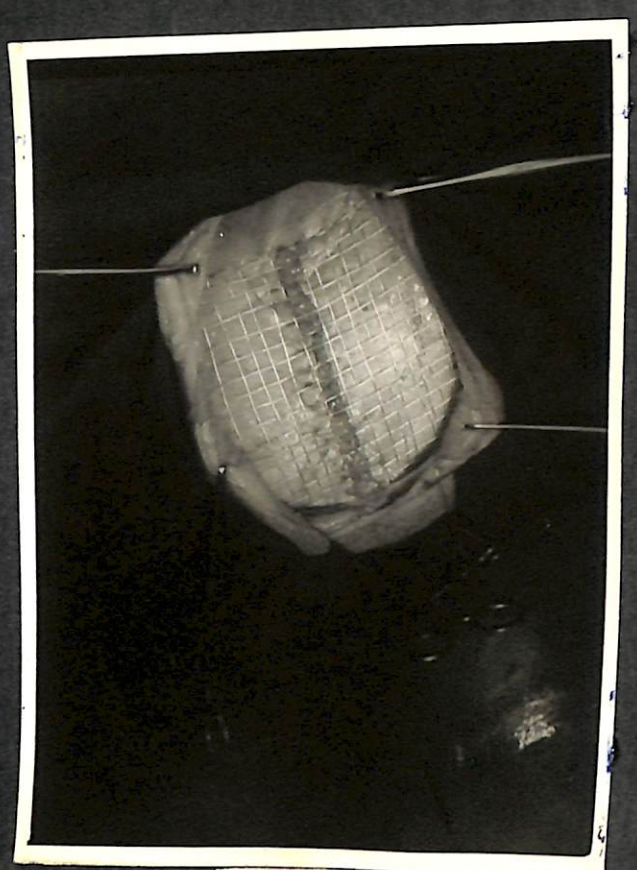

Fig.12

Method of vetafil darning over the hernial ring to provide additional support.

Fig.13

Suture line after closing the skin.

Fig.14

Suture line after closing the skin.
Skin wound closed; the drape in position.

Fig.15

Fig.16

Photo after completely recovery and removal of stitches.

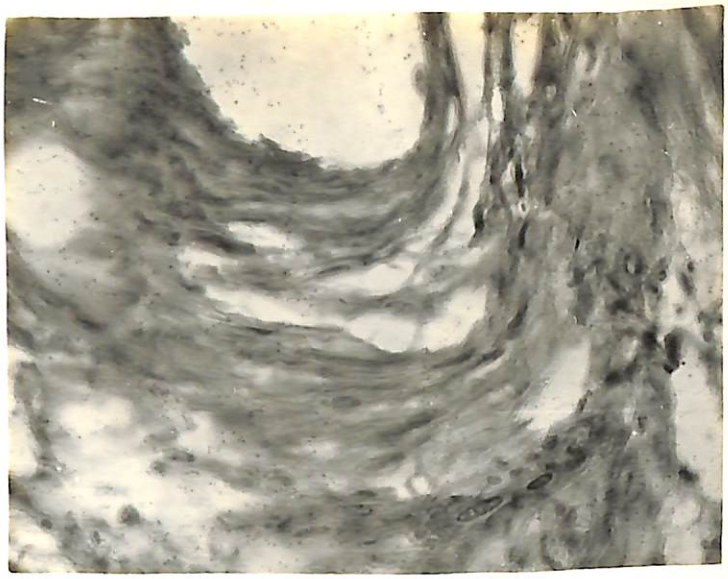

g.17

Nylon mesh :

Severe reaction around the mesh. Numerous fibroblasts along with their fibres were seen at the brim of the mesh running parallel to each other. H & E Stain; x 40.

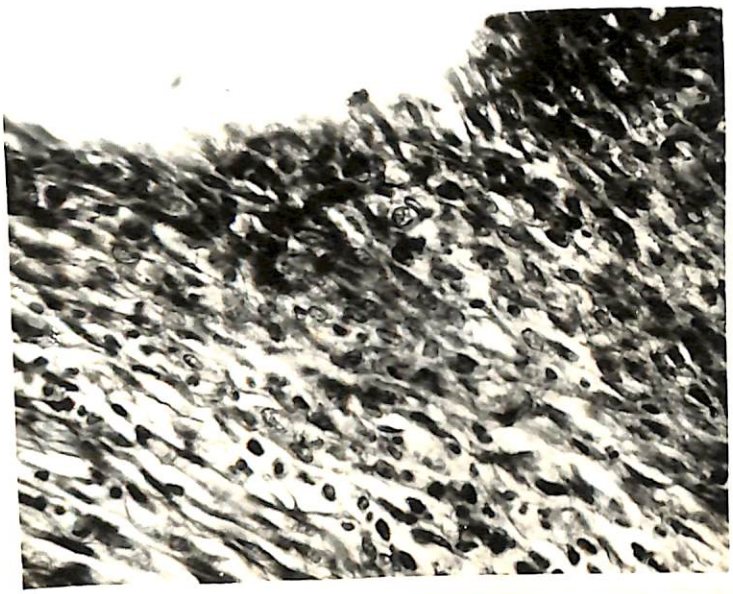

18

Plastic mesh:

Marked inflammatory reaction around the plastic mesh. In the vicinity of the mesh the fibroblast cells and their fibres were seen running almost parallel to the brim of the mesh. Histiocytes were also seen amidsts the fibroblast cells. H & E Stain; x 40.

Fig.21

Nylon mesh :

Section showing heavy leucocytic infiltration all around the meshes. Fibrous tissue are running in the direction of the mesh.
H & E Stain; x 10.

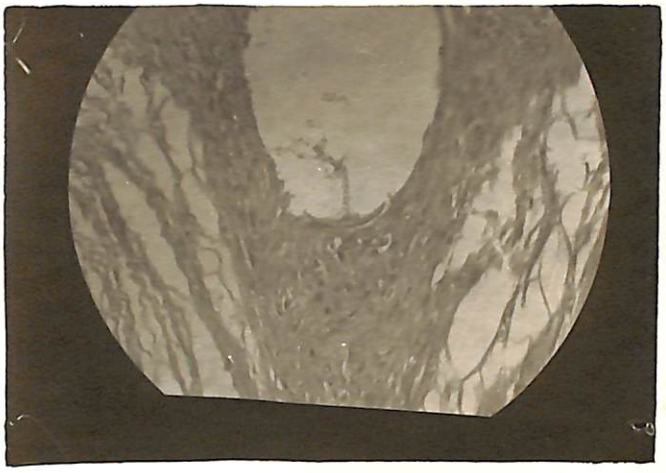

22

Nylon mesh :

ction showing a portion of the mesh surrounded
connective tissue fibres. Few leucocytes
filtration around the mesh. Blood capillaries
e also marked a bit away from the mesh.
& E Stain; x 40.

.23

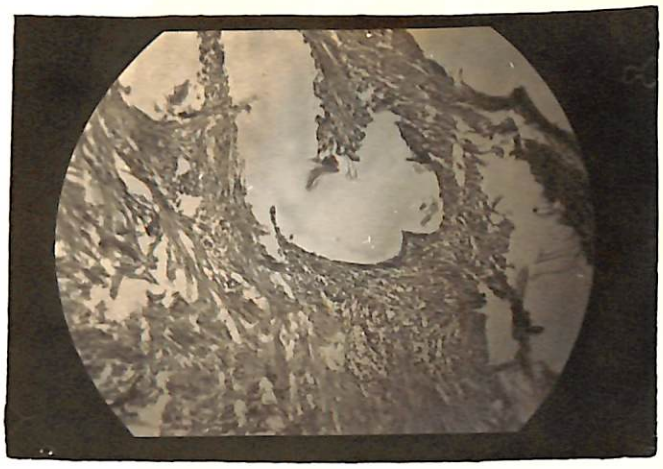

Nylon mesh :

Section showing meshes packed with large number of leucocytes around the periphery of the mesh. No blood capillaries were seen. H & E Stain; x 10.

24

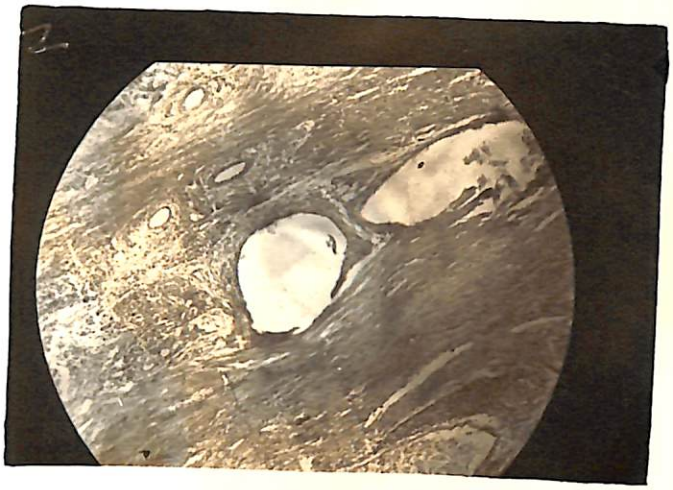

Plastic mesh :

Section showing heavy infiltration of leucocytes around the meshes and large number of blood vessels a bit away from the mesh. H & E Stain;x10.

R E F E R E N C E S.

R E F E R E N C E S

Abel, A.L. and Hunt, A.H. (1948).

A report on 313 inguinal herniae repaired with nylon nets. (Doran, F.S.A., Gibbins, R.E. and Raymond Whitehead, 1961).
Brit. J. Surg., 48 : 430-434.

Acquaviva and Bourret (1944).

The use of pliable plastics in the repair of abdominal wall defects (Thomas, C. Moore and Harry Siderys, 1955).
Ann. Surg., 142 : 973-979.

Adler, R. H. (1962).

An evaluation of surgical mesh in the repair of hernia and tissue defects.
Archives of Surgery, 85:836-844.

Adler, R.H., Pelecanos, N.T., Geil, R.G., Rosenzweig, S.E., and Throsell, H.G. (1962).

Prosthesis developed for hernia repair.
Vet. Med., (1963), 58 : 277-278.

Adler, R.H., and Firme, C.N. (1959).

Use of pliable synthetic mesh in the repair of hernias and tissue defects.
Surg., Gyne. & Obst., 108:199-206.

Aghina (1951).

The use of pliable plastics in the repair of abdominal wall defects (Thomas, C.Moore and Harry Siderys, 1955).
Ann. Surg., 142 : 973-979.

Bartlett, W. (1903).

An improved filigree for the repair of large defects in the abdominal wall (Repair of abdominal wall defects with Fortisan Fabric : Narat, J.K. and Khedroo, L.G., 1952). Ann. Surg., 136 : 272-277.

Blakely, C.L. (1955).

Songes in the repair of perineal hernia. North American Veterinarian, 36 : 55.

Brock, C. (1959).

Perineal hernia repair. Vet.Med., 54 : 613.

Burke, G.L. (1940).

Repair of abdominal wall defects with Fortisan Fabric (Narat, J.K. and Khedroo, L.G., 1952). Ann. Surg., 136 : 272-277.

Burnell, G.F. (1954).

A report on 313 inguinal herniae repaired with nylon nets (F.S.A. Doren, R.E. Gibbins and Raymond Whitehead, 1961). Brit. J. Surg., 48 : 430-434.

Carney, H.M. and Burch, J.C. (1942).

Repair of abdominal wall defects with Fortisan Fabric (Narat, J.K. and Khedroo, L.G., 1952). Ann. Surg., 136 : 272-277.

Donald R. Collins (1965).

Interwoven polyethylene mesh prosthesis in surgical repair of inguinal hernia in the dog. Vet.Med., 60 : 377-381.

Doran, F.S.A., Gibbins, R.E. and Raymond Whitehead (1961).

A report on 313 inguinal herniae repaired with nylon nets. The British Journal of Surgery, 48 : 430-434.

Douglas, D.M. (1948).

Repair of large hernias with tantalum mesh. Lancet, 1: 936.

Douglas, D.M. (1953).

The late results of repair of large hernias with tantalum mesh. Lancet, Jan. 17, 108-110.

Elias Jacobs, F. William Blaisdell and Albert D. Hall (1965).

Use of knitted marlex mesh in the repair of ventral hernias. Am. J. Surg., 110 : 897. Abst.Surg., Gyne. & Obst. (1966) Vol. 122 No. 6 : 1373.

Ewald Berge and Melchior Westhues (1965).

Veterinary operative surgery. Medical Book Company, 7 Aaboulevard. Copenhagen. Denmark, 1966.

Frank, E.R. (1955).

Veterinary Surgery.
Burgers Publishing Company,
426 South Sixth Street,
Minneapolis 15, Minn.

Goepel, R. (1900).

Repair of abdominal wall
defects with Fortisan fabric
(Narat, J.K. and Khedroo,
L.G., 1952).
Ann. Surg., 136 : 272-277.

Grindlay, J.H. and Clagett, O.T. (1949).

Polyvinyl alcohol sponge an
inert plastic for use as a pros-
thesis in the repair of large
hernias. (Schofield, T.L.,1954).
Brit. J. Surg., 42 : 618-621.

Grindlay, J.H. and Waugh, J.M. (1951).

Polyvinyl alcohol sponge an
inert plastic for use as a
prosthesis in the repair of
large hernias (Schofield,T.L.,
1954).
Brit. J. Surg., 42 : 618-621.

Haas, Alfred and Ritter, S.A. (1958).

Use of stainless steel ring
chain net for reinforcement
in the repair of large and
recurrent hernias of anterior
abdominal wall.
Am. J. Surg., 95 : 87-93.

Handley, W.S. (1918).

A report on 313 inguinal herniae
repaired with nylon nets (F.S.A.
Doran and R.E. Gibbins and Raymond
Whitehead, 1961).
Brit. J. Surg., 48 : 430-434.

Harrison, J.H. (1957).

A teflon weave for replacing tissue defects.
Surg. Gyne. & Obst., 104:584-590.

Higgins and Orr (1958).

Orr's operation of General Surgery, Third Ed., W.B.Saunders Company Philadelphia and London.

Horwich, M. (1958).

A report on 313 inguinal herniae repaired with nylon nets(F.S.A. Doran and R.E. Gibbins and Raymond Whitehead, 1961).
Brit. J. Surg., 48: 430-434.

JNO. A.W. Dollars (1912).

Regional Veterinary Surgery and operative technique.
Gay & Hancock Ltd., 12, Henrietta Street, London.

Johnson, L.E. (1963).

Hernia repairs with sliding Fascial flaps.
Modern Vet.Prac., 44: 52-53.

Johnson, L.E. and Bullard, J.F. (1963).

Hernioplasty.
Equine Medicine and Surgery 1st Ed., American Veterinary Publication, INC.

Johnson, J.H. (1969).

An evaluation of polypropylene implants in ponies.
J.Am.Vet.Med.Ass., 154: 779-785.

Koger, R.B. (1954).

Polyethylene sponge in perineal hermorrhaphy - Clinical Report. Vet. Med., 49 : 451.

Koontz, A.R. (1948).

Repair of large ventral hernias with tantalum gauze. Vet. Med., 43 : 43.

Koontz, A.R. (1948).

Preliminary report on the use of tantalum mesh in the repair of ventral hernias. Ann. Surg., 127 : 1079-1085.

Koontz, A.R. (1949).

Repair of abdominal wall defects with Fortisan fabric (Narat,J.K. and Khedroo, L.G., 1952). Ann. Surg., 136 : 272-277.

Koontz, A.R. and Kimberly, R.C. (1950).

Tissue reaction to tantalum mesh and wire. Ann. Surg., 131 : 666-686.

Koontz, A.R. and Coxe, W.S. (1953).

Effect of implanted tantalum mesh on the growth of young individuals. Ann. Surg. 137 : 77-79.

Koontz,A.R. and Kimberly, R.C. (1954).

An evaluation of the usefulness of Fortisan fabric in hernia repair. Ann. Surg., 139: 644-649.

Koontz, A.R. and Kimberly, R.C. (1959).

Further experimental work on prostheses for hernia repair.
Surg.Gyne.& Obst., 109: 321.

Koontz, A.R. and Kimberly, R.C. (1960).

Tantalum and Marlex mesh (with a note on Marlex Thread). An experimental and clinical comparison - Preliminary Report.
Ann. Surg., 151 : 796-804.

Lamb, C.R., Szizagyi, D.E. and Puppendabl, M. (1948).

Tantalum gauze in the repair of post-operative ventral hernias.
Arch. Surg., 57: 234-244.

Larsen, J. S. (1966).

Perineal herniorrhaphy in dogs.
J. Am.Vet.Med.Ass.,149:277-280.

Lattimore, T.J. and Koontz, A.R. (1954).

Suction drainage after implanting of tantalum sheets.
J.A.M.A., 155 :1333-1334.

Leacock, A.C. and Rowley, R.K. (1962).

Results of nylon repairs in inguinal hernias.
Lancet, January 6,

Mc Gavin, L. (1909).

A report on 313 inguinal herniae

repaired with nylong nets
(F.S.A.Doran, R.E.Gibbins
and Raymond Whitehead, 1961).
Brit.J.Surg., 48 : 430-434.

McNealy, R.W. and Glassman, J.A. (1950).

A report on 313 inguinal
hernia repaired with nylon
nets (F.S.A.Doran,R.E. Gibbins
and Raymond Whitehead, 1961).
Brit. J. Surg., 48 : 430-434.

Moloney, G.E., Gill, W.G. and Barclay,R.C.(1948).

operation for hernia : Technique
of nylon darn.
Lancet, 2: 45-48.

Moore, T.C. and Harry Siderys (1955).

The use of pliable plastics
in the repair of abdominal wall
defects.
Ann. Surg., 142 : 973-979.

Moraes, C.C. and Ribeiro, F. M. (1954).

Skin grafts in treatment of
hernia and eventration of
abdominal wall. Results in
103 cases.
J.A.M.A., 155 : 520.

Merriston, Davies, Temple and Stathatos (1951).

Polyvinyl alcohol sponge an
inert plastic for use as a
prosthesis in the repair of
large hernias (Schofield,
T.L., 1954).
Brit. J. Surg., 42 : 618-621.

Melick (1955)

The use of pliable plastics in the repair of abdominal wall defects (Moore, T.C. and Harry Siderys, 1955).
Ann. Surg., 142 : 973-979.

Narat, J.K. and Khedroo, L.G. (1952).

Repair of abdominal wall defects with Fortisan febric.
Ann.Surg., 136 : 272-277.

Noon, C.F. (1954).

Inguinal hernia repaired with anterior rectus sheet flap.
Lancet, July 17.

Numan, S.N. and Wintzer, H.J. (1964).

Umbilical and ventral hernia, implanted of plastic, nylon, mersilene.
Cirugia Veterinarius.

O' Connor, J.J. (1958).

Dollar's Veterinary Surgery, 5th Ed., Bailliere, Tindall and Cox, London.

Petronius (1965).

Equine medicine and surgery, 1st Ed., American Veterinary Publications, INC.

Phelps, A.M. (1894).

Repair of abdominal wall defects with Fortisan fibric (Narat, J.K. and Khedroo, L.G., 1952).
Ann. Surg., 136 : 272-277.

Philip, P.J. (1970).

Hernioplasty in ventral herniae in animals. A dissertation submitted to Mahatma Phule Krishi Vidyapeeth in Partial Fulfilment of the requirements for the Degree of M.V.Sc.

Rives, J.R., Stoppa, L.Fortesa, and H.Nicaise (1968).

The usefulness of dacron prosthesis in the surgical repair of inguinal hernia.
Abst.Surg.Gyne.& Obst.(1969), 128 : 420.

Schmitt, H.J. and George, L.B. Grinman (1967).

Use of Marlex mesh in infected abdominal war wound.
Am. J.Surg., 113 :825-828.

Schofiedd, T.L., Hallenbeck, G.A., Grindlay, J.H. and Blades, E.J. (1954).

Use of polyvinyl sponge in the repair of experimentally produced defects in the abdominal wall.
Arch.Surg., 68 : 191.

Schofield, T.L. (1954-1955).

Polyvinyl alcohol sponge an inert plastic for use as a prosthesis in the repair of large hernias.
Brit. J.Surg., 42 : 618-621.

Schilling, J.A., Faveta, B.V. and Radakovich, M. (1953).

Polyvinyl alcohol sponge an inert plastic for use as a prosthesis in the repair of large hernias (Schofield, T.L., 1954). Brit.J.Surg., 42 : 618-621.

Sen, P.K. and Kothare, S.N. (1954).

Connective tissue reaction to implanted polyethylene cellophane and its possible use in the treatment of hernia. Ind.J. Surg., 16 : 53-56.

Stapp, R.W. (1960).

Repair of umbilical hernias with plastic screen. Modern Vet. Practice, 41 : 60.

Stock, F.E. (1954).

Repair of lagge hernia with nylon mesh. Lancet - 1 : 395-396.

Stretton, J. (1948).

A report on 313 inguinal hernia repaired with nylon nets (F.S.A.Doran, R.F. Gibbin and Raymond Whitehead, 1961). Brit.J.Surg., 48 : 430-434.

Tadkod, D.M. (1971).

Studies on the utility of commonly available synthetic materials in hernioplasty in bovines. A dissertation submitted to the University of Madras in Partial Fulfilment of the requirement for the Degree of M.V.Sc.

ta (1951).

The use of pliable plastics in the report of abdominal wall defects (Moore, T.C. and Harry Siderys, 1955).
Ann. Surg., 142 : 973-979.

mpson, W. (1948).

Radical cure of inguinal hernia with a plastic inert.
Lancet - 2 : 182-183.

ust, H.F., Fessler, J.F., e, E.H. and Amstuz, H.E. (1967).

Thoracic repair of a diaphragmatic hernia in a heifer (Moor, A.De, Verschooten, F. and Desmet, P., 1969).
Vet. Record., 85 : 87-89.

ockmorten, T.D. (1948).

A report on 313 inguinal herniae repaired with nylon nets (F.S.A.Doran, R.E. Gibbins and Raymond Whitehead, 1961).
Brit. J. Surg., 48 : 430-434.

er, F.C. (1959).

A new plastic prosthesis for repairing tissue defects of the chest and abdominal.
Am.J.Surg., 97 : 629-633.

er, F.C. (1961).

A new technique for repairing large abdominal wall defects.
Arch. of Surg., 82 : 870-877.

r, F.C. (1962).

Hernia repair with Marlex mesh.
Archives of Surg., 84: 325-328.

re, P. and Palit Pazos, C. (1965).

Use of a leaf of the aponeurotic portion of the rectus muscle of the abdomen in the surgical repair of direct inguinal hernia in men.
Abst.Surg.,Gyne.& Obst.,1966, 122 : 666.

son, D.F. and MacInnis, G.A. (1966).

Polyvinyl foam for repair of hernia in a foal.
J. Am. Vet.Med.Asso.,148:410.

ver, A.D. (1968).

Inguinal hernia in the Ewe : Two case reports.
Vet. Rec., 83 : 170-171.

tcomb, O.W. (1954).

Methods for surgical treatment of bovine abdominal hernias.
(Wintzer, H.J.,1962).
J. Am. Vet.Med.Ass., 141 : 131-134.

ntzer, H. J. (1962).

Methods for surgical treatment of bovine abdominal hernias.
J.Am.Vet.Med.Ass.,141:131-134.

Wion, J. E. (1957).

Methods for surgical treatment of bovine abdominal hernias. (Wintzer, H.J., 1962). J.Am.Vet.Med.Asso, 141 : 131-134.

Witzel, O. (1900).

Repair of abdominal wall defects with Fortisan fabric (Narat, J.K. and Khedroo, L.G., 1952). Ann.Surg., 136 : 272-277.

Yeager, G.H. and Adams Cowley (1948).

Studies on the use of polythene as a Fibrous tissue stimulant. Ann. Surg., 127 :509-520.

****
*****
***
*
***
*****
****