HYSTEROSCOPY IN LARGE DOMESTIC ANIMALS

Prof Govind Narayan Purohit

Head Department of Veterinary Gynecology and Obstetrics
College of Veterinary and Animal science, RAJUVAS, Bikaner
Rajasthan

- The endoscopic technique used to view the interior of the uterus is called hysteroscopy. Hysteroscopy is used often as an adjunct technique during a breeding soundness examination in animals, and has specific applications for the diagnosis of certain conditions. It is increasingly being used for operative procedures in the uterus

History

- Even though hysteroscopy has been available since 1869 when Pantaleoni visualized and treated an endometrial polyp, it has struggled to be widely adapted as a gynecological surgical tool in medical practice. In 1970s the possibility of trans-cervical sterilizations caused the first real spurt of interest and growth among general medical gynecologists to learn hysteroscopy (Bradley and Falcon, 2009).

- Cattle: (Devine and Lindsey, 1984)
- Mares: (Leidl et al., 1987)

- Reports on the hyssteroscopic visualization of the large animal uterus are not very old (Devine and Lindsay, 1984; Metzner et al., 1992). However, the interest in use of hysteroscopy has gained popularity in equine reproductive medicine on account of easier introduction of the scope in the equine uterus and possibly the cost of the species. Thus, hysteroscopy has been used in the equine species for evaluation of normal fertile (Bracher and Allen, 1992) and sub-fertile mares (Bracher et al., 1992) identification of growths or adhesions (Berezowski, 2002; Assad and Pandey, 2015), collection of biopsies (Card et al., 2010), low dose insemination with normal (Lindsey et al., 2001; Ball, 2004) or sex selected semen (Lindsey et al., 2002a; Lindsey et al., 2002b; Lindsey et al., 2005). In cattle and buffalo however, the use has been limited to evaluation of endometritis (Madoz eet al., 2007; Madoz et al., 2010) or visualization of endometrial hemorrhages or fluid accumulations (Purohit et al., 2013; Chaudhary et al., 2014).

- **FIBEROPTIC ENDOSCOPE PRINCIPLES**
  A fiberoptic endoscope system is based on transmission of light and images through long thin fibers of optical glass. The fiberoptic image is made up of thousands of tiny fibers that are made of coated glass. The coating acts as a mirror that reflects light through the fiber into the eyepiece. The eyepiece magnifies the group of fibers into an image that one can visualize with the eye (Figure 1). The screen is actually all the fibers lined up next to one another. Each fiber displays part of the overall image.
-
  Light used to visualize your image is sent into the body cavity through light guides and then travels back up through the image guide to the eyepiece for viewing.

. Optical system of fiberoptic endoscope.



Figure 1

- The uterus is essentially an unsuitable organ for endoscopic procedures: without mechanical dilatation, the isthmus is too narrow to introduce the endoscope; the uterine cavity is virtual, i.e., the two thick and rigid walls are in proximity with a narrow space; also, the endometrium is extremely fragile

- Most commonly used modern panoramic hysteroscopes can be divided into two major types: the **rigid type** and **flexible type** of instruments, according to the method of image transmission.
- Each has advantages and disadvantages, as shown in Table 1. The basic equipment of diagnostic hysteroscopy consists of four items: the hysteroscope, a light source, a light-transmitting glass fiber cable, and a suitable recording device (still cameras and video cameras)


SAMSUNG
STORZ


SAMSUNG
STORZ

Table 1. Strong and weak points of rigid and flexible hysteroscopes

	Rigid	Flexible
Image guide	Rod lens	Optic fiber bundle
Light guide	Fiber bundle	Fiber bundle
direction of vision	Direct or oblique	Steerable
Clarity of image	Sharp and clear	Dotted, distinct
Operation of tool	Easy	Rather complicated
Focus	Fixed	Adjustable
Price of tool	Moderate	Expensive

- **The Rigid Hysteroscope**
  The hysteroscope consists of a telescope and an outer sleeve with an obturator. The hysteroscope, has an oval cross section of 4.0 x 6.3 mm, equipped with a Hopkins lens system with direct vision over a 60° visual angle and a fixed focal length of 2mm. A light transmitting cable, connecting the light source and the hysteroscope, consists of about 9000 optical glass fibers. The distal ends of the glass fibers are confined within the hysteroscope, surrounding the optic lens channel.

- There is one more thin channel, 2mm in diameter, for water rinsing to dilate the uterine cavity, connecting to the inlet valve. The valve at the neck of the telescope regulates water intake from the irrigator at a height of 50 cm. The outer sleeve, a thin-walled cylindrical pipe, is 7mm OD, and 2mm longer than the telescope.

- It plays an important role in protecting the endometrium from direct contact with the telescope as well as keeping the distal lens at a fixed distance from the objects. A gap between the telescope and the outer sleeve is used as a channel through which sterile saline or 32% dextran solution is drained after lavage and distension of the uterine cavity.

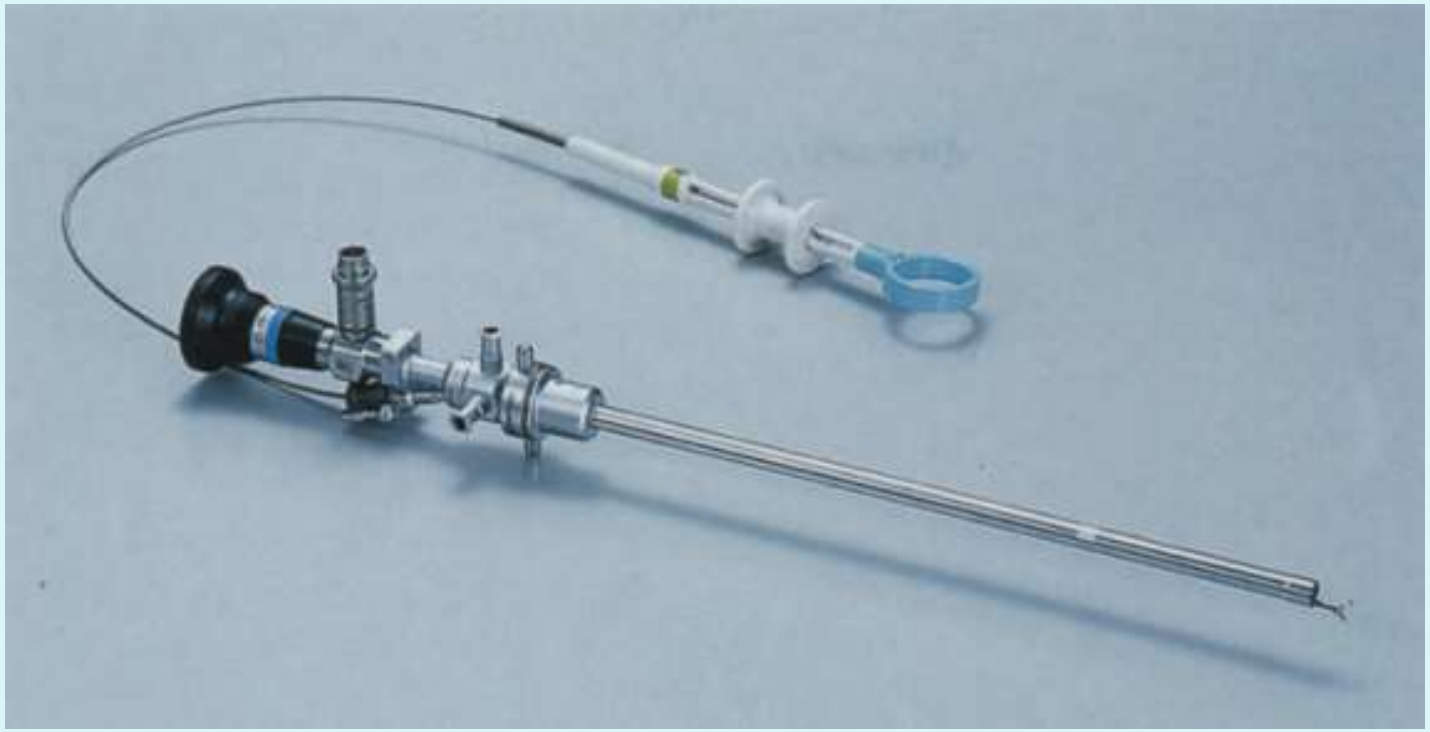

- **The Steerable Hysteroscope (Hysterofiberscope)**
- The hysterofiberscope has a 3.5-mm OD and is 540 mm in length. It is equipped with a fiber-optical system that is flexible at the distal end and steerable through a total arc of 200^0 in the horizontal plane by using a manual control. The telescope has three channels, one for image transmission, one for the light guide, and the third for water irrigation (Fig.).

- As the tool is thin and flexible, it is possible to see directly into the entire interior of the uterus.

- However, because the hysterofiberscope is not equipped with a drainage channel through the outer sleeve because of its flexibility, it is difficult to remove blood and debris masking the structures. Also, the image reflected on the fiberscope is less sharp and less clear than that on the rigid-lens-type endoscope because it is an aggregation of dotted images reflected through individual fibers.

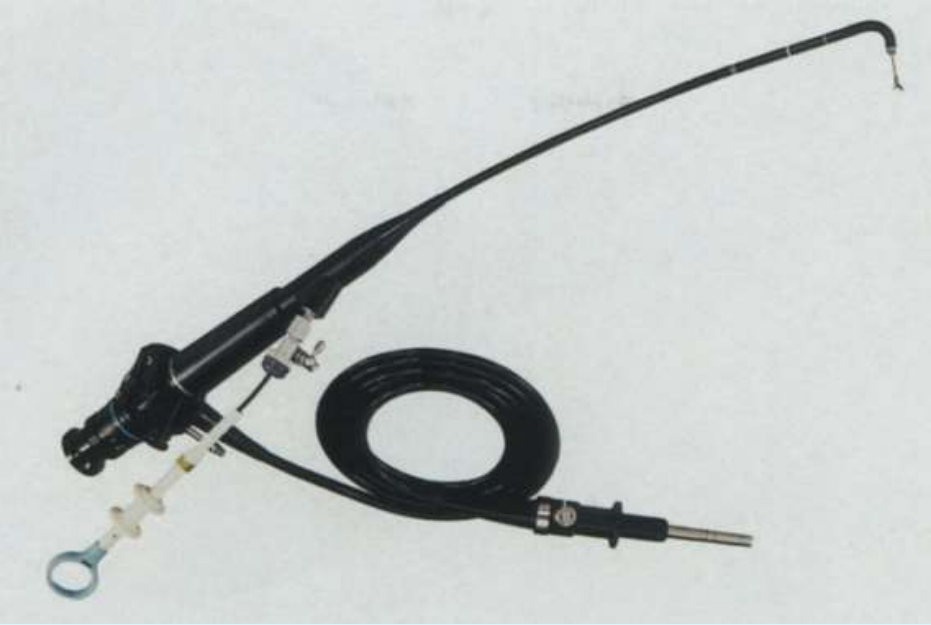


Light Guide Lens
Air / Water Nozzle
Image Guide Lens
Light Guide Lens
Biopsy Channel

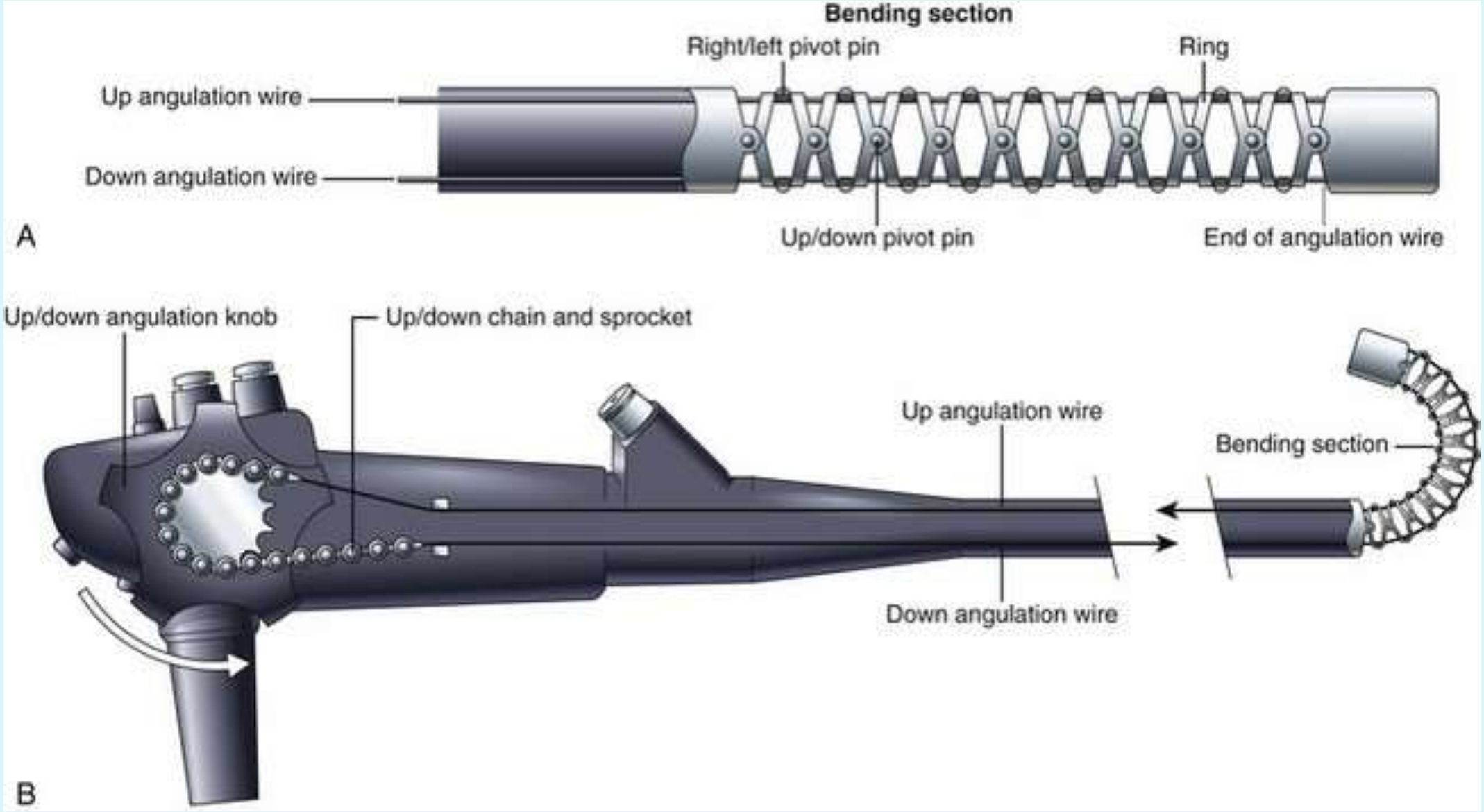
Bending section
Right/left pivot pin
Ring
Up angulation wire
Down angulation wire
A
Up/down pivot pin
End of angulation wire
Up/down angulation knob
Up/down chain and sprocket
Up angulation wire
Bending section
Down angulation wire
B

Distension Media

- To obtain a clear panoramic view of the uterine cavity, it is necessary to dilate the uterine cavity suitably with transparent media. Two kinds of media are now available for distension of the uterus, either liquid or gas. One liquid media is a physiologically isotonic solution such as saline and 5% dextrose in water, and another is a highly viscous solution such as 32% dextran in dextrose. On the other hand, CO2 has been used for gas hysteroscopy at some places.
  Sterile air insufflation has also been suggested.

Restraint and anesthesia

- Restrain in a chute or travis
- Tranquilizers are suggested for mares.
- Some sedation is also required for cows
- Perineal area should be washed and dried

Endoscopy procedure

- The uterus is distended using Ringers lactate or sterile air or CO_2 using a equine embryo flushing catheter and the cervix is sealed by inflating the bulb of catheter.
- The scope is then passed in to the uterus and the endometrium and other structures can be visualized.

Indications

- Examination of uterus
- Artificial insemination using low volume sperms
- Obtaining samples for cytology
- Operative removal of endometrial cysts, endometrial fibrous cysts

–EQUINES

- The structures of the mare’s reproductive tract that may be viewed using endoscopy include: the vagina, vestibulo-vaginal fold, cervix, uterine body: bifurcation, uterine horn, and utero-tubal papilla and ostium.

- Endometrial abnormalities observed with hysteroscopy include endometrial degeneration, endometrial cysts, intra-luminal fluid accumulation, trans-luminal adhesions, etc. (Bracher *et al.* 1992; Santschi, 2005).

- Uterine adhesions are very difficult to diagnose with procedures other than endoscopy.

- BREEDING SOUNDNESS EXAMINATION

- “Hysteroscopy is included as part of a breeding soundness exam for most mares presented for infertility at Rood & Riddle Equine Hospital,” said Etta Bradecamp. “I often get asked what percentage of the findings are abnormal, and I just have to guess.”

- So she performed a retrospective study of 108 hysteroscopic evaluations performed as part of breeding exams at the hospital between 2008 and 2015 and identified pathology (damage or disease) in 41.6% (45/108) of the cases

- . Discolored endometrial plaques, indicating fungal or bacterial growth, in 14.8% (16/108);
- Excessive and overly viscous (thick, sticky) mucus in 6.5% (7/108);
- Retained endometrial cups, in 5.5% (6/108);
- Adhesions/scarring in 3.7% (4/108);
- Excessive cesarean section scarring in 2.7% (3/108);
- Foreign debris within the uterine lumen (cavity) in 1.9% (2/108);
- Widespread fungal endometritis (inflammation of the uterus lining) in 1.9% (2/108); and
- Other causes accounted for 4.6% (5/108).

- Mares are restrained and tranquilized by iv injection of 3-5 mg detomidine hydrochloride, followed ***5*** min later by an iv injection of 7-10 mg of butorphanol (Slovis, 2004).
- Passage of filtered air allows the visualization of uterine cavity as the endoscope is passed inside.

Hysteroscopic low dose insemination at the UTJ

- Sperms- $10x10^6$ to $14x10^6$
- Volume 20 to 500 µL
- Pregnancy Rates 56-67%

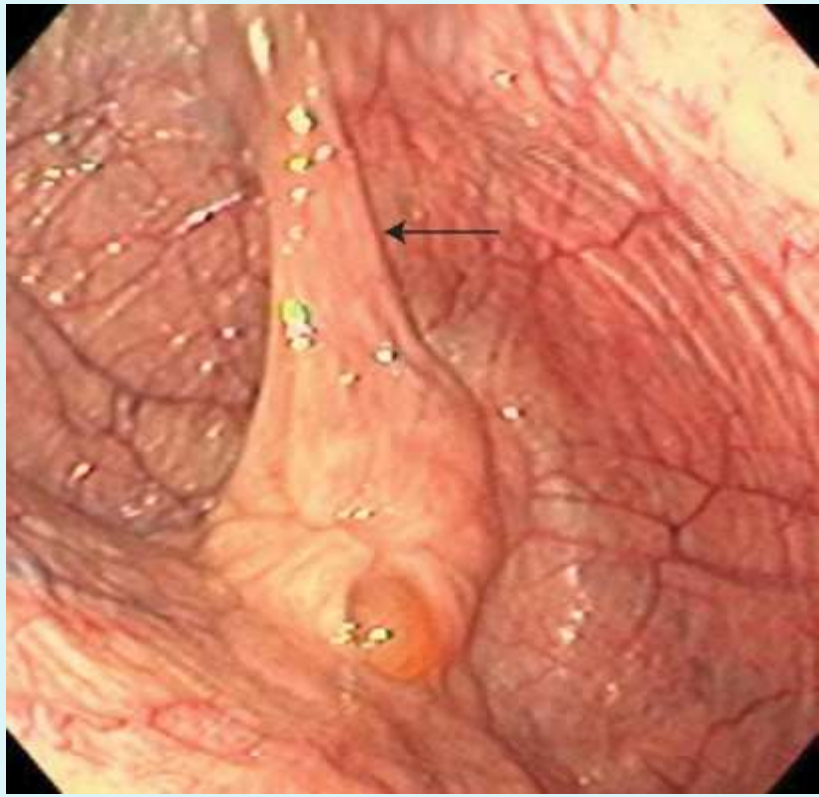




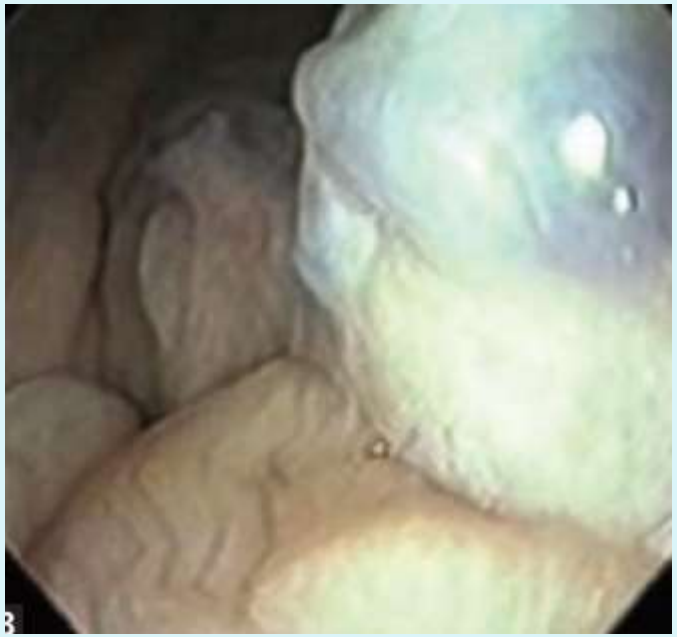
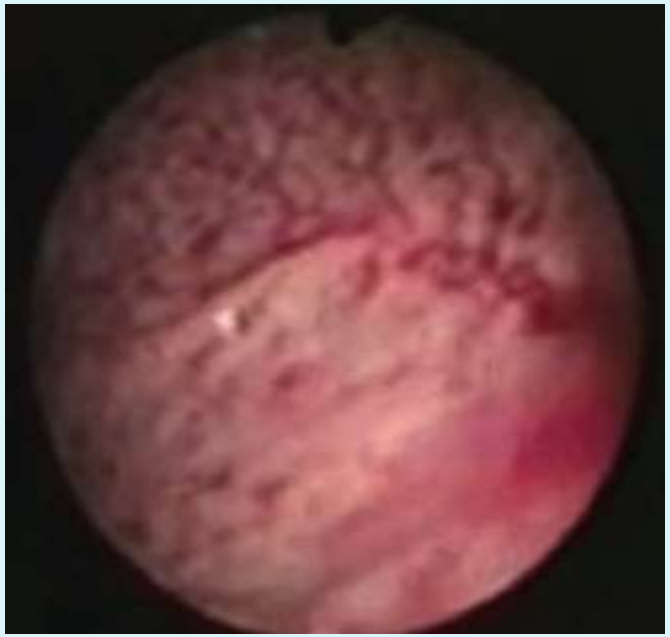


Equine

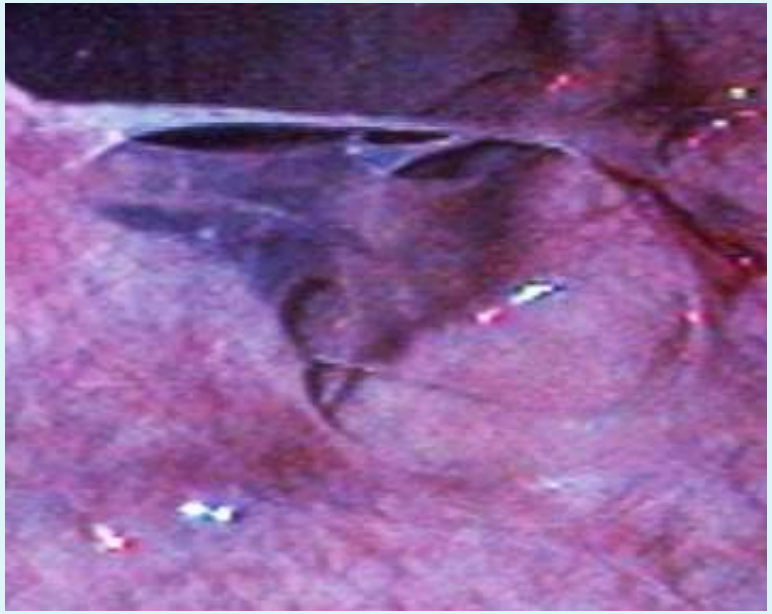

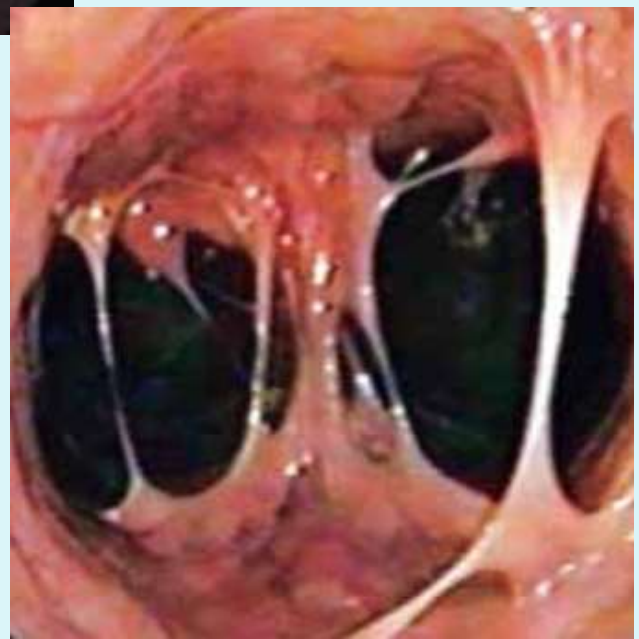

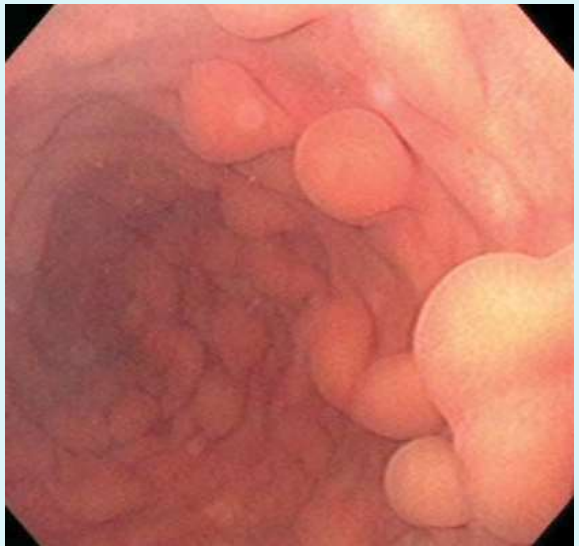

Equine

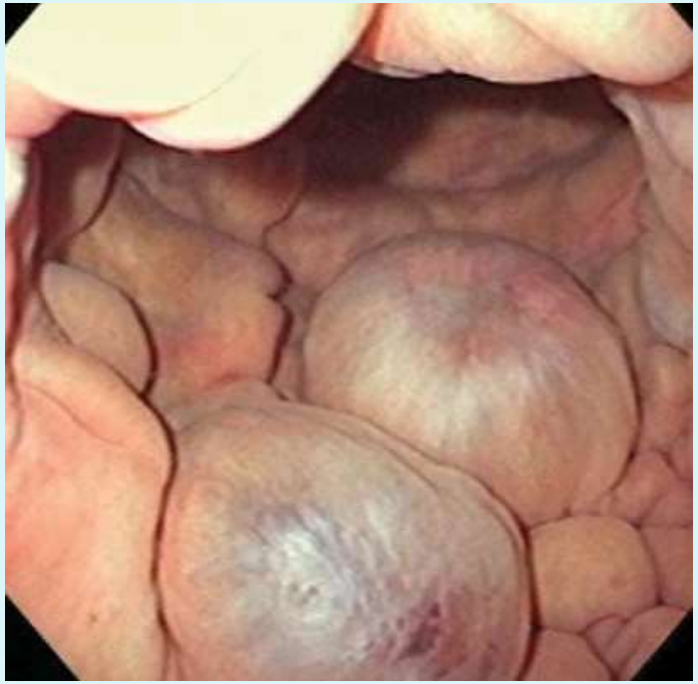

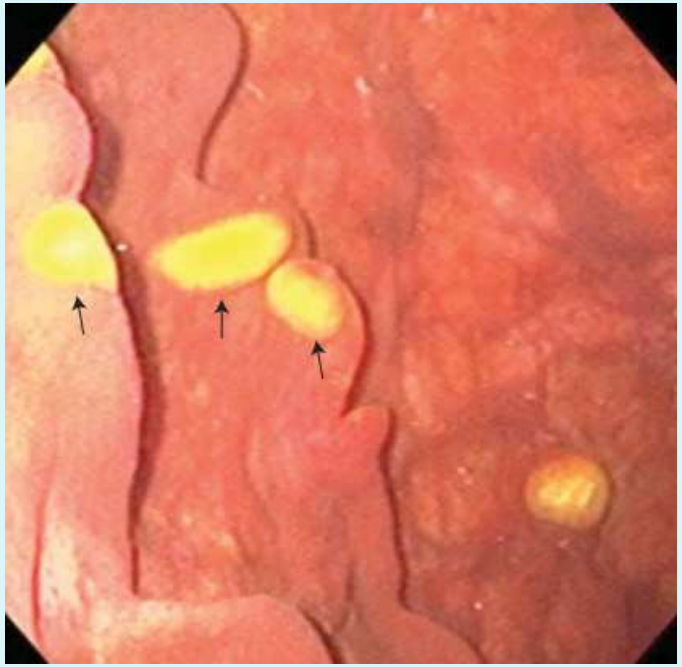

Bovine endometritis

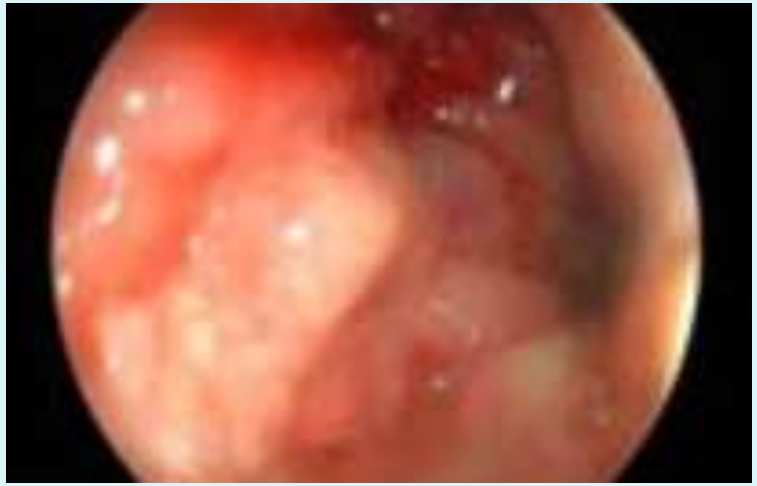


Buffalo

Operative Hysteroscopy

- Electrocoagulation
- Photo-ablation of cysts
- Hysteroscopic Laser surgery
- Hysteroscopic resection of tissues
- Collection of biopsies



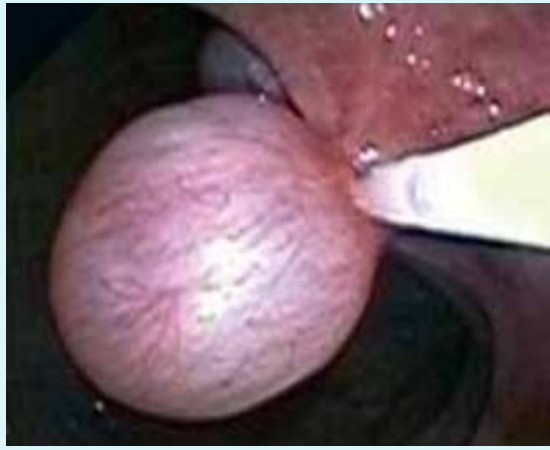

THANKS FOR YOUR PATIENT HEARING