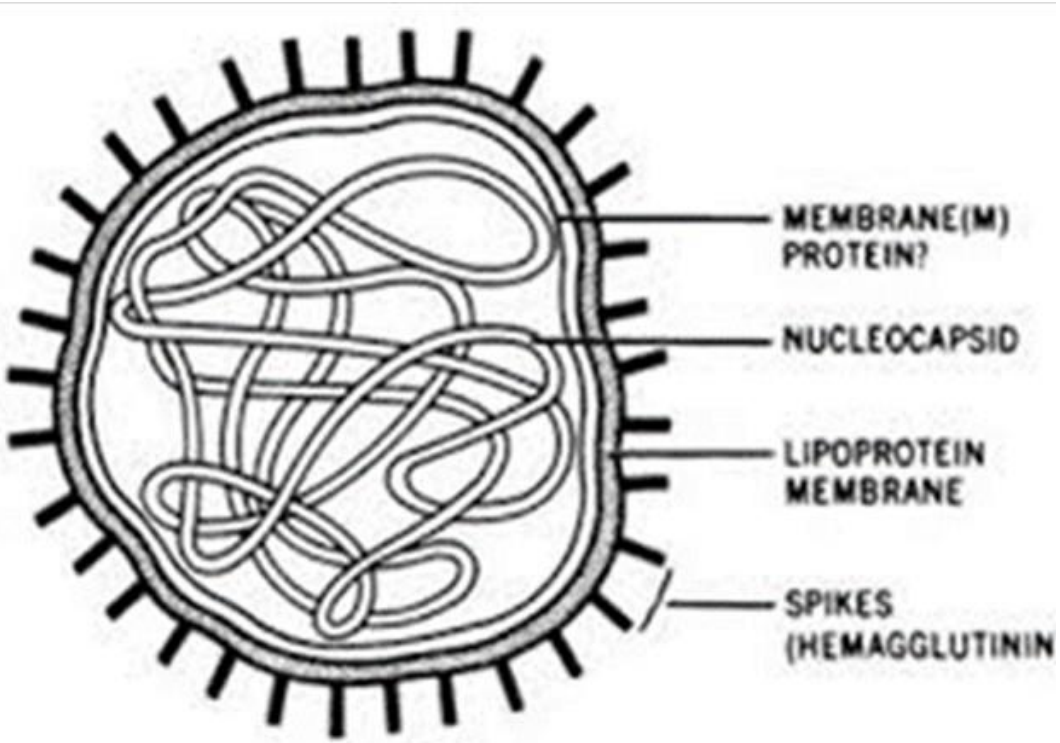

Rinderpestvirus

Rinderpest virus (RPV)

Bihar Veterinary College
Bihar Animal Sciences University

VMC 605

Dr Manoj Kumar,
Assistant Professor

Classification

- Family: *Paramyxoviridae*
- Genus: *Morbilivirus*
- Serotype: only one, with differences in virulence

Morphology

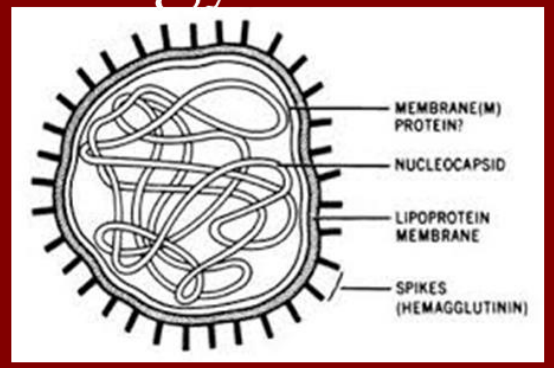



- Rinderpest electron microscopy

Rinderpest virus



Ultrastructural Findings

- Virions are enveloped, covered with peplomers, -“herringbone shaped”

- Helically symmetrical nucleocapsid, 660- 800nm x 18 nm

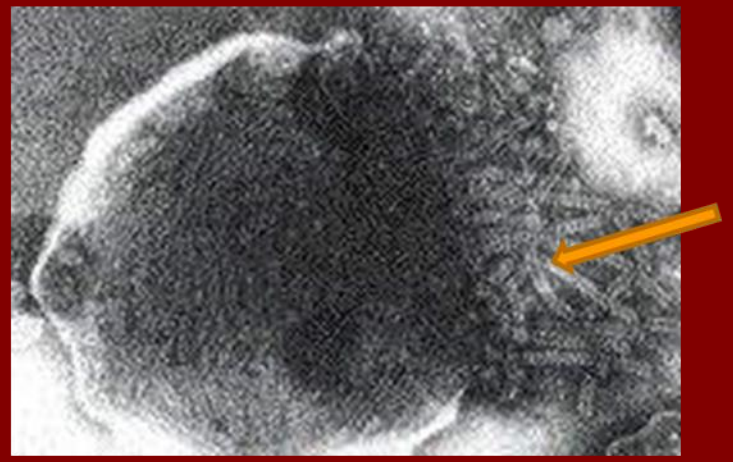

herringbone shaped

Rinderpest virus

The virus is relatively fragile and is immunologically related to viruses that cause

- canine distemper,
- measles, and
- peste des petits ruminants

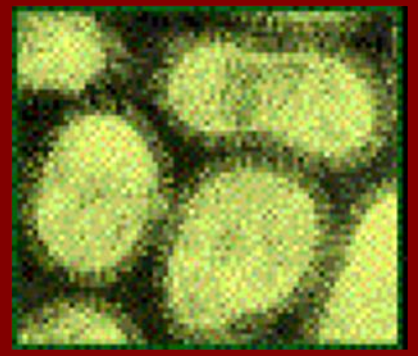

Replication

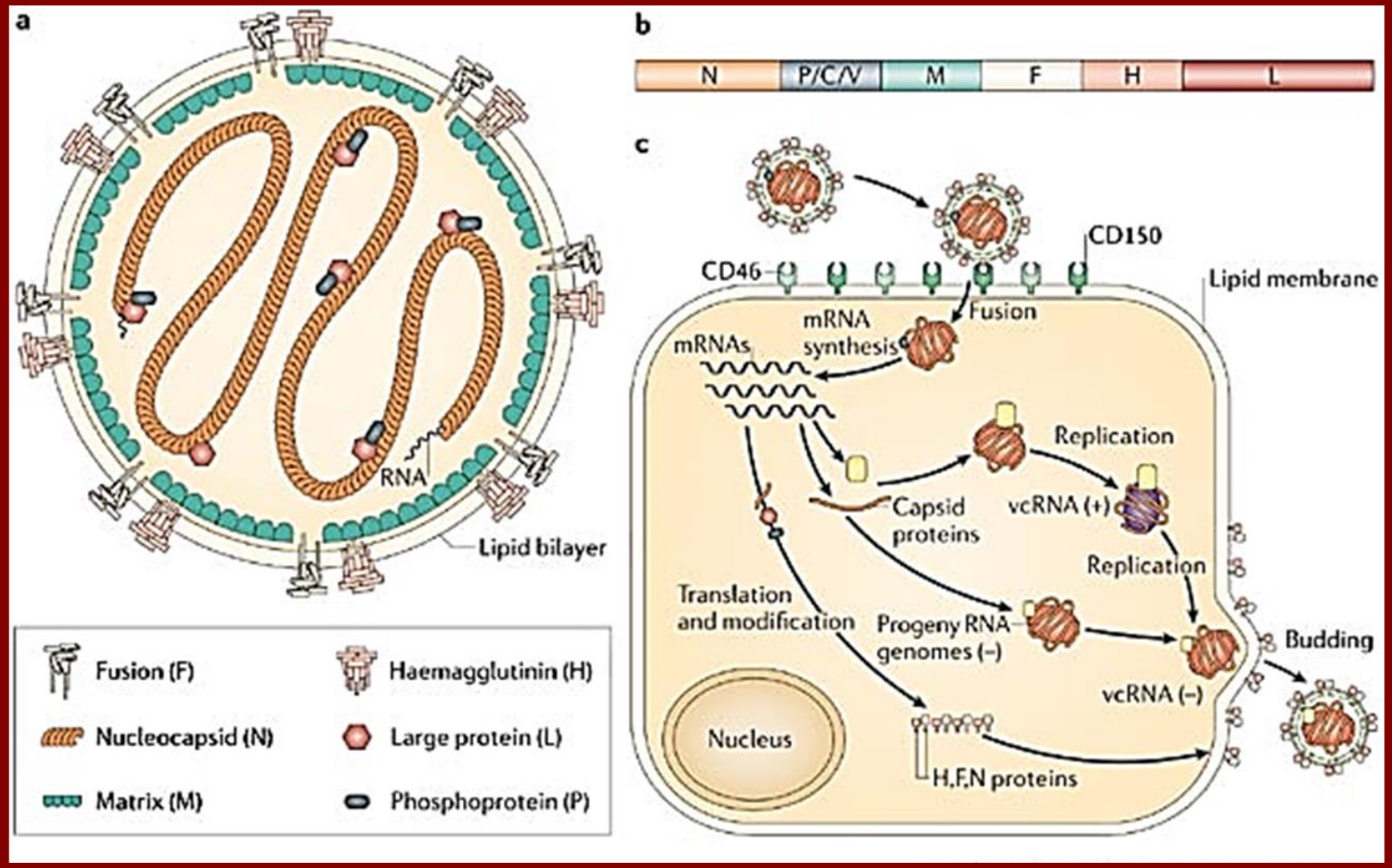

Replication – Schematic diagram

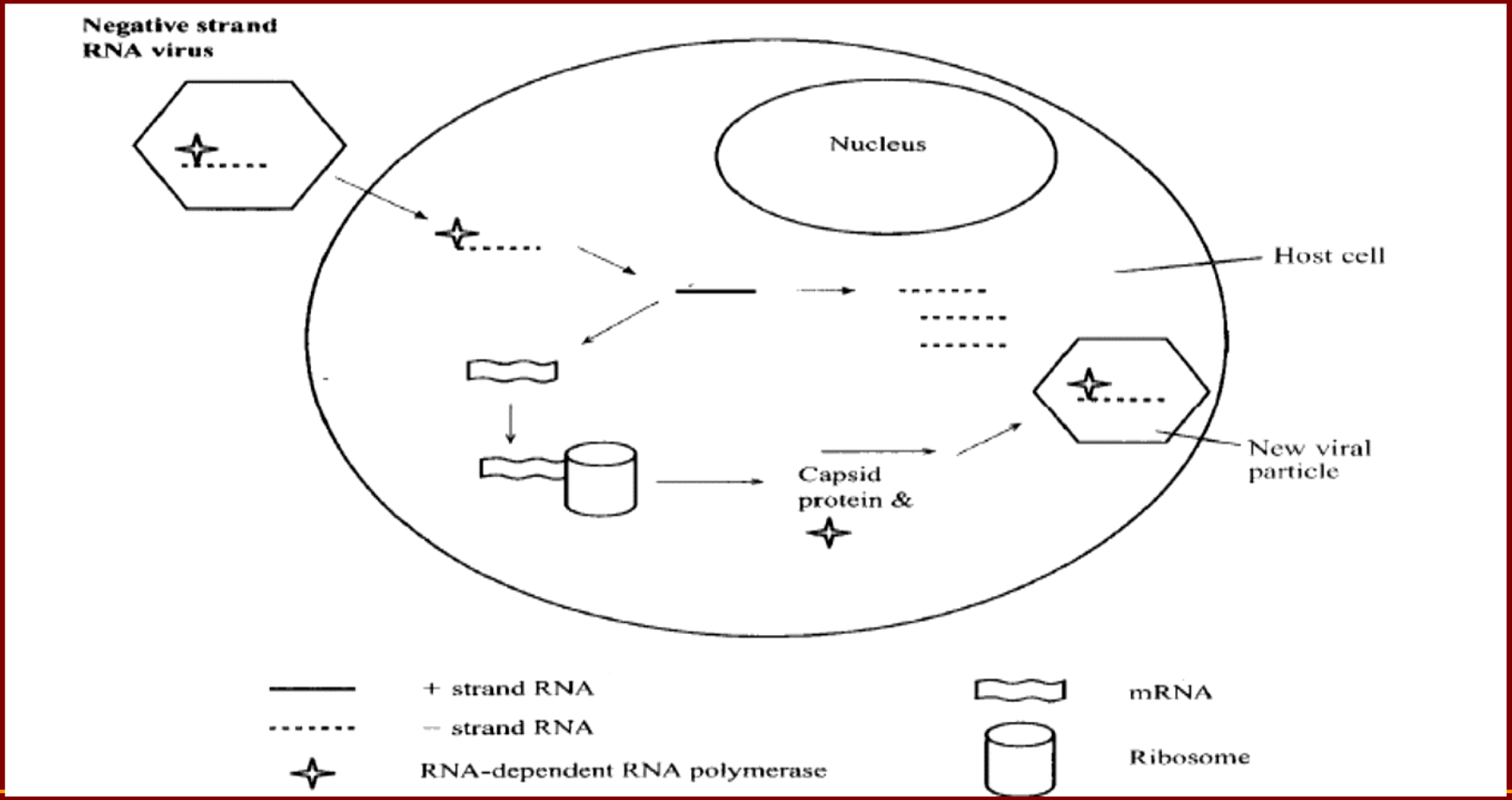

RPV causes Rinderpest

Rinderpest

- Rinderpest is an acute, highly contagious disease of cattle and swine caused by a Morbillivirus. In its acute form it is characterised by inflammation and necrosis of mucous membranes and a very high mortality rate.

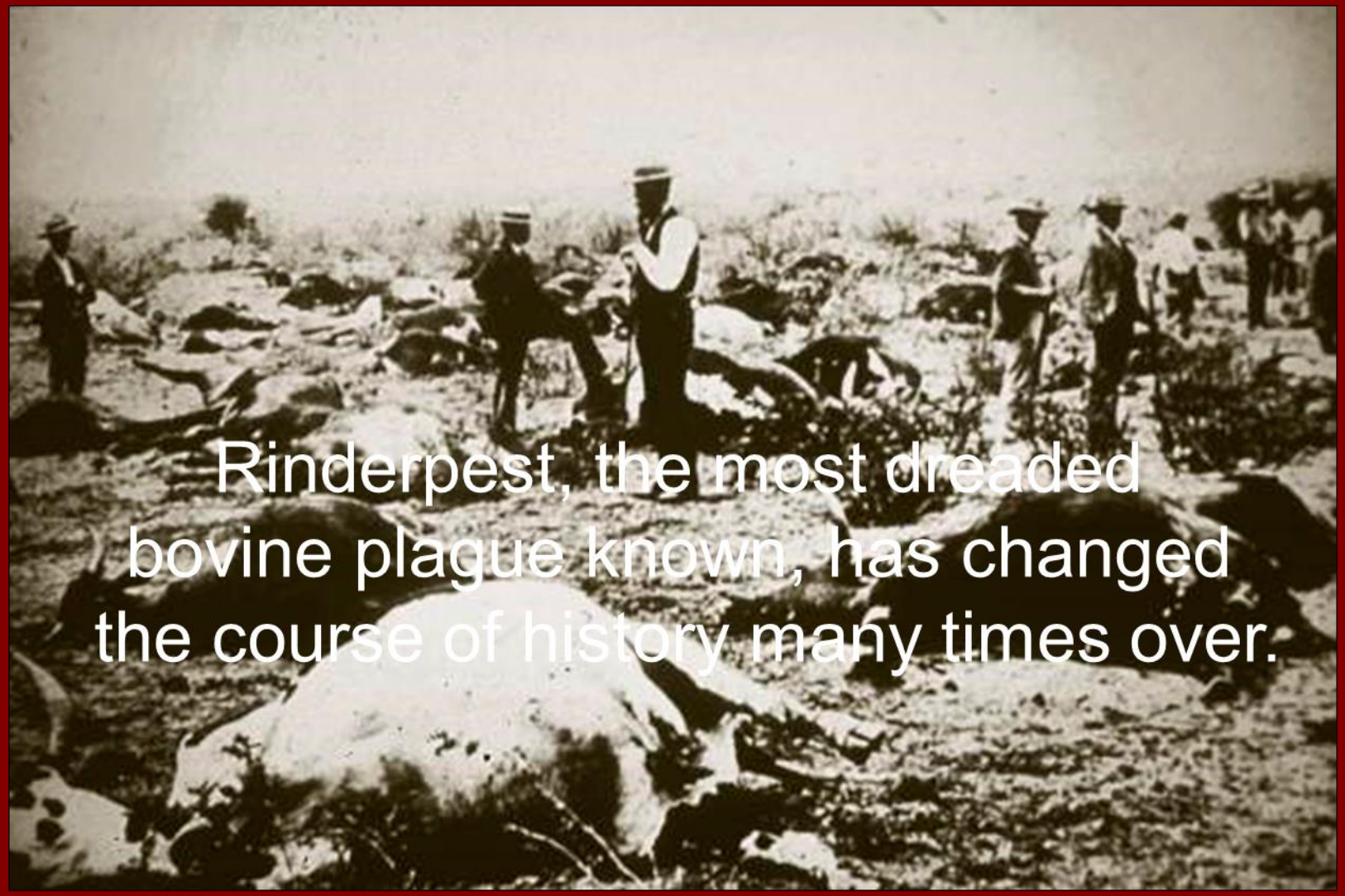
Rinderpest, the most dreaded
bovine plague known, has changed
the course of history many times over.

Because rinderpest was easily transmissible between animals, it is a major concern for livestock producers

‘ Century after century, rinderpest swept west over and around Europe and east over and around Asia with every marauding army causing the disaster, death and devastation that preceded

1. *The fall of the Roman Empire*,
2. *The conquest of Christian Europe by Charlemagne*,
3. *The French Revolution*,
4. *The impoverishment of Russia* and
5. *The colonisation of Africa*.’

Rinderpest

Rinderpest is characterized by high fever, lachrymal discharge, inflammation, hemorrhage, necrosis, erosions of the epithelium of the mouth and of the digestive tract, profuse diarrhea, and death.

The “four D’s” of Rinderpest:

Depression

Diarrhea

Dehydration

Death

Host Animals

Animal name	Context
Bos grunniens (yaks)	Domesticated host, Wild host
Bos indicus (zebu)	Domesticated host
Bos taurus (cattle)	Domesticated host
Bubalus bubalis (buffalo)	Domesticated host
Capra hircus (goats)	Domesticated host
Ovis aries (sheep)	Domesticated host

Systems Affected

- Digestive - Large Ruminants
- Digestive - Small Ruminants
- Multisystem - Large Ruminants
- Multisystem - Small Ruminants

Clinical Signs in cattle

The case definition of rinderpest is ocular and nasal discharges with any two of the additional signs:



+ fever
+ erosions in the mouth
+ diarrhea
+ dehydration
+ death

Also known as “cattle plague”

Rinderpest is a mucosal disease

Mass vaccination and eradication efforts have steadily decreased the prevalence and eradication of RP from globe

Rinderpest

- Rinderpest is a disease to be reportable to the OIE.

High Mortality

Can be a highly fatal disease → There is a good vaccine available and <u>proper</u> use of it can reduce fatality

High morbidity, High mortality → Morbidity can be greater than 90% in cattle.

Host Range

All cloven-hoofed animals are susceptible (not all are clinical)

Cattle and water buffaloes are highly susceptible

Host Range

- Sheep, goats, and yak are mostly subclinical

Host Range

- Camels – asymptomatic infections only



Incubation period

- Varies with strain of RPV, dosage, and route of exposure (3-15 days)
- Normally a range of 3-9 days (can be as long as 10-15 days with virus of low virulence)
- Duration: 2 or more weeks

**Virus remains present*
in blood and secretions
BEFORE
symptoms appear

Pathogenesis

Infection through respiratory route

↓

Virus growth in regional lymph node

↓

Primary viraemia (day 2-3)

Virus growth in regional lymph node

↓

Virus growth in lymphoid tissue

↓

Secondary viraemia (day 7)

Infection of target tissue

Pathogenesis

Pathogenic changes	Visual effects
Virus in excreted urine, feces, nasal/oral secretions and milk	None
Transmission by contaminated feed or inhalation	None
Virus binds to host enters via a fusion protein	None
Hemagglutinin neuraminidase mediates attachment	None
Replication in monocytes, tonsils, mandibular and pharyngeal lymph nodes	Lacrimation ,nasal discharge,inflammation of eye
Primary viremia in 48- 72 hours	Acute High rise of temperature, dullness , depression ,anorexia, decrease in milk production, lacrimation
Further replication in nasal, oral and alimentary mucosal cells	Occulo nasal mucopurulent discharge Inflammation , harmorrhages of mucosa, epiphora , constipation
Secondary viraemia	Furhter rise of temperature, depression and worse worsen condition
Focal necrosis, erosion,and fibrinous exudation	Severe bloody diarrhoea ,prostration , dehydration
Destruction of mesenteric lymph nodes and gut associated lymphoid tissue	Severe bloody diarrhoea ,prostration , dehydration
Immunodeficiency with invasion by other viruses or opportunistic bacteria	invasion by other viruses or opportunistic bacteria
Death from severe dehydration and occasionally from secondary infections	Severe dehydration,prostration shock and death
Survivors develop lifelong immunity	Survivors develop lifelong immunity

Pathogenesis

Pathogenic changes	Visual effects
Virus in excreted urine, feces, nasal/oral secretions and milk	Nine
Transmission by contaminated feed or inhalation	None
Virus binds to host enters via a fusion protein	None
Hemagglutinin neuraminidase mediates attachment	None
Replication in monocytes, tonsils, mandibular and pharyngeal lymph nodes	Lymphoid necrosis with loss of matugiant re lymphocytes and replacement by plasma cells & macrophages
Primary viremia in 48- 72 hours	slight lymphocytosis before the onset of pyrexia
Further replication in nasal, oral and alimentary mucosal cells, epiphora	Occulo nasal mucopurulent discharge Inflammation , harmorrhages of mucosa, constipation
Secondary viraemia	Furhter rise of temperature, depression and worse worsen condition
Focal necrosis, erosion,and fibrinous exudation	Necrosis of intestinal crypts with resultant erosions and ulcers
Destruction of mesenteric lymph nodes and gut associated lymphoid tissue	Syncytia; intracytoplasmic and intranuclear eosinophilic inclusion bodies in infectedepithelial cells
Immunodeficiency with invasion by other viruses or opportunistic bacteria	invasion by other viruses or opportunistic bacteria
Death from severe dehydration and occasionally from secondary infections	Severe dehydration,prostration shock and death
Survivors develop lifelong immunity	lymphocyte levels slowly return to normal

Pathogenicity

- First lesions on inner surface of lower lip, adjacent gum, cheeks, ventral tongue
- Dehydrated, soiled, fetid carcass
- Focal erosions and ulcers of the upper GI and respiratory tracts
- Erosions, ulcers, edema of abomasum
- Hemorrhagic, necrotic, edematous Peyer's patches
- Hemorrhage and congestion of cecum, colon, rectum (zebra stripes)
- Congestion, swelling and erosion of vulval and vaginal mucosa

Clinical signs in cattle

Two major forms of disease

- Acute or Classic form
- Peracute form

Clinical Signs in cattle (Peracute Form)

- Most often found in highly susceptible young and newborn animals
- No prodromal signs
- High fever (104-107 °F)
- Congested mucous membranes

Clinical Signs in cattle (Acute Form)

- Acute (classic) form characterized by pyrexia, erosive stomatitis, gastroenteritis, dehydration, and death
- Four stages
  1. Incubation period
  2. Febrile period
  3. Mucous membrane congestion
  4. Gastrointestinal signs

Clinical Signs in cattle (Acute Form)

- Fever - 104 to 107°F (40-42°C)
- Serous oculo-nasal discharge
- Leukopenia
- Depression
- Anorexia
- Constipation followed by diarrhoea
- Oral erosions

Clinical Signs in cattle (Acute Form)

- Decreases in fever and virus titer
- Diarrhea (may be watery or hemorrhagic)
- Dehydration, emaciation
- Prostration and death 6 to 12 days after onset of illness

General Clinical Signs

- Clinical signs include:
- High fever
- Red patches with discharge from around the eyes, nose and mouth
- Frothy saliva from the mouth
- Constipation followed by diarrhea
- After a few days, the infected animal dies.

General Clinical signs

- Fever
- Depression
- Nasal & lachrymal secretion
- Congested mucosas
- Mucosal erosions
- Severe diarrhea
- Leukopenia
- Death

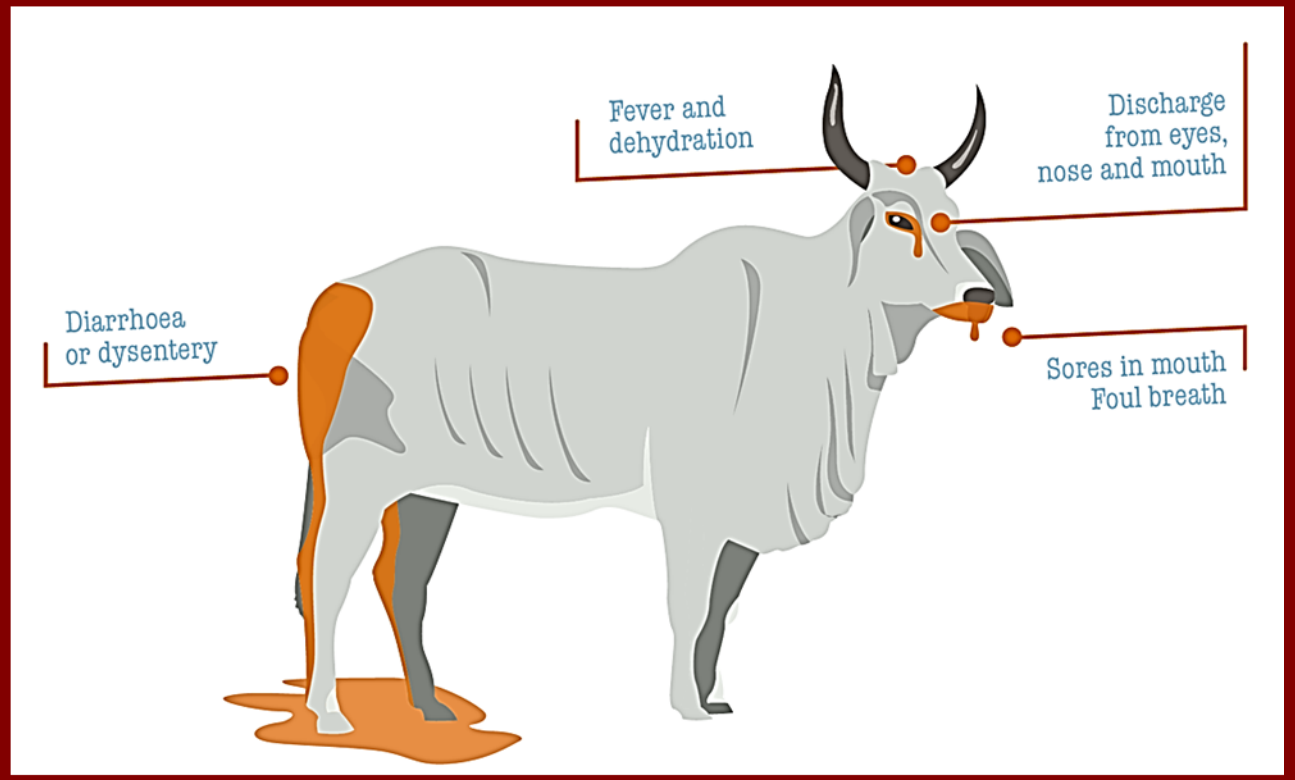

Clinical signs

The disease can occur with different level of virulence, the subclinical Infection In cattle, the acute form of the disease is characterised by:

- Sudden onset of fever (41.5 °C)
- Depression and loss of appetite
- Congestion of the visible mucosal surfaces
- Watery discharges from the eyes and nose
- Loss of milk production in dairy animals
- Necrotic lesions on mucous membranes of the mouth nostrils and urogenital tract
- Respiratory distress
- Diarrhoea (‘shooting diarrhoea’) starts about two days after appearance of mucosal lesions - faeces are profuse, dark, fetid and may contain mucus, blood and necrotic mucosa
- Dehydration, collapse and death
- Mortality rate 30-100%

Gross Pathology

- Dehydrated carcass with faecal staining of the legs
- Erosions of the mucosa in the mouth, pharynx and oesophagus *bran like deposit*
- Muco-purulent nasal exudate
- Congestion, oedema and erosion of the abomasal mucosa
- Prominent, necrotic Peyer's patches· severe congestion, ulceration and haemorrhages in the large
- intestine ('*tiger striping*' - haemorrhages of the longitudinal folds of the large intestine

Clinical Signs: swine

- Inapparent infection accompanied by modest fever
- Pyrexia, prostration, conjunctivitis, erosions of buccal mucosa, death

Clinical Signs: sheep and goats

- Clinical signs less precise that those in cattle
- Variable pyrexia and anorexia
- Inconsistent diarrhea

Mode of Transmission

- Direct Contact with infected animal
  - Respiratory and lachrymal secretions
  - Feces
  - Other body fluids

- Carriers:
  - Unknown…..wildlife?

Transmission(vehicle)

- Aerosol
- Vectors –tabanids*
- Ingestion
- Fomites

Diagnosis

- Samples:
  - Conjunctival Fluid
  - Intestinal contents or feces
  - Whole blood
  - Lymphoid tissue, lung, intestine
  - Serum

Diagnostic tests

- Presumptive diagnosis
- **Laboratory tests**:
  - Isolation and identification of virus
  - Serological test - AGID
  - Histopathology and immunohistochemistry
  - Reverse-transcription polymerase chain reaction (RT-PCR)

Isolation and identification of virus

- *Cell culture for isolation*
  - i. Culture on leukocyte fraction of whole blood
  - ii. primary calf kidney
  - iii. African green monkey kidney (Vero) cells
- Cytopathic effects (CPE)
  - a. Refractility,
  - b. Cell rounding,
  - c. Cell retraction with elongated cytoplasmic bridges (stellate cells)
  - d. Syncytial formation

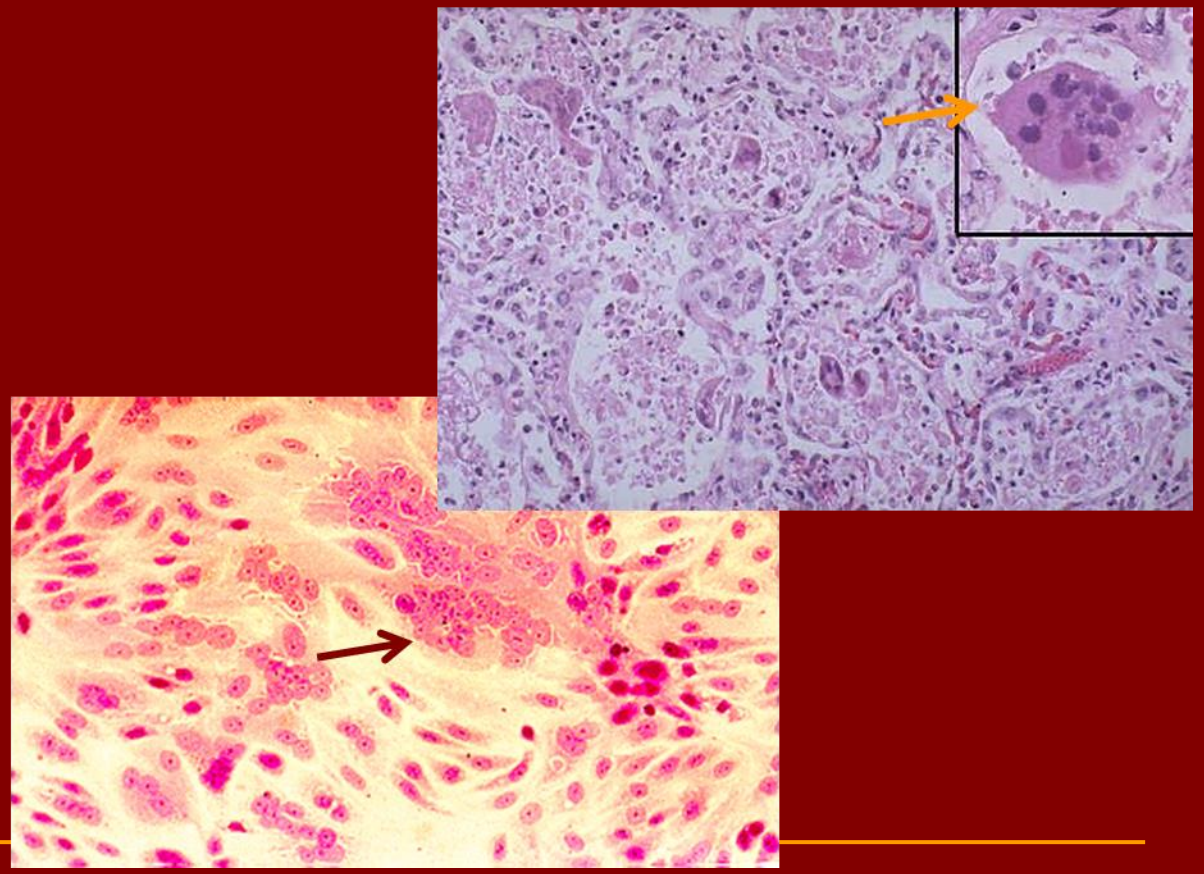

Serological Tests

- Antigen Detection
  i. Agar gel immunodiffusion
  ii. Counter immunoelectrophoresis test
  iii. Immunocapture ELISA
  iv. Indirect ELISA
  v. Virus neutralisation (VN) test [‘gold standard’]
- Antibody Detection
  i. Competitive ELISA
- Detection of virus genetic material

Reverse transcription polymerase chain reaction (RT- PCR)

Differential Diagnosis

- Bovine virus diarrhea
- Mucosal disease
- Infectious bovine rhinotracheaitis
- Malignant catarrhal fever
- Vesicular stomatitis
- Foot-and-mouth disease
- Salmonellosis
- Paratuberculosis
- Mycotic stomatitis
- Necrobacillosis

Prophylaxis

- Attenuated rinderpest vaccines were developed by passage of the virus in nonnatural hosts:
- For example, rabbit and embryonated eggs (lapinised/avianised) or goats (caprinised)
- Cell culture attenuated vaccine

GREP

- The Global Rinderpest Eradication Programme (GREP), a combination of vaccination campaigns with targeted
- Surveillance, followed by continued seromonitoring after cessation of vaccination

Current Status of Rinderpest

- Most importantly, rinderpest has become the first veterinary disease to be eradicated from the world.
- The disease, although still notionally on the list of diseases notifiable to the World Organisation for Animal Health (in French, the Office International des Epizooties, and hence abbreviated everywhere as 'OIE'), was declared eradicated by the Food and Agriculture Organisation of the UN (FAO) and the OIE in 2011 (FAO and OIE, 2011).
- There have been no confirmed cases of rinderpest in livestock or wildlife anywhere in the world since 2001
- The india has been declared free from RP since 1997due to efforts of National Programme for Rinderpest Eradication(NPRE)

Reference

- https://talk.ictvonline.org/ictv-reports/ictv_online_report/negative-sense-rna-viruses/mononegavirales/w/paramyxoviridae
- https://pubmed.ncbi.nlm.nih.gov/21783268/
- https://pubmed.ncbi.nlm.nih.gov/22748234/
- https://www.merckvetmanual.com/generalized-conditions/rinderpest/overview-of-rinderpest
- https://link.springer.com/chapter/10.1007/978-1-4419-8901-7_1
- http://www.fao.org/news/story/en/item/35548/icode/
- https://www.pirbright.ac.uk/viruses/rinderpest-virus

- **Rinderpest Virus**, Chapter 17. *Paramyxoviridae* and *Pneumoviridae,* **Fenner's Veterinary Virology**, Fifth Edition.

- **Rinderpest,** Chapter 2, 6*. Paramyxoviridae,* **Veterinary Virology, Third Edition,** Academic Press.

Acknowledgement

- Content and images have been taken from www.google.com.
- The content taken from website is for academic purpose and has no commercial use.
- The contributors are duly acknowledged.

Any questions???

Thanks for listening