Studies on the Pathology of Kidneys of Japanese Quail

(*Coturnix coturnix japonica*)

THESIS

SUBMITTED TO THE

RAJENDRA AGRICULTURAL UNIVERSITY

PUSA - 848125 (SAMASTIPUR)

(B I H A R)

By

Dr. Sudhir Kumar

Reg. No. M/Vety. Patho/68/1998 99

FOR THE AWARD OF THE DEGREE OF

Master of Veterinary Science

IN

VETERINARY PATHOLOGY

Post-Graduate Department of Veterinary Pathology

BIHAR VETERINARY COLLEGE

PATNA 800 014 (BIHAR)

2000

BIHAR VETERINARY COLLEGE
PATNA, BIHAR
LIBRARY

Acc. No. 12920

DATE DUE

This book is due on the date last stamped. An over-due charge of **10 Paise** will be charged for each day the book is kept over-time.

Studies on the Pathology of Kidneys of Japanese Quail

(*Coturnix coturnix japonica*)

THESIS

SUBMITTED TO THE

RAJENDRA AGRICULTURAL UNIVERSITY

PUSA - 848125 (SAMASTIPUR)

(B I H A R)

By

Dr. Sudhir Kumar

Reg. No. M/Vety. Patho/68/1998 99

FOR THE AWARD OF THE DEGREE OF

Master of Veterinary Science

IN

VETERINARY PATHOLOGY

Post-Graduate Department of Veterinary Pathology

BIHAR VETERINARY COLLEGE

PATNA 800 014 (BIHAR)

2000

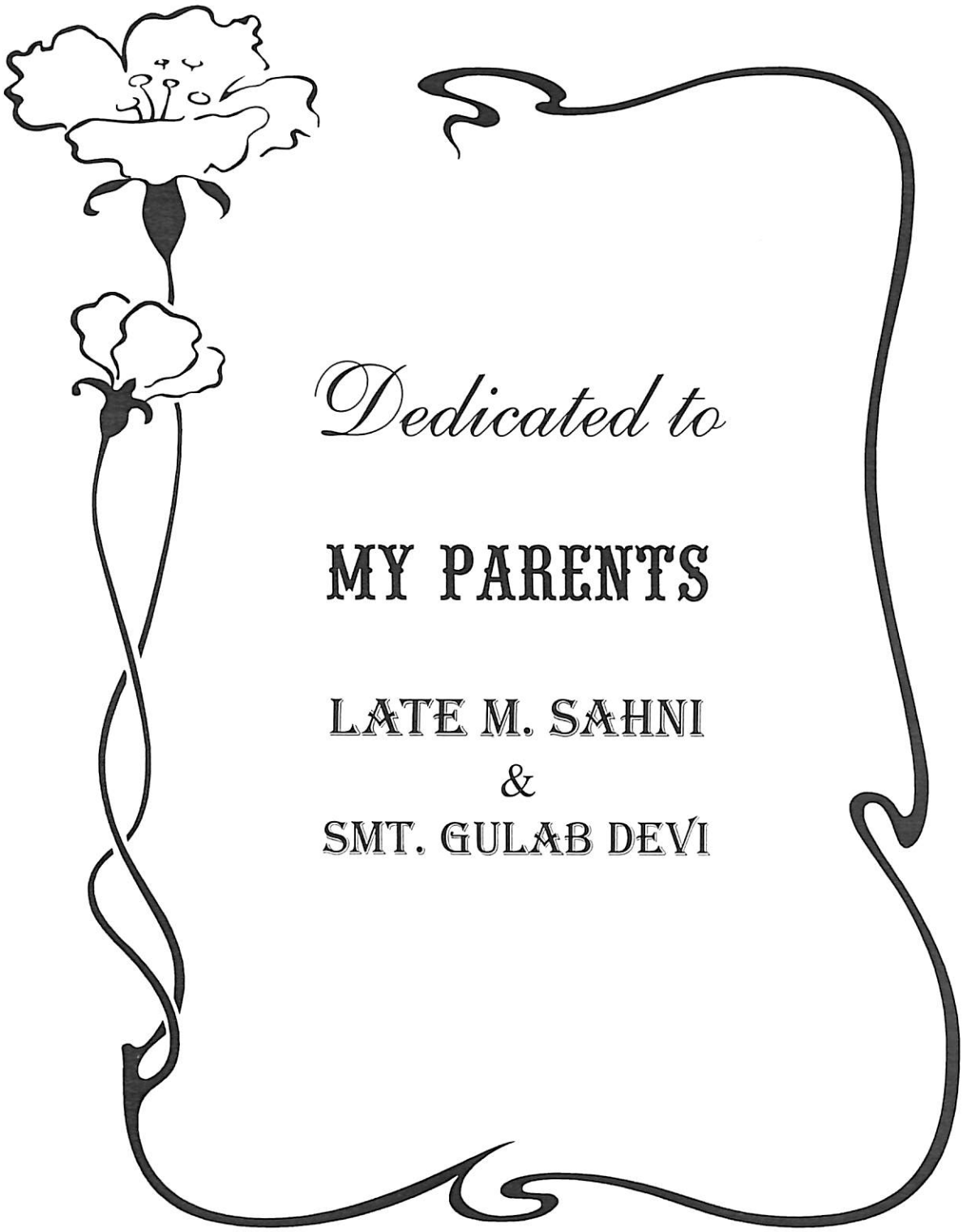
Dedicated to
MY PARENTS
LATE M. SAHNI
&
SMT. GULAB DEVI

POST GRADUATE DEPARTMENT OF VETERINARY PATHOLOGY
Bihar Veterinary College, Patna – 800014.
(Rajendra Agricultural University, Bihar)

CERTIFICATE – I

This is to certify that the thesis entitled '***STUDIES ON THE PATHOLOGY OF KIDNEYS OF JAPANESE QUAIL (Coturnix coturnix japonica)***" submitted in partial fulfilment of the requirements for the **Degree of Master of Veterinary Science (Pathology) of the faculty of Post-graduate studies, Rajendra Agricultural University, Pusa, Bihar** is the record of bonafide research carried out by **Dr. Sudhir Kumar** under my supervision and guidance. No part of the thesis has been submitted for any other Degree or Diploma.

It is further certified that such help or information received during the course of this investigation and preparation of the thesis have been duly acknowledged.

30/1/2001.

(Dr. Binay Kumar Sinha)
Associate Professor & Head
Department of Veterinary Pathology,
Bihar Veterinary College,
Patna - 14
Major Advisor

Endorsed :

30/1/2001

(Chairman/Head of the Department)

CERTIFICATE – II

We, the undersigned, members of Advisory Committee of **DR. SUDHIR KUMAR**, a candidate for the degree of **Master of Veterinary Science** with **Major in Pathology,** have gone through the manuscript of the thesis and agree that the thesis entitled "***STUDIES ON THE PATHOLOGY OF KIDNEYS OF JAPANESE QUAIL (Coturnix coturnix japonica)***" may be submitted by **Dr. Sudhir Kumar** in partial fulfilment of the requirement for the degree.

30/1/2001

(Dr. Binay Kumar Sinha)
Chairman
Advisory Committee

Members of Advisory Committee :

1. **Dr. L. N. Prasad,**
   Associate Professor of Pathology
   Bihar Veterinary College, Patna-14

   30.1.2001

2. **Dr. M. K. Roy,**
   Associate Professor and Head of Anatomy.
   Bihar Veterinary College, Patna – 14

   30/1/2001

3. **Dr. S. R. P. Sinha,**
   Assistant Professor of Parasitology,
   Bihar Veterinary College, Patna – 14,

   30/1/2001

4. **Dr. Abhay Kumar Sinha,**
   Assoc. Professor of V.P.H.
   Bihar Veterinary College, Patna – 14.

CERTIFICATE – III

This is to certify that the thesis entitled "***STUDIES ON THE PATHOLOGY OF KIDNEYS OF JAPANESE QUAIL (Coturnix coturnix japonica)***" submitted by **DR. SUDHIR KUMAR** in partial fulfilment of the requirement for the Degree of **Master of Veterinary Science (Pathology) of the faculty of Post-graduate studies, Rajendra Agricultural University, Bihar** was examined and approved on ..23-1-2002..... ~~2001.~~

23/1/2002

(Dr. Binay Kumar Sinha)
Chairman
Examination Committee

Members of Advisory Committee :

1. **Dr. L.N. Prasad,**
   Associate Professor,
   Department of Pathology,
   Bihar Veterinary College, Patna – 14.

   23.1.2002

2. **Dr. M.K. Roy,**
   Assocociate Professor & Head,
   Department of Anatomy,
   Bihar Veterinary College, Patna – 14.

   23/1/2002

3. **Dr. S.R.P. Sinha,**
   Associate Professor,
   Department of Parasitology,
   Bihar Veterinary College, Patna – 14.

4. **Dr. Abhay Kumar Sinha,**
   Associate Professor,
   Department of Vety. Public Health,
   Bihar Veterinary College, Patna – 14.

   23/1/02

Dean, Post-graduate studies

ACKNOWLEDGEMENT

I wish to express my deep sense of gratitude to my major Advisor, Dr. Binay Kumar Sinha, M.V.Sc., Ph.D., Associate Professor and Head, Department of Pathology, Bihar Veterinary College, Patna, Bihar, for his immense guidance, keen interest, valuable criticism and untiring help during the course of this study. I recollect his critical trends which helped me to improve my knowledge over the years.

I feel extremely happy to express my sincere thanks to Dr. L.N. Prasad, M.V.Sc., Ph.D. Associate Professor, Department of Pathology, Bihar Veterinary College, Patna for constant help, valuable suggestions and untiring cooperation during the entire course of study.

I, express my sincere thanks to Dr. S.R.P. Sinha, M.V.Sc., Ph.D., Associate Professor, Department of Parasitology, Bihar Veterinary College, Patna for his constant help and inspiration throughout this study.

I also extend my thanks to Dr. M.K. Roy, M.V.Sc., Ph.D., Associate Professor and Head, Department

of Anatomy, Bihar Veterinary College, Patna, for his constant help, encouragement and active interest from the very onset till the end of the present study.

I am grateful to Dr. Abhay Kumar Sinha, M.V.Sc., Ph.D., Associate Professor, Department of Veterinary Public Health, Bihar Veterinary College, for his constant suggestions and necessary help during the study.

I express my sincere thanks to Dr. C.D.N. Singh for extending help in preparation of this manuscript.

I extend my warmest thanks to Dr. S.P. Verma, M.V.Sc., Ph.D., Associate Professor, Department of Medicine, Bihar Veterinary College, Patna, Bihar whose immense help and encouragement have nurtured me throughout the study.

I am extremely thankful to Dean-Cum-Principal, Bihar Veterinary College, Patna, Bihar for providing necessary facilities and help to complete this studies.

I am also thankful to Dr. B.N. Mishra, Campus, Librarian, Bihar Veterinary College, Patna, Bihar for providing all the possible necessities regarding library facilities.

My thanks are also due to Sri. Arjun Prasad, Laboratory Assistant, Shri Banwari Singh and other technical staffs of the Department of Pathology for Laboratory assistance during laboratory work. Warmest thanks to Shri Binay Kumar, Typist Cum-Clerk for his help in careful typing of the manuscript.

I must extend my thanks to my friends Dr. Param Bodh Kumar, Dr. Arun Kumar, Dr. Ashok Kumar, Dr. Sudhir Kumar, Dr. Deepak Oraon and seniors Dr. Sukhdeo Mukhiya, Dr. Sudhir Ranjan Sahni and Dr. Sanjeev Thakur for their co-operation and time-to-time encouragement.

I am also thankful to Mr. Rajeev Prasad & Anit Prakash of Srishti Computers for typesetting of this manuscript.

I also convey my deep sense of gratitude to my wife, Mrs. Sangi and all members of my family for extending unceasing moral support and encouragement.

Place :

Date :

Sudhir Kumar

Dr. Sudhir Kumar

Contents

Chapter No.	Description	Page No.
1.	Introduction	1-4
2.	Review of Literature	5-31
3.	Materials and Methods	32-36
4.	Results	37-44
5.	Discussion	45-51
6.	Summary and Conclusion	52-56
	Bibliography	i-xii
	Total No. of Tables	*3*
	Total No. of Figures	*20*

List of Tables

Table No.	Description	Page No.
1.	Showing total number of birds examined grossly	32
2.	Statistical material of renal disease in quail.	38
3.	Distribution of various kinds of renal diseases in quails	39

List of Figures

Fig. No.	Description
1.	Gross photograph of dead quail showing hyperaemic and swollen kidneys.
2.	Gross photograph of dead quail showing hyperaemic changes in the kidneys.
3.	Gross photograph of dead quail showing haemorrhages in the kidneys
4.	Gross photograph of dead quail showing deposition of urates on kidneys.
5.	Gross photograph of dead quail showing deposition of urates on kidneys.
6.	Photo-micrograph of section of kidney of quail showing changes of hyperaemia. (H. & E. X 100)
7.	Photo-micrograph of section of quail kidney showing changes of hyperaemia in which blood vessels were engorged with blood. (H. & E. X 100)
8.	Photo-micrograph of section of quail kidney showing changes of haemorrhages in which erythrocytes were found infiltrated in the parenchyma. (H. & E. X 100)
9.	Photo-micrograph of section of quail kidney showing changes of haemorrhages in which erythrocytes were found infiltrated in the parenchyma and degenerative changes in the lining epithelium of tubules (H.&E.X100)

10. Photo-micrograph of quail kidney showing changes of degeneration in tubular epithelial cells with desquamation at places. (H. & E. X 150)

11. Photo-micrograph of quail kidney showing changes of necrosis and desquamation of epithelial cells from basement membrane of tubules. (H. & E. X 150)

12. Photo-micrograph of quail kidney showing changes of occlusion of lumen of tubules by desquamated cells. (H. & E. X 100)

13. Photo-micrograph of quail kidney showing changes of acute interstitial nephritis in which leucocytes were found infiltrated in interstitial tissues between tubules. (H. & E. X 100)

14. Photo-micrograph of quail kidney showing changes of deffuse infiltration of leucocytes in the kidney parenchyma (H. & E. X 100)

15. Photo-micrograph of quail kidney showing presence of thrombus in the dilated blood vessels and necrotic changes in the epithelium of kidney. (H. & E. X 100)

16. Photo-micrograph of section of quail kidney showing changes of chronic interstitial nephritis in which there was proliferation of fibrous connective tissue. (H. & E. X 100)

17. Photo-micrograph of section of quail kidney showing diffuse infiltration of leucocytes mostly made up of monocytes and lymphocytes in chronic nephritis. (H. & E. X 100)

18. Photo-micrograph of section of quail kidney showing changes of suppurative nephritis in which large number of heterophils and erythrocytes were found accumulated replacing normal tubules. (H. & E. X 100)

19. Photo-micrograph of section of quail kidney showing the presence of cysts in the medullary region lined by fibrous connective tissue. (H. & E. X 100)

20. Photo-micrograph of section of quail kidney showing fibrosis of wall of the blood vessels. (H. & E. X 100)

Chapter 1

Introduction

INTRODUCTION

About 50 to 60 years ago the Japanese Quail (*Coturnix coturnix japonica*) has a wild life in the Japanese Island. Few Japanese fanciers kept the birds in order to listen to their songs. Now-a-days its meat and eggs are considered to be one of the food delicacies in many parts of the country. Quails are introduced in India in the year 1974. It is commonly known in Hindi as 'Bater'. It was introduced by the Center of Advanced Studies in poultry science at IVRI, Izatnagar and has occupied a unique place in avian research throughout the world today. Due to its close resemblance with turkey and chickens it serves as a suitable research model for conducting pilot experiments.

In USA, about 100 laboratories use Japanese quail as a pilot model. Furthermore, because of growing interest in the field of virally based cancer of the avian species, the Japanese quails commands a unique strain as a model for research studies. Broiler quails are marketed at around 6 weeks of age. Processed eggs and meat are eaten in several European countries, USA, Canada and South Arabia (Baumagartner, 1994).

In India it was a purview of wild life protection Act, 1972. But today it has become third largest avian species in number, next to

chicken and duck (Ahuja, 1996). The number of quails increased considerably during recent years and estimated to be about one lakh broilers per week (Agrawal, 1986).

The importance of Japanese quails in raising the low nutritional standard of our population in Bihar can not be over emphasized. Eggs and meat are of the richest sources of proteins and vitamins for mankind. The average Indian diet is extremely deficient in both of these nutrients. Quails therefore, offer the most quickest means of increasing the production of high quality proteins. Japanese quail egg production will prove to be equally or economical to a farmer (Wahab, 1990). Moreover, our population is increasing very fast and we have to meet the rising protein requirements.

To meet the increasing demand, well management of quail keeping and controlling the diseases is foremost important. Quails are very sensitive to abrupt environmental changes particularly during the first week of their life. They need better care during the brooding age. Inspite of extensive work done on disease control in poultry in recent years, there are large numbers of disease conditions of which the etiology has not been established satisfactory. The importance of disease of poultry has been well recognised in the development of poultry breeding with regard to disease control programme. The exposure of urinary system through the

environment via the circulatory system exposes them to diseases quite frequently. In many of the affections, it has not always been possible to associate any single etiological factor with certain pathological processes reported, which would indicate the need of establishing the pathological entities.

Kidneys being highly specialized organ are prone to mild infection and as such it becomes obligatory on the part of the pathologists to attempt systematic and thorough study of kidney diseases. The toxic agents of blood whether they are vegetable, mineral or microbial in origin, do some harm to structure of the kidneys while passing through these structures.

Kidney diseases causes economic losses due to death, retardation in growth as well as reduction in productivity.

Although some work on the diseases of quails have been carried out but there is very meager information regarding the diseases of kidneys of the quails.

Keeping in view of the above facts the present study has been under taken to give a systematic account of common disease conditions encountered in the kidneys of quail and the structures by which these may be recognised grossly and histopatholgically. Although there is a vast literature available on these conditions of large domesticated animals but the information on the disease of

kidney of quail is insufficient and much remains to be added. The present study will help veterinarians to adopt correct measures for control and treatment of diseases of kidney of poultry and more particularly of quails.

The present study was conducted having the following objectives :-

1. To study the type, pattern and morphology of various kidney affections in Japanese quails found in and around Patna.
2. To study the gross pathological lesions in the kidneys of Japanese quails.
3. Histopathological study of diseased kidneys to ascertain microscopical alterations in quails.
4. Attempt to ascertain the different etiological factors of disease conditions of kidneys using different staining procedures.

*****

CHAPTER 2

Review of Literature

REVIEW OF LITERATURE

Quails are very sensitive birds and prone to diseases due to abrupt environmental changes. The sensitivity to diseases is more potent during the first two weeks of life. The patterns of diseases developing in quail are more of less similar to those of chickens. Quails suffer from *Aspergillosis fumigatus* (brooder pneumonia) infection. Ulcerative colitis in quails is caused by *Clostridium colunium*. They also suffer from aplastic anaemia and infectious bronchial diseases (IBD).

Dutton *et al.* (1973) found MD in Japanese quails. The birds were infected with acute MD virus. The lesions were noticed in kidney, spleen, liver and the lymphoproliferative cells included heterogenosis lymphoid cells and occasional plasma cell.

Carlson *et al.* (1974) described an outbreak of reticuloendotheliosis in Japanese quail. Tumor masses were observed in liver, kidney, heart and sciatic nerve etc. The tumor tissues consisted of bizzare nuclei, mitotic figures, mishappened nuclei and prominent pleomorphic cytoplasm.

Fujimoto *et al.* (1975) carried out pathological studies in MD in Japanese quail and found lymphoreticular cell proliferation in organs like kidneys, liver and spleen etc. They also noticed

immuno-fluorescent antigen in the epidermis and superficial epithelial cells. The clinical findings in these bird included depression and diarrhoea.

Khare *et al.* (1975) described a transovarian transmission study of MD in Japanese quail. Breeding quails were infected with JM strain and MD specific fluorescent antigen was observed in fibroblast, one kidney cell culture from embryos of parents infected at one day of age.

Bar *et al.* (1976) also described regulation of intestinal calcium absorption in the laying quails independent of kidney vitamin-D hydroxylation and found that intestinal Ca-absorption was considerably higher during shell formation that in periods of uterine inactivity in quails given cholecalciferol or DHCC. They suggested that the mechanism responsible for that difference was independent of vitamin-D hydroxylation in the kidney.

Stone and Soares (1976) studied effects of dietary selenium level and lead toxicity in Japanese quails. They noticed that selenium appears to have variable effect on the concentration of lead in liver, kidney and tibia. Selenium added to lead diets resulted in significantly more lead in the kidney tissue but there was little or no effect on liver or tibia lead.

Stone *et al.* (1977) studied delta amino levulinic acid dehydratase indicator of lead exposure in Japanese quails. These studies indicated that in quails consumption of 25 ppm lead fed for 2 weeks had no significant weight on body weight on size of kidneys and liver and duodenum. The renal and hepatic concentration were higher in poisoned birds than in control.

Bush and Marguardt (1978) studied the effects of starvation and molecular weight on turnover of soluble protein from five tissue of Japanese quails. They observed that starvation for 3 to 10 days reduced 3H: 14C ratio in liver, kidney and brain and heart muscle soluble protein and increased 3H: 14C ratio of breast muscle.

Baumagartner *et al.* (1981) studied the mortality in commercial duck between August 1979 and March, 1980, they isolated viruses and pathogenecity test was induced in six weeks old chicken.

Mohanty and Verma (1982) reported that the important quail diseases are ulcerative enteritis, quail bronchitis, avian encephalomyelitis, avian influenza, lymphoid leucosis and Marek's disease.

Sah *et al.* (1983) reported systemic proteus infection in Japanese quails and congestion was noticed in lungs, kidneys, liver of Japanese quail.

Gromysz *et al.* (1984) reported tissue respiration in quails under physiological condition and under poisoning with chlorofenvinphos and found that chlorofenvinphos increased oxygen consumption by muscle but decreased that of kidney.

Brown and Fletcher, (1985) studied the ultra structural P.M. Changes in chicken kidneys at 27^0 C.

Huff *et al.* (1986) studied the effects of aflatoxin and deoxynivalenol mixing them in the feed of the broiler chickens and found increase in relative weight of proventriculus, gizzard, spleen, liver and kidney due to interaction between aflatoxin and deoxynivalenol.

Moorthy *et al.* (1986) reported the microscopical observation and formation of nodules, bile duct hyperplasia in the liver, lymphoid hyperplasia of spleen, chronic bronchitis of lungs, mild periglomerular fibrosis in kidneys and neuronal and neurophagia when the chickens were given aflatoxin @ 3.12 ppm liver for 3 weeks.

Balachandran and Ramakrishnan (1987) found hyperplasia of bile duct and foccal necrosis of liver with a prominent regenerative changes of hepatic cells forming a ductular pattern surrounded by a thin layer of fibrous tissue. Further they observed foccal necrosis and hyaline degeneration in the thigh muscles and tubular degeneration, haemorrhage and lymphocytes infiltration in

the kidneys of broiler chickens fed a diet containing aflatoxin @ 1.0 and 3.0 ppm.

Balachandran and Ramakrishnan (1987) noted enlarged, yellow coloured, mottled, soft and friable liver in the cobb broiler chickens by feeding them with a dietary aflatoxin at a concentration of 1.0 ppm for a period of 4 weeks (0 to 28 days). Further they reported that kidneys were enlarged, pale or congested with a few petechial haemorrhage at 1.0 ppm level and were more marked at 3.0 ppm level. Similarly, extensive epicardial haemorrhage, severe splenomegaly, extremely pale breast muscles and copious catarrh of intestinal mucosa were observed due to feeding of aflatoxin at 3 ppm level.

Dafalla *et al.* (1987) reported fatty and studded, enlarged liver with haemorrhages and some containing haematoma in the dead hens which were fed a diet containing AFB_1 @ 142 ppb. Further they reported that kidneys of those hens were enlarged and congested.

Dafalla *et al.* (1987) reported cytoplasmic vacuolation of hepatocytes, necrotic foci and lymphoid nodules in the peripheral area of liver in hens fed with AFB_1 @ 142 ppb in diet. Further they reported that epithelial cells of renal tubules were vacuolated. The renal medula were congested and lymphocytic nodules were scattered in the cortex.

Huff *et al.* (1988) found a significant ($p<0.05$) increase in the relative weight of liver, kidney, spleen, pancreas, heart and proventriculus due to synergistic toxicity of aflatoxin and T-2 toxin in the broiler chickens.

Mollenhauer *et al.* (1989) reported enlargement of bile canaliculi, reduction in mitochondrial size, mild lymphocytic infiltration, hepatocellular degeneration and necrosis as primary lesions in the liver of chicks fed with 5.0 μg aflatoxin in per gm of feed. Further they reported the thickening of glomerular basement membrane at 2.5 and 5.0 μg/gm levels.

Gangadharan *et al.* (1989) made an analytical study on mortality in Japanese quails and reported that in young chicks, the prevalence of various diseases such as omphalitis (41.08 percent), hepatosis (1.99 percent), pulmonary congestion and edema (18.37 percent).

Semen *et al.* (1989) in their studies on the metabolism of decoquinate in chickens and Japanese quail compared pathways of decoquinate (DO) excretion. Samples of liver, heart, kidney, bile, skin fat and muscle were analysed for 14C. Quail appeared to excrete peak amounts of detectable 14C one day earlier. Their result indicated that chickens and quail metabolise 14C-DQ at comparable rates and by similar pathways.

Imai *et al.* (1990) isolated Marek's disease virus from Japanese quails affected with this lymphoproliferation disease. As reported by them, there were outbreaks of lymphoproliferative lesions were noticed and some quails had M.D. virus and feather tips antigens. Moreover M.D. was found in one quail out of 22 quails in their studies. Their findings indicated that MDV was etiologically involved in present outbreak of lympho-proliferative disease in Japanese quails.

Rao *et al.* (1990) described clinical signs and gross lesions caused by *Eimeria uzura* infection and aflatoxicosis in Japanese quail. Increase relative weights of liver, kidneys and spleen were observed due to aflatoxin sensitivity in quails. The bursa of fabricius revealed depletion of lymphocytes and hypoplastic changes in the after toxic quails.

Kaul and Pradhan (1991) described immune pathology in Marek's disease in quails. About 25-30% of the glomeruli of kidney of infective quails shows deposits of immune complexes in the kidney glomeruli of quails infected with MD virus and concluded that autoimmunity might have a pathogenic role in Marek's disease.

Kupsh *et al.* (1991) studied renal damage induced by uranyl nitrate and estradiol-17 beta in Japanese quails, and Wister rats. Alterations were noticed in kidneys of Japanese quails and

Wister rats. Degenerative and necrotic changes were noticed in the epithelium of distal convoluted tubules of quails. Changes in the glomeruli and collective ducts of the affected quails were not prominent. Protein deposits were found in kidneys of rats and quails. Calcification of degenerating epithelium, calcified casts in tubules and damage to collecting tubules were seen in quails. Estradiol-17 beta induced renal lesions in quails. Both toxin (uranyl nitrate and estradiol-17 beta) produced severe lesions in the kidney of quails and rats following a combined administration of these two toxins.

Arshad *et al.* (1992) found microscopic changes as congestion, fatty changes, necrosis, leucocytic infiltration and haemorrhage in liver. Further they found moderately enlarged, congested kidneys with deposits of urate in ureters, and degenerated and necrosed kidneys tubules with mononuclear cell infiltration in birds fed with higher dose (5310 ppb) of aflatoxin.

Larochelle *et al.* (1992) conducted the pathological study of 32 turkeys died suddenly with peri-renal haemorrhage syndrome. They found that splenomegaly, pulmonary congestion and hypertrophic cardiopathy, were also associated in these turkeys. Microscopically there were moderate to marked acute passive congestion found in tissue sections of kidneys and spleen.

Ruff *et al.* (1992) studied the characterisation of the toxicity of the mycotoxin (aflatoxin, ochratoxin and T-2 toxin) in

Japanese quail. Toxin (OA) administration increased kidney weight of Bubwhite quails.

Singh *et al.* (1992) reported mild to moderate loss in activities of mucopolysaccharide, adenosine triphosphatase, succinic dehydrogenase and lactic dehydrogenase, glucose 6-phosphatase and increase in reaction of lipids in hepatocytes Von-Kupffer cells and renal epithelium in the different aflatoxin/ochratoxin treated groups of chicks.

Puette and Crowell (1993) conducted histologic and morphometric examination of avian glomeruli from normal and swollen kidneys of broilers at slaughter houses.

Maruyama *et al.* (1994) reported about infectivity to *Toxocara canis* larvae from Japanese quails in mice. The mice infected from larvae did not show any clinical sign but the larvae were found in the kidneys of infected mice.

Kono and Kumagai (1995) reported low microsomal activity in quail compared with the hamsters during in-vitro microsome medicated aflatoxin-B DNA binding and its inhibition by cytosol of various organs of the hamsters and quails. This study indicated a very small contribution of the lung and kidney microsomes to the activation of B_1 in birds.

Mishra (1995) observed marked vascular engorgement, focal haemorrhage and mild degeneration of hepatocytes in the liver and degeneration of tubular epithelium of kidneys upto 20 days of his experiment in chickens which were fed aflatoxin @ 1.5 ppm in mash.

Bata *et al.* (1996) reported swelling and yellow colouration of liver with haemorrhages on its surface, swelling of kidneys, hydropericardium and acute intestinal catarrh during aflatoxicosis in poultry.

Zaky *et al.* (1998) reported necrosis, swelling, vacuolisation and proliferation of bile duct epithelium in the liver, hyperaemia of glomeruli and intestinal blood capillaries and degenerative changes in the epithelial cells of proximal tubules of kidneys. Further they reported testicular degeneration in testes, smaller bursal follicles and fewer medullary lymphocytes in the bursa of fabricius in the broiler chickens fed aflatoxin @ 85 μg/Kg of feed for five days.

Lixiamin *et al.* (1998) reported that kidney of chicks from a quail fed high calcium (Ca: 3. 9%) high protein (44.0%) appeared edematous. There were uric acid salts deposits on the renal surface and in sections. The ureters were expanded and full of white uric acid salt deposits. Microscopic examination showed that glomeruli were swollen and the epithelial cells of the proximal and distal convoluted tubules were swollen and degenerated. Electron microscopy showed

that the epithelial cells of the proximal convoluted tubules were shortened, swollen and broken, the epithelial cells of the distal convoluted tubules had and expanded mitochandrion with a number of vacuoles and a serrated nucleus. Their results showed that uric acid salt deposition could be caused by both high calcium and high protein diets.

Nakamur *et al.* (1998) reported systematic amyloidosis in laying Japanese quail. The affected birds showed decreased in egg production, anorexia, white diarrhoea and sub-cutaneous abscess of head. Amyloid deposits were found in different organs such as spleen, liver, heart, lung and gastrointestinal tract.

Tsai *et al.* (1998) reported that out-break of adenoviral infection occurred in quails. Birds less than 3 weeks old showed depression, ruffled feathers, diarrhoea and high mortality. Histological examination of 18 quails revealed basophillic intranuclear inclusion bodies mainly in the digestive tract and rarely in the liver, kidney, nasal epithelium, conjunctiva and columnar epithelial cells within the mucosa of the bursa of fabricius.

DISEASES OF KIDNEYS OF OTHER BIRDS

Although kidney diseases of poultry are responsible for considerable mortality and production losses, they are among the most neglected areas in avian pathology. For example, in his classic book on poultry disease Zurn (1882) devotes no more than 350 words

to urinary affections and few modern text books do more than mention them none deal adequately with the subject.

In human medicine the importance of renal disease has been recognised for centuries; entire institutes are now devoted to the study of nephrology. The complexities of renal structure and function have always fascinated scientists and the ancient anatomists were so taken with the marvels of the kidney that they called it the 'viscus elegantissimus', the most elegant of organs (Kahn, 1939). The bird's kidney is no less fascinating and yet it is neglected. Few would consider themselves experts in avian nephrology.

There are several reasons for this neglect. Firstly, there is economic priority. In the days when poultry flocks were ravaged by major infections the comparatively few deaths due to incipient renal disease were unimportant and often hardly noticed. Secondly, it is possible that many poultry pathologists are not fully conversant with the microscopic structure of the bird's kidney. It is astonishing that even today post-mortem diagnosis of poultry diseases often relies entirely on gross examination with only bacteriological back-up because of insufficient expertise in histopathology. But the third and most important reason is that we do not adequately understand the nephropathies of poultry and lack a competent classification of renal diseases. This is largely because there is a total absence of reliable clinical information.

Often the first indication of kidney disease is found at autopsy and the lesions may then be so advanced that one cannot draw reliable conclusions retrospectively about the cause or pathogenesis.

Generally, there is no experimental models for kidney diseases and, although a simple biopsy technique is available for fowls (Siller, 1959a). It is therefore difficult to build up a coherent pattern and any classification must be tentative. In poultry disease diagnosis the terms nephritis and nephrosis are used in the loosest possible way and yet a uniform terminology is essential. Correct nomenclature must depend not only on the identification of the causal agent but also on the histological characterisation of the lesions, which latter, because of its obvious complexities, is rarely awarded much attention.

STRUCTURE OF NORMAL KIDNEY

The two large kidneys, lying extraperitoneally deep in the recesses of the renal fossae, are each divided into three divisions, often incorrectly referred to as lobes. But the avian kidney is entirely made up of lobules (lobuli renales) which override the indistinct borders of the divisions and give its surface an irregular appearance, reminiscent of cerebral giri. Johnson (1979) provided an excellent description of the lobular organisation in various avian species. A single lobule consists of a large cortical (cortex renalis) and small

medullary (medulla renalis) region. The cortex is made up of the various segments of the nephrons (nephrona) so arranged that their glomeruli roughly form a "horse-shoe" pattern around the central vein, itself a branch of the efferent vein of the renal portal system. Only the nephrons associated with the juxtamedullary glomeruli are of the "mammalian" type and have loops (Ansa nephroni) extending into the medulla like the loops of Henle. The other nephrons are of the "reptilian" type and are confined entirely to the cortical region.

The avian glomerulus is similar to its mammalian counterpart but it is smaller and has a simpler system of capillary loops arranged around the central core of mesangial cells (mesangium). The bird also has a juxtaglomerular apparatus (complexus juxtaglomerularis).

The various segments of the nephron do not differ substantially from those of mammals. The tall epithelial cells of the PCT have a distinct brush border of microvilli which instantly differentiates this segment from the smaller distal convoluted tubules (DCT) (tubuli convobuti distales). The collecting tubules (CT) (pars conjugens) are also small but easily recognised by their mucin production. They link with the perilobular collecting ducts (CD) (tubuli colligentes) that continue into the medullary tract. The CD are characterised by their size and the fact that the membrane separating neighbouring cells is very distinct. They also secrete mucus as does the ureter and its branches.

Incidence of Renal Disease

There are many publications on disease incidence in the fowl. They indicate the importance of renal disease, which was the fourth most common diagnosis among the 8,603 autopsies of Goss (1940), who saw nephritis and gout in 15% of cases and subsequently Siller (1959b) recorded nephritis in the same flock at more than twice the incidence (30%), probably because the latter survey was based on histological diagnosis. Hicks (1958) stated that during 1952-53 29.6% of pullet mortality was due to nephritis. Dudley *et al.* (1941) rated the frequency of urinary disease at only 5-6%.

In more recent total mortality surveys on broiler breeder flocks Jones *et al.* (1978) observed kidney lesions in 9.5% of females that died or were killed, while in the small number of males available the incidence was in the region of 1.3%. In a mortality survey on 41 caged layer flocks Randall *et al.* (1977) found primary renal disease in 20% of all dead birds and Blaxland *et al.* (1980) reported that in some laying flocks more than half the deaths were attributable to urolithiasis.

Hemsley (1965) studying broiler mortality in 14 flocks and a total of 100,000 birds listed no renal diseases other than three cases of unilateral agencies. This is an interesting contrast to Jackson *et al.* (1972) who calculated that 2.3% of losses among their 70,000

broilers was due to visceral gout and 1.4% to nephrosis, presumably an infection with IB virus. Brigden and Riddell (1975) found that the incidence of gout fluctuated from 1.6% to 50% in their flocks, but the excessively high figure was believed due, not to IB nephritis, but to failure of water supply in one group. Although the study of Blaxland and Borland (1977) was carried out at two Investigation Centres (Norwich and Cambrdige), they reported a 6% incidence of nephrosis from only Norwich.

It is clear from these studies that adult laying birds are much more prone to kidney disease and with the passage of time the character of the lesions in these birds appears to have changed from pullet disease or pyelonephritis some years ago (Hicks, 1958).

Vascular Changes

In fowls the renal arteries and their branches are not often involved in pathological processes. Atherosclerosis which is common, especially in older birds, does not usually involve the kidney vessels to any extent (Siller, 1961).

Medial thickening of the smaller arteries of the kidney is common in glomerulonephritis of the fowl (Siller, 1959c), a condition in which there is intimal calcification.

Visceral Urate Deposition

The deposition of monosodium urate crystals on various organs occurs not infrequently in fowl and other birds and constitutes what is generally referred to as visceral gout.

In birds uric acid accounts for around 80% of the urinary nitrogen (Sykes, 1971) and it is eliminated largely by active tubular secretion (Shannon, 1938). The site of urate transport has not been determined in the avian kidney, nor it known whether both types of nephrons participate in urate secretion, but is likely to occur in the PCT as it does in mammals and reptiles (Dantzler, 1978). In man not all urate is excreted by the kidney and other routes are of considerable importance. In the fowl, however, no such extrarenal excretion was detected following the ingestion of high activity Curic acid (Martindale, 1976).

Articular Gout

Spontaneous articular gout, unlike the visceraly type, is relatively uncommon in poultry and, as in man, it appears to have a hereditary basis (Peterson *et al.*, 1971).

The condition is painful and acute attacks may alternate with periods of remission (Herth, 1849). Larcher (1884) gave an excellent, detailed description of the clinical signs. The gross lesions

are typical, usually consisting of soft swelling on the feet, especially around the metatarsophalangeal and interphalangeal joints. But other sites, such as the joints of the wings and vertebrae have been recorded (Larcher, 1884).

Nephrosis

Nephrosis, a term introduced into the medical vocabulary and hotly disputed for years, is now less commonly used in its original meaning in human medicine. It has been retained to designate the "nephrotic syndrome" (Lipoid nephrosis), a clinico-pathological complex not recognised in domestic poultry. In textbooks on Veterinary pathology the concept of nephrosis is retained as a morphological rather than a clinical entity and defined, as any degenerative, primarily non-inflammatory lesion of the kidney, from cloudy swelling to necrosis, whatever the cause. If the term nephrosis is to be used at all in poultry pathology it should be defined in that way.

Acute tubular necrosis following chemical poisoning or traumatic ischaemia has been studied in detail in man (Heptinstal, 1966) but no parallel exposition is available for the fowl. However, in view of its important role in the elimination of deleterious substance the avian kidney is equally vulnerable to the effects of many chemical toxins. In succumbs, as does the mammalian kidney, to tubular

degeneration, sometimes necrosis which, if severe enough, leads to acute renal failure. The basic renal histology in such cases differs little from that of man but in the bird there is one cardinal differentiating sign and that is visceral gout. For in the bird renal failure rapidly leads to hyperuricaemia and the more or less diffuse visceral deposition of monosodium urate.

Pacs (1959) claims to have produced visceral gout in laying hens on diets containing 20-40% protein. This is contrary to the general findings and it is probable that there was an underlying primary disease. Pryor and Woo (1964) have shown that high protein-high energy diets increase susceptibility to spontaneous nephritis. They did observe that there was a four-fold rise in the blood uric acid level of affected chicks.

There are no clinical or gross pathological features which can be considered pathognomonic of nephrosis in the fowl. At autopsy one may encounter enlargement of the kidneys and deviation from its normal colour but these findings are by no means constant. The only reliable diagnostic method is the histological examination and even this, as pointed out above, may be complicated by autolysis.

Infectious Disease

Enlargement of the kidneys has been reported in a number of common infectious diseases and, although histological evidence is often lacking, nephrosis is said to complicate some of

them, e.g. Newcastle disease, ornithosis, vibrio hepatitis, pasteurellosis and pullorum disease. Rhoades (1964) believed, however, that interstitial nephritis complicated pasteurellosis and Suganuma (1960) claimed that in pullorum disease too there was a secondary interstitial nephritis. Protozoan infections can also cause nephrosis in fowls, as shown by Soni and Cox (1974) in acute avian malaria and *Clostridium welchii* enterotoxin can cause tubular necrosis and visceral urate deposition on the pericardium and peritoneum (Nilo, 1976).

In the majority of these conditions the renal involvement is of minor importance and probably does not significantly influence the course of the primary disease.

Vitamin A Deficiency

In 1921, it has been reported an outbreak of a roup-like condition with kidney involvement and visceral urate deposits and recognised that this was due to some form of malnutrition which was identified it as vitamin A deficiency. It was subsequently confirmed the findings in fowls while investigating various nutritional aspects of vitamin A (Konstantinov, 1972).

Visceral urate deposits could be due to other causes and the accumulation in the ureter was terminal. Because of its greater requirement for vitamin A (weight for weight) the fowl was thought

to be more sensitive to A-avitaminosis than the rat. Young birds are used in most studies on the renal effect of vitamin A deficiency but later it was found that the majority of laying hens on such a diet also developed kidney lesions with renal and sometimes visceral urate deposits. Stoewsand and Scott (1959) reported plasma urate levels of 4.5-9 mg%, while Henk (1966) stated that there was a gradual rise between the first and seventh weeks and that birds with 22 mg% were very sick and those with 30 mg% never survived. Scott (1961) believed that in poults but not chicks the blood uric acid level could be used as a reliable indication of the severity of the deficiency. He was of the opinion that the presence of visceral gout indicated a disturbance of protein metabolism.

There are few detailed pathological studies of the renal lesions in either experimental or spontaneous avitaminosis A in the fowl.

The most detailed and comprehensively illustrated account of the renal lesions in vitamin A deficiency was given by Bokori (1966) who observed "renal gout" in 14 of the 15 birds fed a vitamin deficient diet. Only in four cases were the renal lesions complicated by visceral gout and two of these were classed as only mild.

The characteristic histological renal lesions are dilatation and impaction of the collecting ducts in the medulla with cell debris, inflammatory cells and urates. This is accompanied by severe interstitial fibrosis and compression of other medullary components. In the cortical tissue there is hyperaemia and areas of tubular with mainly mononuclear inflammatory cells, debris, urate crystals and some hyaline casts. Typical tophi are also encountered interstitially.

Occasionally some of the surface tubules situated immediately below the peritoneal covering are found not only impacted with urates but also ruptured so that crystals discharge below the "capsule". Urate crystals are found on the epicardium, in the liver and myocardium as previously described in visceral gout (Siller, 1962).

Konstantinov (1970) showed that even before lesions were recognisable in kidney of vitamin A-deficient birds, severe changes had taken place in the ureters consisting of metaplasia of the normally double-layered epithelium to a keratinising stratified squamous type. A comparable metaplasia into multilayered epithelium also affected the collecting ducts. Later it was shown by Konstantinov (1972) that the excessive keratin could form an obstructing plug in the lower part of the ureter and that this could be the cause of the uratic diathesis.

The ureter is probably the true site of the primary lesion because it is well known that vitamin A deficiency causes keratinisation of epithelia in many parts of the body including the urinary tract (Moore, 1960). The "caseous whitish material" found in the ureters and their branches was undoubtedly a mass of keratin. While this can cause a simple obstruction of urine flow, vitamin A deficiency may also contribute to the precipitation of urates, not only in the ureter and its branches but also in the collecting tubules, through its effect on secretion of mucin (De Luca *et al.*, 1970). Porter (1966) has shown that mucoid substances of mammalian urine can maintain urates in solution at concentrations where they would otherwise precipitate and McNabb *et al.*, (1973) believed that, since the mammalian mucoids are of the same type as those of birds, a most important function of the rich mucin production of the avian collecting duct system is to prevent premature population of urates.

Renal calculi were produced experimentally in Vitamin A deficient rats but there is little evidence, according to Heptinstal (1966) that this is an important factor in stone formation of man. Although fowls are prone to urolithiasis stone formation has not been reported in this species in vitamin A deficiency.

A shortage of vitamin A in the diet has thus a direct effect on the ureter and collecting duct system, causing hyperkeratinisation and reduced mucin production. All other renal lesions, including

tubular dilatation and necrosis, tophus formation and interstitial fibrosis can be explained as secondary manifestations to the obstruction of the ureter.

NEPHRITIS

Nephritis of fowls was invariably secondary to nutritional errors, infectious or parasitic diseases or poisoning. Few would disagree, since most possibilities have been covered but it is an over simplification of the true situation and probably results from the fact that sometimes, even today, it is not uncommon for a diagnostic of "nephritis" to be made simply when at autopsy a deviation is observed in kidney size or colour. Rarely are such diagnoses supported by histological examination and it is little wonder, therefore, that such confusion exists in the classification of the avian nephritides.

However, in principle the classification used in mammalian nephritis can be applied in the fowl but it is difficult to elucidate the course of a particular disease and to identify the pathological characteristics of its various stages when no adequate clinical information is available.

Interstitial Nephritis

Contrary to the situation in man, where glomerulonephritis predominates, interstitial nephritis is the most

common form of inflammatory kidney disease in domestic mammals. In the fowl however, interstitial nephritis was believed to be rare (Siller, 1962) even though one of the earliest histological descriptions of avian renal disease concerned an outbreak of acute interstitial nephritis of unknown aetiology (Semmer, 1992) in which there was marked swelling of the kidneys, interstitial infiltration by inflammatory cells and a degree of tubular degeneration without deposition of urate crystals.

Chronic interstitial nephritis was observed in spirochaetosis, by Fletcher and Maas (1962) in fowl cholera and is reported from time to time a coincidental finding in other disease (Sevoian *et al.*, 1958) but it appears to be most frequently associated with virus infections.

Infectious Bronchitis Nephritis

It is nearly 20 years since the important observation was made by Winterfield and Hitchner (1962) that the kidneys may be involved in infections with certain strains, the so called nephrotropic strains, of infectious bronchitis virus (IBV). Winterfield and Hitchner selected the term "nephrosis" to stress the fact that both inflammatory and degenerative renal changes occur concurrently. However, nephritis-nephrosis was an unfortunate choice because this clumsy term has become entrenched in the literature and given rise to

confusion. Subsequent authors have opted for different version generally without recourse to a histopathological assessment of the nature of the lesions : Cumming (1963) spoke of infectious avian nephrosis, Hirai and Shimakura (1971) simply of nephrosis, Newton and Simmons (1963) preferred avian nephritis Minarik *et al.* (1967) infectious nephritis, while Julian and Willis (1969) considered "nephrosis-nephritis to be more bronchitis nephrosis of infectious bronchitis nephrosis (Cumming, 1971).

Neoplasia

Tumours of the kidney are not uncommon in the fowl (Guillon and Chouroulinkov, 1964). Among the primary renal neoplasms Campbell (1969) included non-metastasising adenocarcinomas and he described how upon experimental infection the embryonic renal tissue found in the kidneys of young chickens could give rise to clear cell adenomata with erythroleukosis virus (Carr, 1956) and to papilliform adenomas with osteopetrosis virus (Campbell *et al.*, 1964).

In one study, 16% of broiler tumours were nephroblastomas (Campbell and Appleby, 1966), the most common primary tumour found in the kidney of the fowl. These growths vary in size and appearance, they are often cystic and usually unilateral. According to Campbell (1969) they are embryonal in origin, arising

from the metanephric blastema. Since, therefore, they stem from mesoderm, Campbell expressed surprise that they can give rise to mesenchymal and epithelial. Feldman and Olson (1962) saw the nephroblastoma as originating from multipotential nephrogenic cells. At any rate the histological appearance of such other tumours sometimes reported in the kidney of the fowl are : Lipoma, myxosarcoma, histocytic cell sarcoma (Campbell, 1943), neurofibroma and tentoma (Campbell and Appleby, 1966).

Many other primary tumours like ovarian adenocarcinomas, granulosa-cell and Brenner tumours, oviduct and liver cell carcinomas can metastasise to the kidney (Campbell, 1969).

*****

CHAPTER 3

Materials and Methods

MATERIALS AND METHODS

The materials used in the present study consisted of kidneys of naturally dead Japanese quails (*Coturnix coturnix japonica*) of different age group and sex. The materials were collected from Central Poultry Farm and privately owned poultry farms in and around Patna and some other sources. The collection also included post-mortem examination of quails conducted at Bihar Veterinary College, Patna. The number of naturally dead Japanese quails examined are given in Table - 1.

Table – 1 : *showing total number of birds examined grossly*

Central Poultry farm, Patna	Private owned Poultry farms in and around Patna	Other sources (P.M. rooms)	Total
187	63	52	302

COLLECTION OF MATERIALS

302 dead quails were used in the present study. The dead birds were placed on the post-mortem table and Post-mortem examinations were conducted. During Post-mortem examinations, pieces of kidneys showing gross lesions such as hyperaemia, granulomatous, haemorrhagic and other lesions were collected and kept in sterile containers taking all aseptic precautions.

The following points were kept in mind during collection of specimens :-

1. Change in colour of kidneys.
2. Abnormalities in shape and size of kidneys.
3. Consistency of kidneys.
4. Presence of any abscess on kidney surface.
5. Presence of cyst etc.

After gross examination of renal specimens, the colour and consistency of oozing exudate were also noted. The other outer visible surfaces were examined for any abnormalities in shape and size. Pieces of 127 pairs of kidneys showing alterations were collected and preserved in the 10 percent formal saline solution for further processing and histopathological examination.

In the beginning, collected kidneys were incised and impression smears were made on clean glass slides. These impression smears were fixed and stained by different staining methods to detect bacteria and other microorganisms including fungus if present.

HISTOPATHOLOGICAL EXAMINATION

For histopathological examination, 0.5 cm thick tissue pieces of kidney lesions were collected and preserved in 10 percent formal saline solution.

Preparation of Stained Tissue Sections

It included the steps like fixing, embedding, section cutting, staining and mounting of the stained sections.

Fixing :-

It was done to stop the tissue autolysis and also to obtain the hardening of the pieces of the kidneys. Pieces of the kidney tissues (not more that 0.5 to 1 cm thick) were immersed for the sake of preservation in the following reagents :

a) 10 percent formalin. Tissue of kidneys were preserved in aqueous solution of formalin (10 percent) for 12 to 24 hours.

b) Absolute alcohol or methylated spirit.

Some kidney tissues were preserved in absolute alcohol. To stain the glycogen in tissue, the kidney tissues were preserved in absolute alcohol soon after collection of the kidney specimens.

Fixed tissues were washed thoroughly in running tap water for 12 hours or over night. Later, these tissues were dehydrated in ascending grades of ethyl alcohol, cleared in several changes of xylol and finally transferred for paraffin embedding (melting point of paraffin 58^0 - 60^0 C). The temperature of paraffin bath was maintained at 60^0 C. Three changes in melting paraffin were done to

ensure perfect infiltration of paraffin into the tissues. Then blocks were prepared by embedding the tissue in paraffin.

Paraffin sections were cut at 5-6 microns in thickness with the help of microtome and ribbons procured were allowed to spread in the water bath. The sections were lifted on clean slides which were previously smeared with Mayer's Glycerine egg albumin and dried in electric drier to remove water and fix the sections on the slide. These tissue sections were stained by Haematoxylin and Eosin (H & E) and other staining techniques.

For Haematoxylin and Eosin staining, tissue sections were deparaffinised by passing it in two changes of xylol and brought to water level by passing it into descending grades of alcohol and finally into the distilled water.

Then sections were stained with Mayer's haematoxylin and counter stained by 1.0 percent alcoholic solution of eosin as a routine stain.

For demonstration and isolation of special structures, abnormally present or developed due to tissue reaction during any infection, infestation and diseased conditions, the sections were stained with different special stains which are as follows :

1. Van-Giesson method (Luna, 1968).

   - Connective tissue

2. Ziehl-Neelsen Corbol Fuschin technique (Luna, 1968).

   - Acid fast organism

3. Von Kossa method (Culling, 1974).

   - Calcium

4. Brown and Brenn method (Luna, 1968)

   - Gram-positive and gram-negative bacteria.

*****

Chapter 4

Results

RESULTS

In the present study a total number of 302 naturally dead Japanese quail (*Coturnix coturnix japonica*) of both sexes and of all age groups were grossly examined for various pathological abnormalities in kidney. 127 Quail had shown alteration in their kidneys, which were collected from the naturally dead quail from Central Poultry Farm Patna, some private owned poultry farm and other sources.

For examination of various kidney affections in dead quails, a systematic post-mortem were conducted and examined. The kidneys showing apparent gross lesions were preserved in sterile container containing 10% formal saline solution. Gross pathological abnormalities were recorded before preservation. The kidney sections were stained by routine haematoxylin and eosin and some other staining methods and the result of this study were summarised in Table 2 and 3.

HISTOPATHOLOGICAL EXAMINATION

Apart from routine H & E staining technique other techniques applied to samples of kidney includes Van Gieson's connective tissue stain, Von Kossa's calcium stain and Brown and Brenn gram stain were also used.

On microscopical examination 127 specimen of kidneys revealed different types of pathological changes (Table 2 and 3).

Table – 2 : ***Statistical material of renal disease in quail.***

Sl. No.	Source	No. of quails examined	No. of Kidney showing gross lesions	Percentage of Positive
1.	Central Poultry Farm, Patna	250	112	44.8
2.	Private quail Farm	52	15	28.84
		302	127	42.05

Macroscopical Changes

In the diseases encountered in kidneys of dead quails revealed the lesions to the extent of putting them on to different groups.

Kidneys with greyish foci or patches

The kidneys showed such foci in 48 cases on the cut surface. A few kidneys were also enlarged moderately. The consistency of such kidney was somewhat soft.

Others

23 specimens of kidney were slightly swollen and somewhat greyish and when the kidneys were cut urates were noticed on the cut surfaces (figure 4 and 5). Ureters in such cases were also dilated and packed with such material.

Microscopical Changes

The following histopathological changes noticed in 127 specimens which are described with categorisation of lesions.

Renal Hyperaemia

Kidneys of 25 quails (19.6%) showed the changes of hyperaemia in which intertubular blood vessels and blood vessels of glomeruli were found engorged with blood with numerous nucleated erythrocytes (Figure-6). Lining of epithelium of tubules of medulla showed mild changes of degeneration in which parenchymatous degeneration was prominent. Cytoplasm of affected cells had become granular appearance. Changes of hyperaemia were more prominent in the cortex than medullary region of affected kidneys. Hyperaemic

changes were seen in both kidneys of 14 quails whereas rest 11 quails had shown changes of hyperaemia in only one kidney (Figure-7). Other kidney did not show the changes of hyperaemia.

Renal Haemorrhage

Kidneys of 31 quails (24.4%) had shown the changes of haemorrhages. Nucleated red blood cells were found in large number in the parenchyma of cortex and medulla of affected kidneys. some affected kidneys showed generalised haemorrhages in which blood cells were found in large areas of kidneys where as other kidneys showed changes of focal haemorrhages, (Figure-8 & 9) or around glomeruli. Due to infiltration of large number of erythrocytes, lining epithelium of tubules showed the changes of pressure atrophy associated with mild degenerative changes near the haemorrhage.

Nephritis

48 quails (37.7%) had shown changes of different types of nephritis which are as follows

Nephrosis

The most commonly and severely affected segment of affected kidneys were the proximal convoluted tubules and histological changes encountered were those of parenchymatous degeneration in various stages (Figure-10). Tubular epithelial cells

were swollen and often separated from one another by intercellular spaces. Occasionally they were detached from basement membrane. Fatty degenerative changes were also seen in some places (Figure – 11). Changes of necrosis were also seen in epithelial cells of some of the tubules. The lumens of such necrotic tubules were occluded by disquamated cells (Figure –12). Changes of nephrosis were seen in 23 quails.

Acute Interstitial Nephritis

Kidneys of 20 quails had shown the changes of acute interstitial nephrites. Inflammatory cells were found infiltrated in the interstitial tissues between the tubules (Figure – 13). The inflammatory cells were made up of heterophils, eosinophils associated with nucleated red blood cells. Diffuse infiltration of leucocytes was seen in kidneys of 5 quails. Focal interstitial nephritis were seen in kidneys of 12 quails. In diffuse infiltration, leucocytes were found accumulated in vast areas of kidneys (Figure-14). Cortex and medulla were equally affected. In focal type of nephritis, inflammatory cells were found infiltrated between the tubules of few areas of kidneys. This change was mostly confined in cortical areas of kidneys. Changes of hyperaemia were also seen in these affected kidneys. This changes was mostly confined in cortical areas of kidneys. Changes of hyperaemia were also seen in these affected

kidneys. Intertubular blood vessels were found dilated and were filled with excess of blood (Figure – 15). At many places, normal parenchyma were replaced by inflammatory cells. Epithelium of surviving tubules were swollen and hypertrophied.

Chronic Interstitial Nephritis

Kidneys of only 3 quails had shown the changes of chronic interstitial nephritis in which there was thickening of interstitial tissues with proliferation of fibrous connective tissue (Figure-16). This change was seen at both cortex and medullary regions of kidneys. Inflammatory cells were also seen present in the interstitial septa. These cells were mostly made up of monocytes and lymphocytes (Figure – 17) replacing some of the tubules. Some of the intertubular blood vessels showed the changes of midial thickening. There was changes of atrophy of tubules near the lesions.

Suppurative Nephritis

Two quails had shown the presence of abscesses in their kidneys. These small abscess contained yellow colour pus. Tissue sections of these affected kidneys showed the changes of suppurative nephritis. Large number of hetrophils and red blood cells were found accumulated replacing normal tubules in the lesions (Figure – 18).

Cysts

Grossly kidneys of 4 quails were apparently normal except they were mildly swollen. On histological examination, sections of these kidneys showed the presence of one or more cysts in the medullary regions (Figure – 19). These cysts were lined by single layer of cells and fibrous connective tissues. Due to presence of cysts, surrounding normal tissues of kidneys showed the changes of pressure atrophy and degenerative changes of lining epithelium of tubules. There was focal desquamation of epithelium from basal layer of tubules. Lumen of affected tubules showed the presence of desquamated necrosed epithelium.

Changes in blood vessels of kidneys

Blood vessels of affected kidneys had shown two types of alteration, in acute nephritis, intertubular veins were highly dilated. Majority of these blood vessels were engorged and filled with excess of blood. Similar changes of hyperaemia were present in the blood vessels of glomeruli of kidneys showing acute inflammation. These blood vessels also contained excess blood.

In chronic nephritis, wall of some of the inter tubular blood vessels were highly thickened. There was medial fibrosis of these blood vessels (Figure-20).

*****

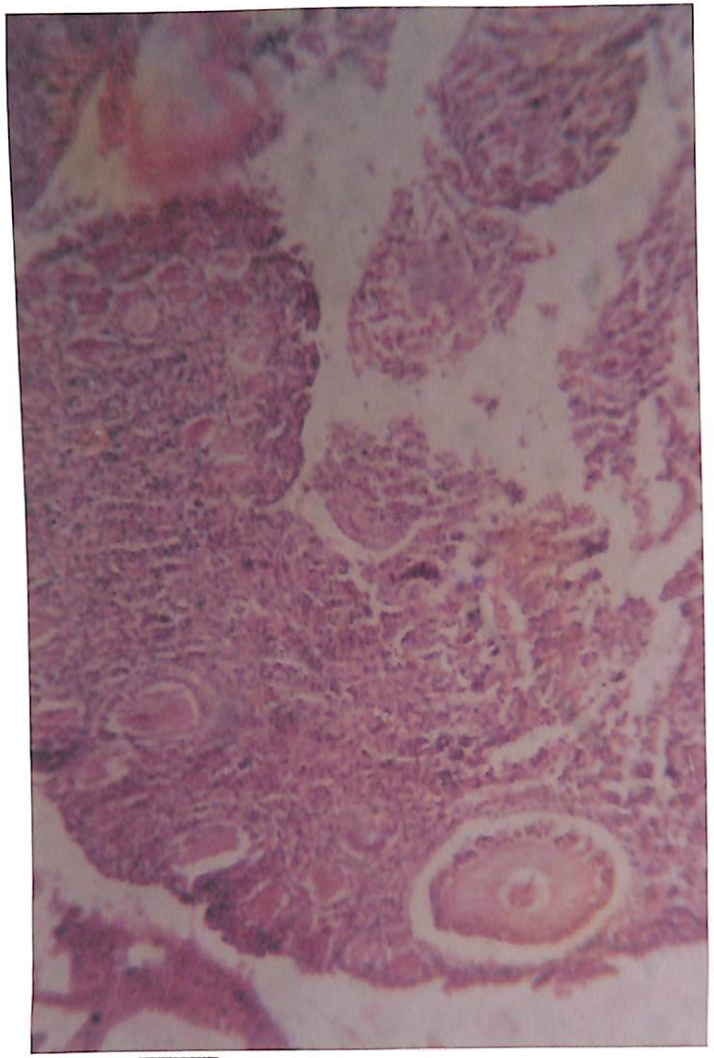

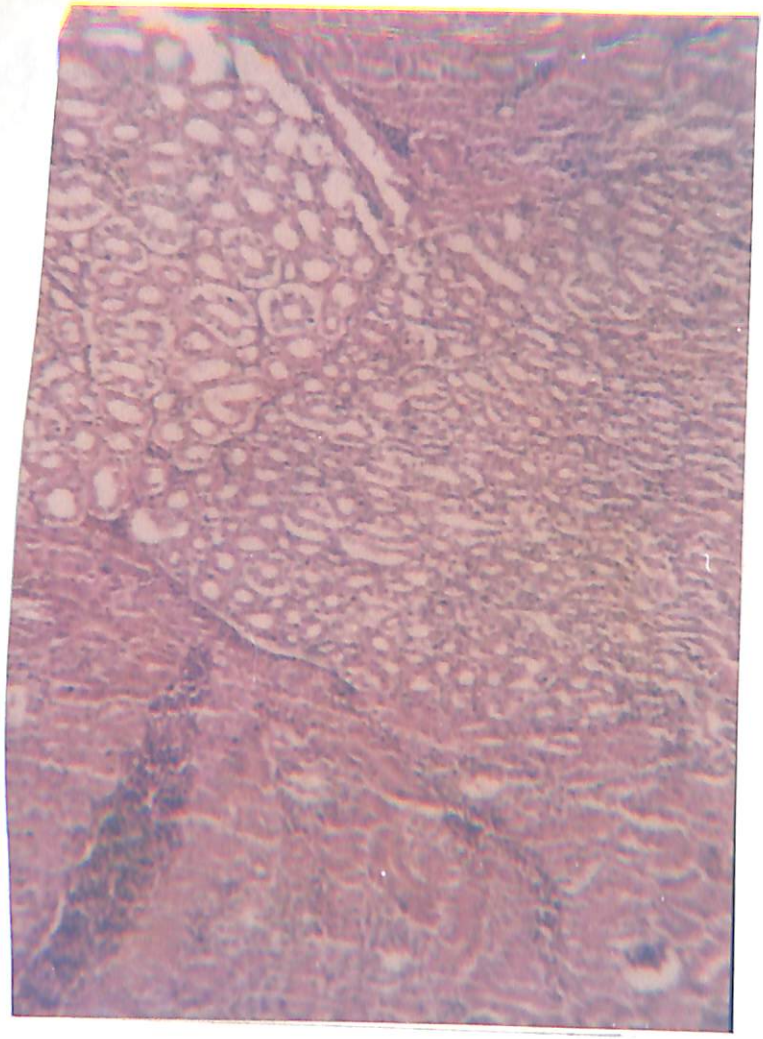

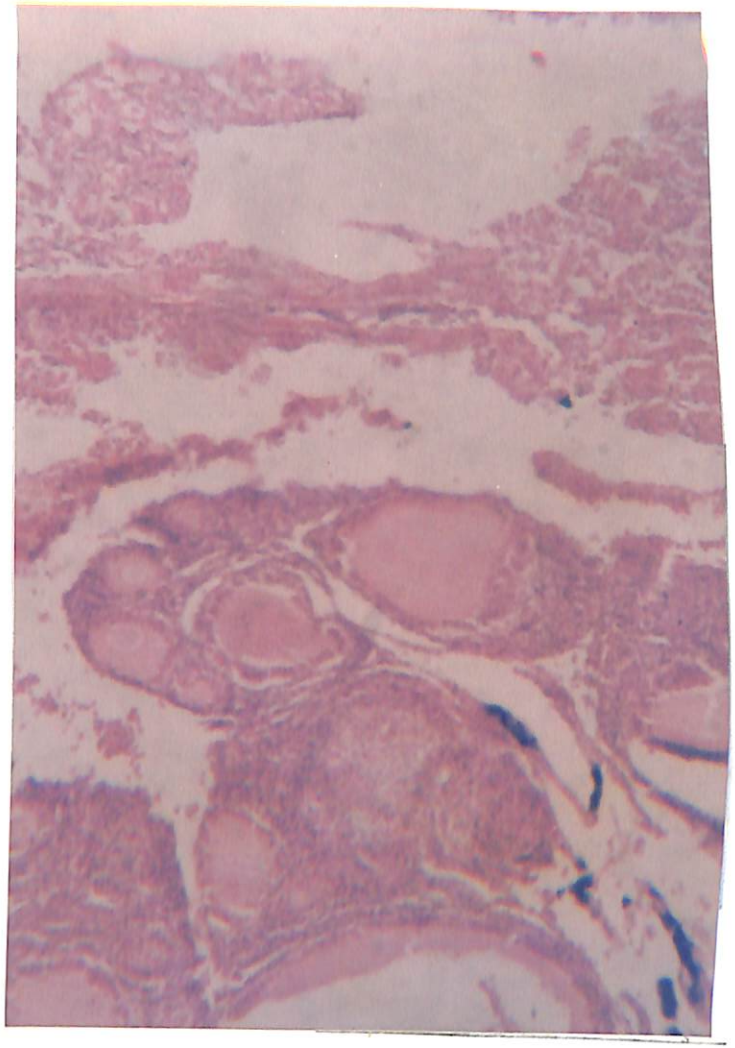

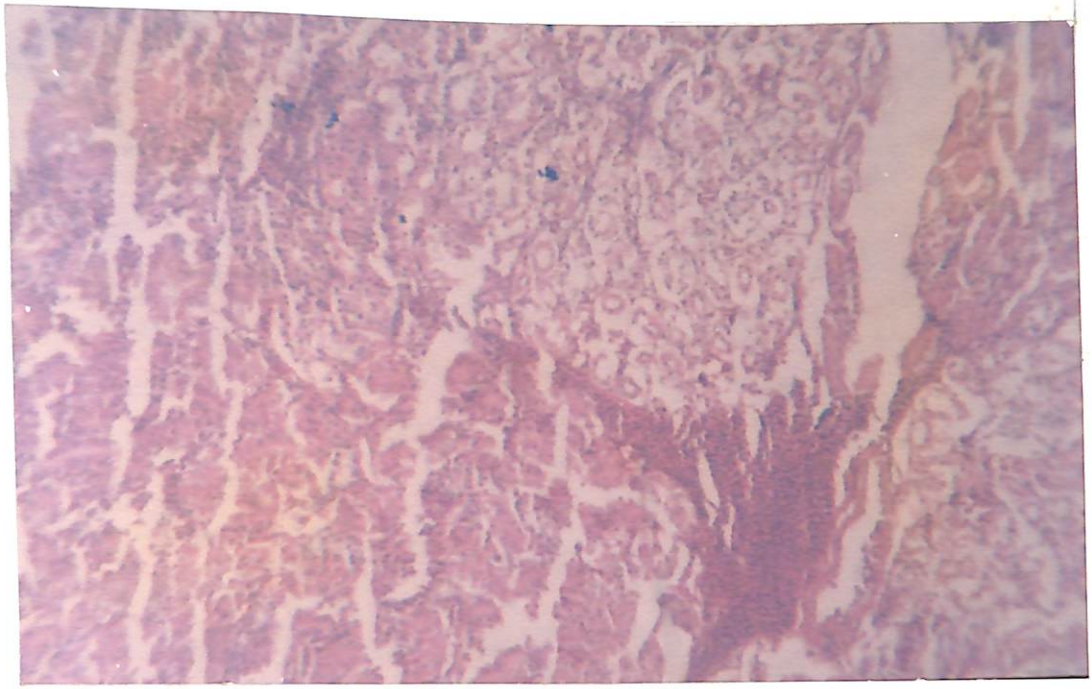

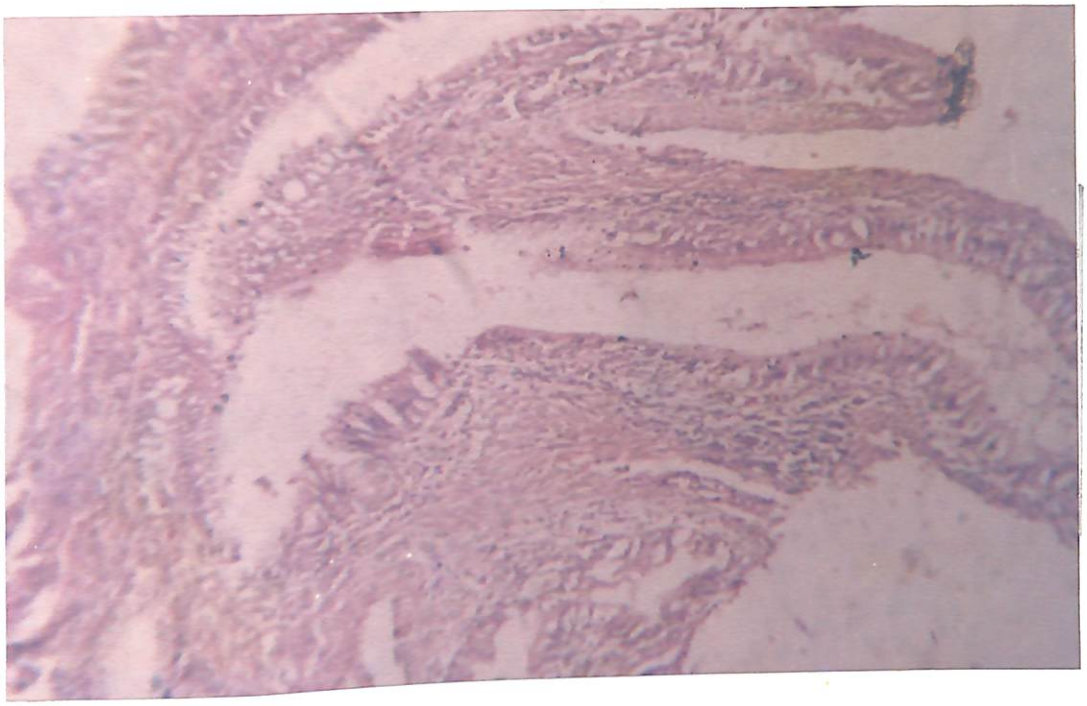

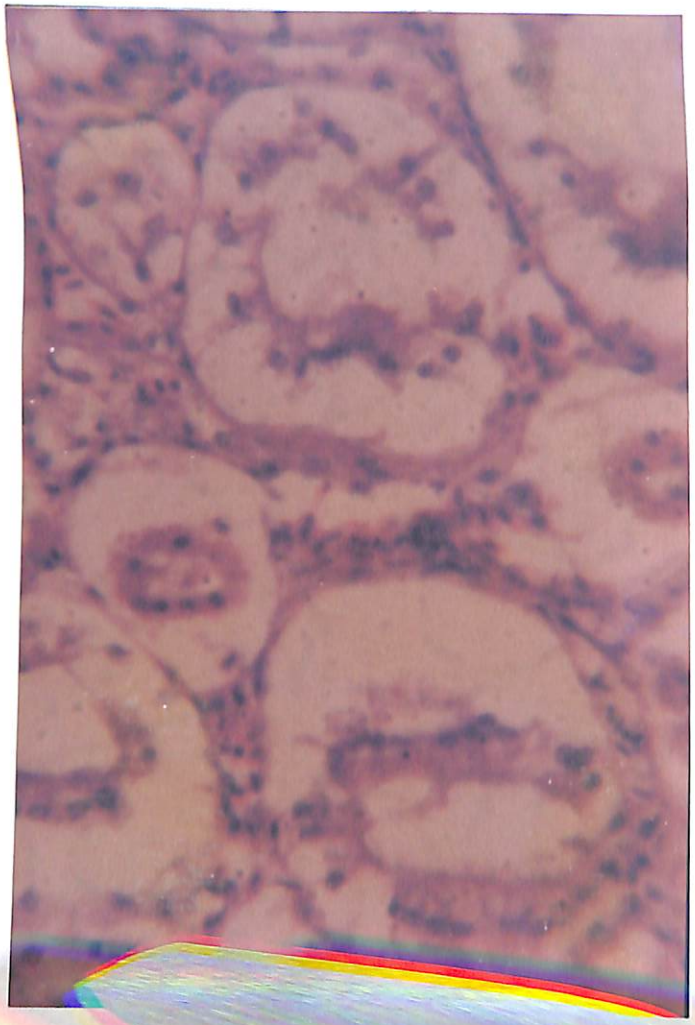

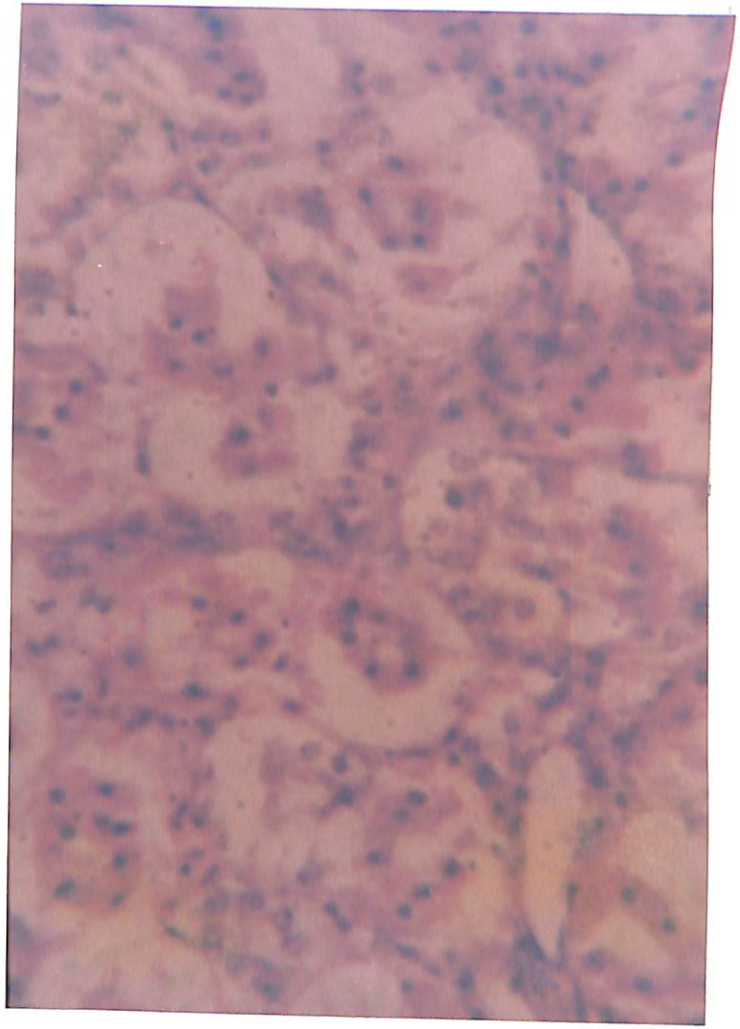

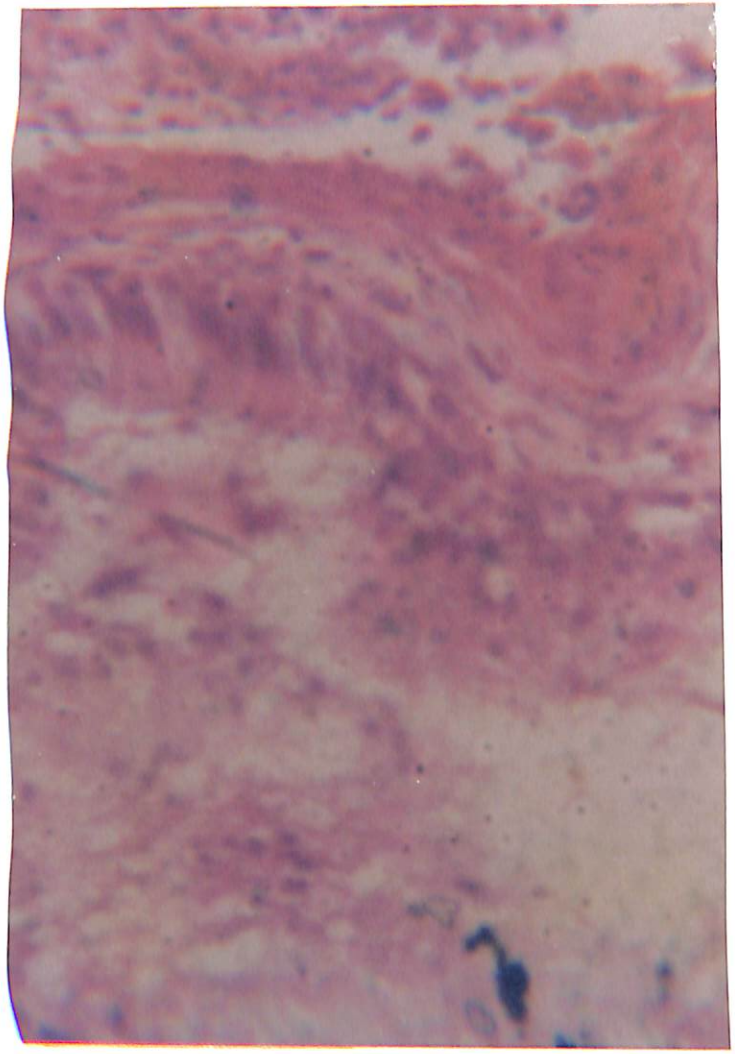

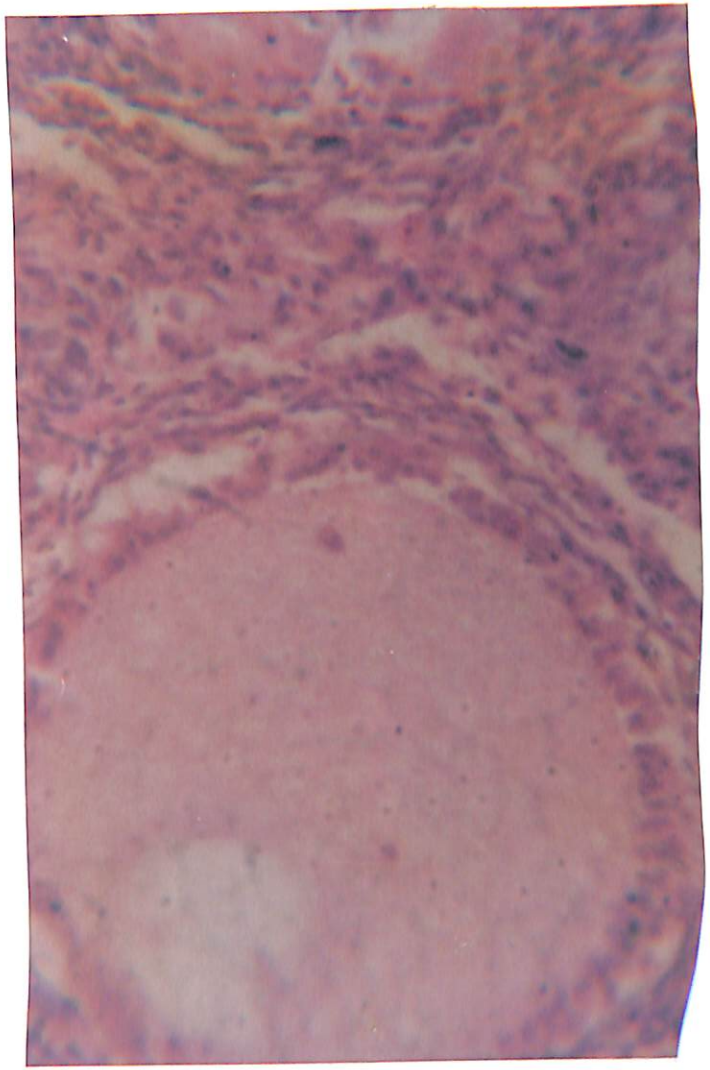

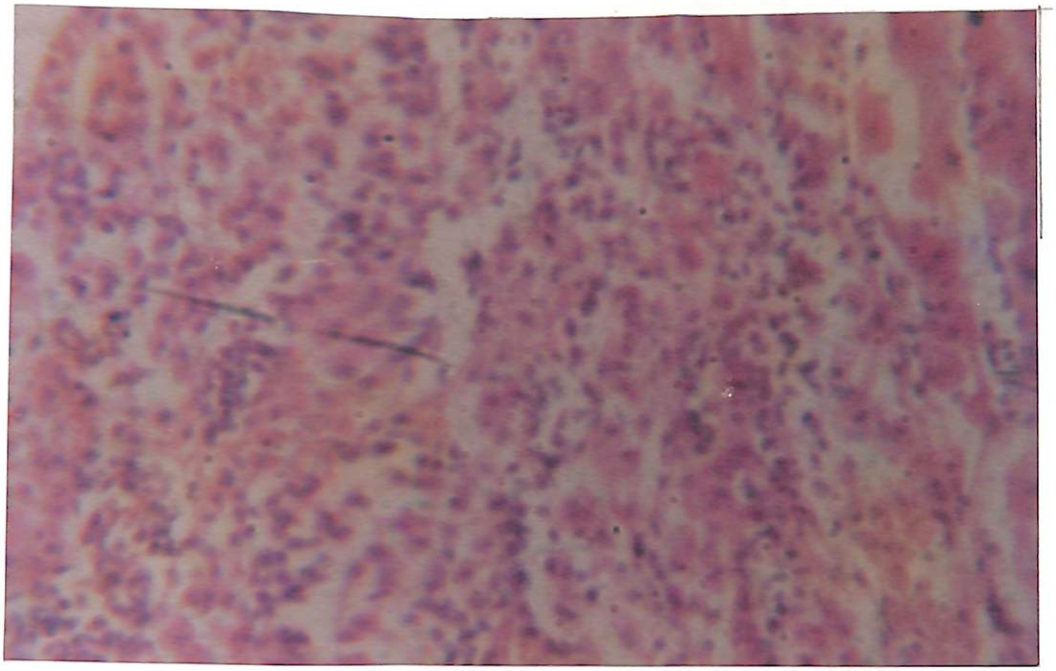

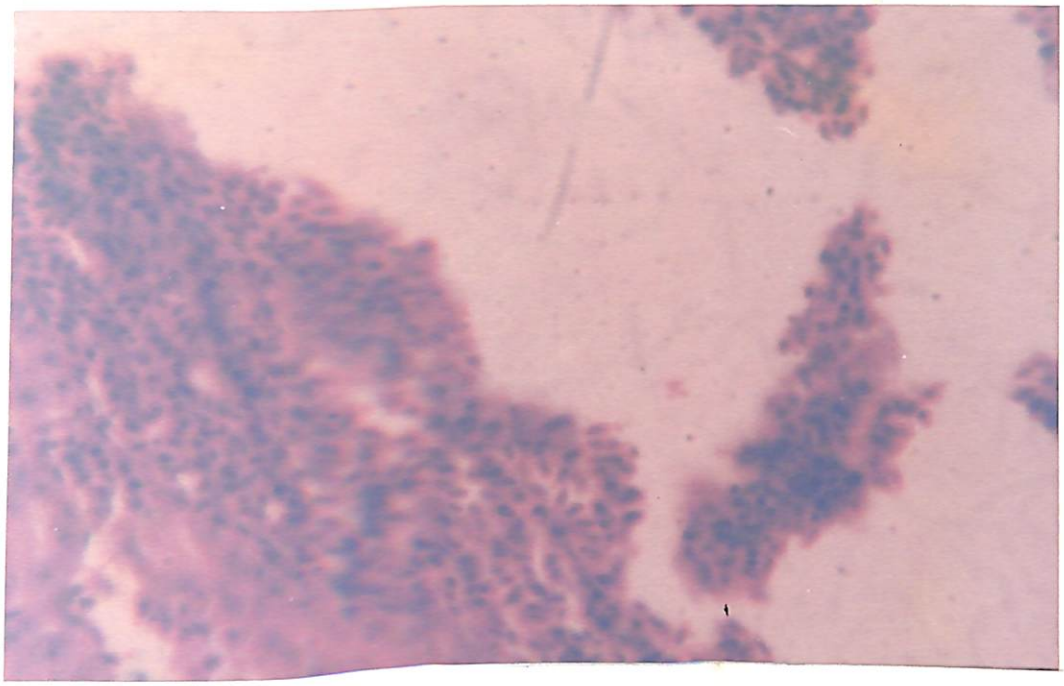

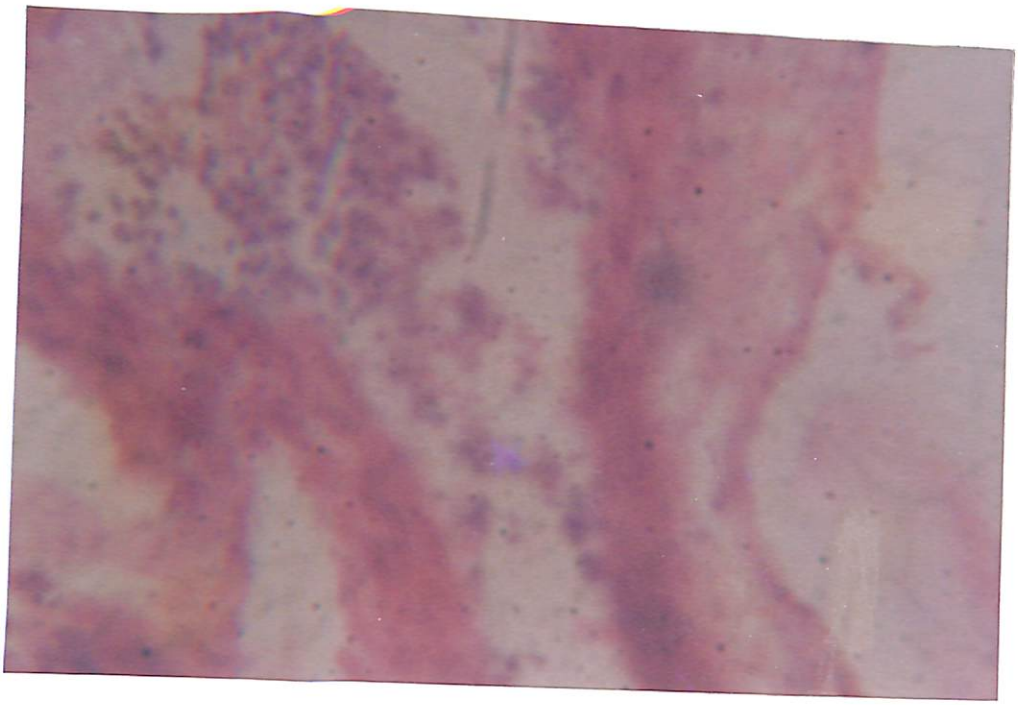

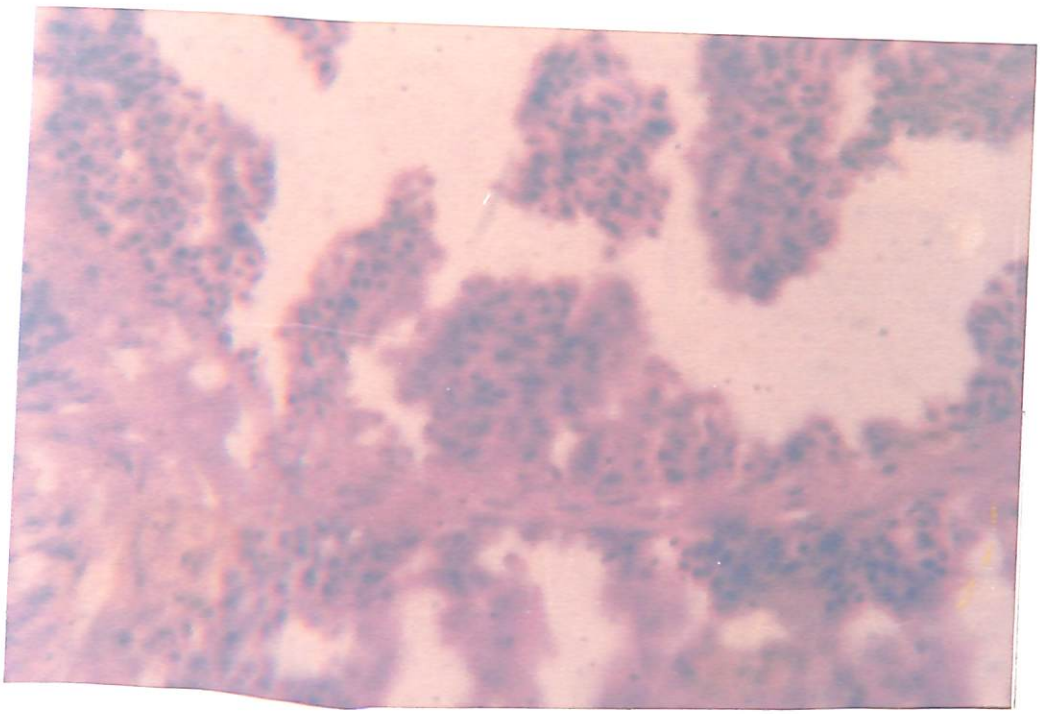

CHAPTER 5

Discussion

DISCUSSION

Japanese quail (*Coturnix coturnix japonica*) belong to class Aves, family Phasianidae and genus coturnix. They are hardy and easy to handle, that is why it has occupied a unique place in avian research throughout world. Because of similarity to chicken in several aspects, quails have been used as pilot animals for pathological, nutritional and physiological studies.

In the present study, materials have been taken from naturally dead Japanese quails in and around Patna, irrespective of their age, sex and health status. A total of 302 Japanese quails were examined in which kidneys of 127 quails had shown gross abnormalities.

On perusal of the available literature, it was found that information on the pathological conditions of the kidneys of quails are scanty. Similar is the case of poultry, although kidney diseases of poultry are responsible for considerable mortality and production losses, they are among the most neglected areas in avian Pathology. (Siller, 1971).

In human medicine, the importance of renal disease has been recognised for centuries, several works have been done in study

of human nephrology. In ancient, the anatomist had called the kidney as "Viscus elegantissimus", the most elegant of organs (Kahn, 1939). Some systemic works have been carried out on the renal diseases of cattle and buffaloes but it is neglected in birds. There are several reasons for this neglect. Firstly, there is economic priority. In the days when poultry flocks were ravaged with renal diseases, they are sacrificed. Secondly, it is possible that only a few deaths occurred due to renal disease which are important and often hardly noticed. Secondly, microscopic structure of bird's kidney is somewhat complex which needs expertise in histopathology in diagnosis. There is also lack of competent classification of renal diseases (Johnson, 1979).

In the present study, kidneys of 127 quails had shown gross abnormalities. Hypereamia, haemorrhage, nephrosis, nephritis, cysts and changes in blood vessels were important pathological conditions recorded in these quails. The percentage of these conditions are nephritis (37.7%) renal hyperaemia (19.6%) haemorrhages (24.4%), cysts (4.82%). Incidence of renal diseases of fowl have been reported by many workers. Goss (1940) reported nephritis and gout in 15% cases of dead birds. Greenwood and Blyth (1948) found 13% nephritis in fowls but Siller in 1959b reported the incidence of nephritis in the same flock at more than twice that incidence of 30%. This high incidence of nephritis is due to the fact

his survey was based on histological diagnosis. Hicks (1958) ed that during 1952-53 study, 29.6% of pullet mortality was due to hritis. Similarly, Dudley *et al.* (1941) and Blaxland (1977) reported 6% renal diseases in fowls. In the present study, 37.7% Japanese ails had shown different types of nephritis, which is higher idence. This difference is due to all previous reports are subject to rtain degree of selection and do not present the true picture. All the me time, Hicks (1958) stated that adult laying birds are much more rone to kidney disease and with the passage of time, the character of sion in these birds appears to have changed from pullet disease or yelonephritis.

During the present study, 25 quails had shown the changes of renal hypraemia which comes to 19.6%. Grossly affected kidneys were swollen and red in colour. Microscopically, intertubular veins and vessels of glomeruli were found dilated and engorged with blood. Hyperaemic changes were present in both kidneys of affected quails. Sinha *et al.* (1987) and Vegad and Katiyar (1995) had studied in detail the experimentally induced inflammation in chicken. They reported that chemical mediators are responsible for dilatation of blood vessels. Renal hyperaemia in the present study might be due to action of histamine and other chemicals acted on the blood vessels causing dilatation and congestion. These chemicals might be released

due to action of some infection. Neumann *et al.* (1973) reported that venous congestion and active hyperemia are common in many infectious diseases of fowl which is complicated with renal haemarrhages. In 1968, Gratzl and Kohler mentioned bacterial emboli in the glomerular capillaries in erysipelas infection but infarcts which are common and sometimes very extensive in mammals following embolism and thrombosis, appear not to occur in fowls, probably because of dual blood supply.

Out of 127 kidneys, 31 quails kidneys (24.4 percent) showed haemarrhages which are lower than that reported by Carlson *et al.* (1974), Gangadharan *et al.* (1989) and Arshad *et al* (1992) to the extent of 12.3 percent, 10.7 percent and 17.77 percent respectively. Rohrer (1946) and Wilhelm (1957) reported that renal haemarrages occur due to infectious diseases.

In the present study, kidneys showed pin point haemorrhages. Some kidneys showed agonal haemorrhages with marked demarcation to non-haemarrhagic areas. Histologically, Bowmans capsule showed congested capillaries with some haemarrhages in the surrounding tissue. Blood vessels of interstitium were also congested with extravasation of nucleated erythrocytes at some places which are in agreement with the finding of Awadhiya *et al.* (1980), Sinha (1985).

Other important pathological condition encountered in present study was changes of nephritis which was recorded in 23 quails out of 127 quails. The most commonly and severely affected segment of affected kidneys in the present study were proximal convoluted tubules and histological changes encountered were those of parenchymatous degeneration. Tubular epithelium were swollen and separated from one another in intercellular spaces. In some cases, fatty changes and necrosis of lining epithelial cells were found with detachment of cells from basement membrane. Similar changes were described by Carlson *et al.* (1974).

Nephrosis, a term introduced into the medical vocabulary by Muller (1905) as cited by Siller (1961) and hotly disputed for years, is now less commonly used in its original meaning in human medicine. Now, it has been retained to designate as "Nephrotic syndrome" because it is a degenerative, primarily non-inflammatory lesion of kidneys, from cloudy swelling to necrosis of nephrons. (Siller, 1961). Acute tubular necrosis following chemical poisoning or traumatic ischemia had been studied in detail in man by Heptinstal in 1966 and in fowl it has been reported that it might be due to toxicity of any means. (Rhoades, 1964, Stone and Soares, 1976 and Huff *et al.* 1986). From the nature of lesions seen in present study in the kidneys of quails in absence of clinical history, nothing could be said definitely

regarding the causation of this condition but present findings are almost confirmity to other workers who founded some type of poisoning. So lesions might have occurred due to poisoning.

In the present study incidence of interstitial nephritis was recorded in 37.7 percent cases which is highest amongst other pathological conditions although Siller (1959) recorded 30% of nephitis in fowl where as Lorachelle *et al.* (1992) recorded only 13% nephitis in chickens.

The histopathological lesion of acute interstitial nephitis were characterized by infiltration of heterophils and monocytes in the interstitial tissues of kidneys without fibrosis. Intertubular blood vessels were dilated and showed the changes of hyperaemia. In chronic interstitial nephritis, interstitial tissues of kidneys showed proliferation of fibrous connective tissues. There were infiltration of lymphocytes, plasma cells and monocytes in between the tubules replacing some of the normal parenchyma. There was medial thickening of wall of some of the blood vessels. Similar changes were reported by Semmer (1892). It has been reported that these lesions are caused by bacterial infection or due to toxicity by Rhoades (1964) and Spirochaetosis by Fletcher and Maas (1962). In the present investigation, no bacterial microorganism could be identified in the lesions of acute interstitial nephritis. It is however suggested that

further investigations are required with collaboration of the bacteriological laboratories to determine the probable aetiological factor in the causation of these conditions. However, in principal, the classification used in mammalian nephritis can be applied in fowl but is difficult to elucidate the cause of particular disease and to identify the pathological characterisations of its various stages when no adequate clinical information are available.

*****

VETERINARY COLLEGE PATNA
12920
LIBRARY

Chapter 6

Summary and Conclusion

SUMMARY AND CONCLUSION

The present investigation was undertaken to study the incidence and nature of renal disorders in Japanese quail. The materials used in the present study consisted of kidneys of naturally dead Japanese quail (*Coturnix coturnix japonica*) of different age group and sex. The materials were collected from Central Poultry Farm and Privately owned poultry farms in and around Patna and some other sources. The collection also included postmortem examination of quails conducted at Bihar Veterinary College, Patna.

In the present study a total number of 302 naturally dead Japanese quail (*Coturnix coturnix japonica*) of both sexes and of all age groups were grossly examined for various pathological abnormalities in kidney. Out of this, 127 quails had shown alterations in their kidneys.

The following points were kept in mind during collection of specimens :-

1. Change in colour of kidneys.
2. Abnormalities in shape and size of kidneys.
3. Consistency of kidneys.
4. Presence of any abscess on kidney surface
5. Presence of cyst etc.

After gross examination of renal specimens, the colour and consistency of oozing exudate were also noted. The other visible surfaces were examined for any abnormalities in shape and size. Pieces of 127 kidneys showing alterations were collected and preserved in the 10 percent formal saline solution for further processing and histopathological examination.

In the beginning, collected kidneys were incised and impression smears were made on clean glass slides. These impression smears were fixed and stained by different staining procedures. These impression smears were fixed and stained by different staining methods to detect bacteria and other micro organism including fungus if present.

A total of 302 Japanese quail were examined in which kidneys of 127 quails had shown gross abnormalities.

For histopathological examination, 1 cm thick tissue pieces of kidney were collected from 127 kidneys having lesions and were preserved in 10 percent formal saline solution. After proper fixation, paraffin blocks and tissue sections were prepared by standard techniques. Tissue sections were stained with Haematoxylin and Eosin stain for routine examination. Special staining techniques were also adopted whenever needed.

Renal hyperaemia

Kidneys of 25 quails (19.6%) showed the changes of hyperaemia in which intertubular blood vessels and blood vessels of glomeruli were found engorged with blood with numerous nucleated erythrocytes. Changes of hyperaemia were more prominent in the cortex than medullary region of affected kidneys. Hyperaemic changes were seen in both kidneys of 14 quails whereas rest 11 quails had shown changes of hyperaemia in only one kidney.

Renal haemorrhage

Kidneys of 31 quails (24.4%) had shown the changes of haemorrhage. Nucleated red blood cells were found in large number in the parenchyma of cortex and medulla of affected kidneys. Some affected kidneys showed generalised haemorrhage in which blood cells were found in large areas of kidneys whereas other kidney showed changes of focal haemorrhages.

NEPHRITIS

48 quails (37.7%) had shown changes of different types of nephritis which are as follows :-

Nephrosis

The most commonly and severely affected segment of affected kidneys were the proximal convoluted tubules and

histological changes encountered were those of parenchymatous degeneration in various stages. Tubular epithelial cells were swollen and often separated from one another by intercellular space.

Acute Interstitial Nephritis

Kidneys of 20 quails had shown the changes of acute interstitial nephritis. Inflammatory cells were found infiltrated in the interstitial tissue between tubules. The inflammatory cells were made up of heterophils, eosinophils associated with nucleated red blood cells. Diffuse infiltration of leucocytes was seen in kidneys of 5 quails. Focal interstitial nephritis were seen in kidneys of 12 quails. In diffuse infiltration, leucocytes were found accumulated in vast areas of kidneys.

Chronic Interstitial Nephritis

Kidneys of only 3 quails had shown the changes of chronic interstitial nephritis in which there was thickening of interstitial tissues with proliferation of fibrous connective tissue. This change was seen at both cortex and medullary region of kidneys.

Suppurative Nephritis

Two quails had shown the presence of abscesses in their kidneys. These small abscesses contained yellow colour pus. Tissue sections of these affected kidneys showed the changes of suppurative

nephritis. Large number of heterophils and red blood cells were found accumulated replacing normal tubules in the lesions.

Cysts

Grossly kidneys of 4 quails were apparently normal except they were mildly swollen. On histological examination section of these kidneys showed the presence of one or more cysts in the medullary regions.

*****

Bibliography

BIBLIOGRAPHY

Agrawal, S. K. (1996). Paper published in World Poultry Congress, 3 : 704.

Ahuja, S.D. (1996). Quail husbandry, ICAR Publication, 47-48.

Arshad, S., Khan, M.Z., Siddique, M., Javed, M.T. and Khan, H.A. (1992). Clinico-pathological studies of experimentally induced mycotoxins in broiler chickens. *Pakistan Veterinary Journal*, **12 (4) :** 183-185.

Awadhiya, R. P., Vegad, J. L. and Kolte, G. N. (1980). A topographic study of increased vascular permeability in acute inflammatory reaction in the chicken skin. *Res. Vet. Sci.*, **29** : 203-210.

Balachandran, C and Ramakrishnan, R. (1987). An experimental study on the pathology of aflatoxicosis in broiler chicken. *Indian Veterinary Journal*, **64 (11):** 911-914.

r, A., Eisner, U., Montecuccoli, G. and Hurwitz, S. (1976). Regulation of intestinal calcium absorption in the laying quails independent of kidney vitamin D-hydroxylation. *Journal of Nutrition*. **106 (9) :** 1336-1342.

A., Vanyl, A., Glavit, R and Salyi. G. (1996). More important mycotoxicosis of poultry clinico-pathological Review Article. *Magyar-Allator-Vosok Lapja (Hungary)* **51 (7) :** 395-408.

Baumagartner, J., Csuka, J. and Kulisek, V. (1981). Effect of gamma radiation upon the reproductive performance of Japanese quail. *Archiv-fur-geflu-gelkunde*, **45 (1) :** 27-33.

Baumagartner, J. (1994). Japanese quail production : breeding and genetics. *World Poultry Science Journal*. **50 :** 227-235.

Blaxland, J. D. (1957). Poultry mortality today. Year Book of Poultry Association, Great Britain, p. 9-16.

Blaxland, J.D. and Borland, Edith, D. (1977). A survey of 'normal' broiler mortality in East Anglia. *Veterinary Record*, **101 :** 224-227.

Blaxland, J.D., Borland, Edith, D., Siller, W.G. and Martindale, I. (1980). An investigation of urolithiasis in flocks of laying fowls. *Avian Pathology*, **9** : 5-19.

Bokori, J. (1966). Gout in poultry. III. Production of gout by chemical damage to the kidney. *Acta Veterinaria. Academiae Scientiarum Hungarica*, **16** : 273-286.

Brigden, J.L. and Riddel, C. (1975). A survey of mortality in four broiler flocks in Western Canada. *Canadian Veterinary Journal*. **16 :** 194-200.

Brown, T. P. and Fletcher, O. J. (1985). Ultrastructural Postmortem changes in chickens kidneys at 27^0C. *Avian Diseases*, **30 (2)** : 370-380.

Bush, R.S. and Marguardt, R.R. (1978). Effects of starvation and molecular weight on the turnover of soluble proteins from five tissues of the Japanese quails. *Journal of Nutrition*, **108** : 2, 301-306.

Campbell, J.G. (1943). Histocytic and fibroplastic sarcoma (mixed cell sarcoma) in the domestic fowl. *Journal of Comparative Pathology and Therapeutics*. **53** : 323-328.

Campbell, J.G., Young, D.E. and Carr, J.G (1964). Soft tissue lesions and tumours associated with osteoporosis gallinarum virus. *Journal of Comparative Pathology*, **71** : 263-279.

Campbell, J. G. and Appleby, E.C. (1966). Tumours in young chickens bred for rapid growth (broiler chickens) : A study of 351 cases. *Journal of Pathology and Bacteriology,* **92** : 77-90.

Campbell, J.G. (1969). Tumours of the Fowl. Heineiman, London, p. 153-162.

Carlson, H.C., Seawright, G.L. and Pettit. J.R. (1974). Reticuloendotheliosis in Japanese quail. *Avian Pathology* B : No-3, 169-175.

Carr, J.G (1956). Kidney carcinomas of the fowl induced by the MH_2 reticuloendothelioma virus. *British Journal of Cancer*, **14** : 77-82.

Culling, C.F.A. (1974). Hand Book of Histopathological and Histochemical Technique 3rd Edition. Butterworths and Co. Ltd. London.

Cumming, R.B. (1963). The isolation of a virus from 'uraemia' infected chickens. *Australian Journal of Science*, **25** : 314.

Cumming, R.B. (1971). Infectious bronchitis nephrosis : proceedings of 19th World Veterinary Congress. Mexico City, **2** : 487-490.

Dafalla, R., Yagi, A.I. and Adam. S.E.I. (1987). Experimental aflatoxicosis in hybro-type chicks : Sequential changes in growth and serum constituents and histopathological changes. *Veterinary Human Toxicology*, **28 (3)** : 22-226.

Dantzler, W.H. (1978). Urate excretion in non-mammalian vertebrates. In: uric acid edited by W.N. Kelly and I.M. Weiner. Handbook of Experimental Pharmacology. Vol. **51** : 185-210. Springer, Berlin.

DeLuca, L., Schumacher, M and Wolf, G. (1970). Biosynthesis of a glucose containing glycopeptide from rat small intestine in normal and vitamin-A deficient conditions. *Biological Chemistry,* **245** : 4551-4558.

Dudley, F.J., Dobson, N. and Gordon, R.F. (1941). Mortality in egg-laying trials in Great Britain during the period 1929/37. *Veterinary Record*, **53** : 323-330.

Dutton, R.L., Kenzy, S.G. and Becker, W.A. (1973). Marek's disease in Japanese quail (*Coturnix coturnix japonica*). *Poultry Science,* **52** : No. 1, 139-143.

Feldman, W.H. and Olson, C. (1962). Neoplastic diseases of the chickens. In : Diseases of poultry edited by Biester, H.E. and Schwarte, L.H. 4th edition 690-694. Ames : Iowa State. University Press.

Fletcher, R.D. and Maas, H.J.L. (1962). Acute fowl cholera in a Connecticut chicken flock : Description of the isolation of *Pasteurella multocida. Tijdschrift voor Diergeneeskunde,* **87** : 1125-1128.

Fujimoto, Y., Mikami, T., Narita, M and Okada, K. (1975). Pathological studies of Marek's disease in Japanese quail. *Japanese Journal of Veterinary Reference,* **23** : 4, 119-124.

Gangadharan, B., Valsala, K.V., Maruyamma, K.I., Ramachandran, M., Gopalkrishna, N and Rajan, A. (1989). An analysis of mortality in Japanese quail. (*Coturnix coturnix japonica*). *Kerala Journal of Veterinary Science*, **20** : 44-49.

Goss, L.G. (1940). The incidence and classification of avian tumours. *Cornell Veterinarian*, **30** : 75-88.

Gratzl, E. and Köhler, H. (1968). Spezielle Pathologie and Therapie der Geflügelkrankheiten, p. 1038-1055. Stuttgart : Enke.

Grecnwood, W.B. and Blyth, J.S.S (1948). The problem of pullet mortality. Proceedings 8th World Poultry Congress, Copenhagen, **1** : 687-691.

Gromysz, K.K., Szubartonska, E., Sulikowska, J and Trocewicz, K. (1984). Tissue respiration in quail (*Coturnix coturnix japonica*). Under physiological condition and after poisoning with chlorfenvinphos. *Medycyna-Wateryraryjra*, **40** : 12, 721-724.

Guillon, J.C and Chouroulinkov, I. (1964). Les tumeurs renales chez le poulet. *Economie et Medecin Animales*, **5** : 238-274.

Hemsley, L.A. (1965). The causes of mortality in fourteen flocks of broiler chickens. *Veterinary Record*. **77** : 467-472.

Henk, F. (1966). Nierengicht bei Hühnerküken infolge von Vitamin-A-Mangel-Ernährung. *Wiener tierärztliche Monatsschrift*, **53** : 161-170.

Heptinstal, R.H. (1966). Pathology of the kidney. p. 372. Boston, Little, Brown and Co.

Herth, G.H. (1849). Beitrag zu den Krankheiten der vogel Magazin für die gesamte Thierheilkunde, **15** :99-116.

Hicks, A.F. (1958). Genetic resistance to uric nephritis in chickens. *Poultry Science*, **37** : 1289-1294.

Hirai, K. and Shimakura, S. (1971). Isolation and characteristics of avian nephrosis – inducing infectious bronchitis virus (Corona virus). *Japanese Journal of Veterinary Science,* **33** : 209-216.

Huff, W.E., Kubena, L.F., Harvey, R.B., Hagler, W.M.JR., Swanson, S.P., Philips, T.D. and Creger, C.R. (1986). Individual and combined effects of aflatoxin and deoxynivalenol (DON) in broiler chickens. *Poultry Science,* **65 (7)** : 1291-1298.

Huff, W.E., Harvey, R.B., Kubena, L.F. and Rottinghaus, G.E. (1988). Toxic synergism between aflatoxin and T-2 toxin in broiler chicken. *Poultry Science,* **67 (10)** : 1418-1423.

Imai, K., Yuasa, M., Kobayashi, S., Nakamur, K., Tsukamoto, K and Hihara, H. (1990). Isolation of Marek's disease virus from Japanese quail with lymphoproliferative diseases. *Avian Pathology.* **19** : 1, 119-129.

Jackson, C.A.W., Kingsten, D.J. and Hemsley, L.A. (1972). A total mortality survey of nine batches of broiler chickens. *Australian Veterinary Journal*, **48** : 481-487.

Johnson, O.W. (1979). Urinary organs. In: Form and Function in Birds, edited by King, A.S. and McLelland, J. Volume **I** : 183-235. London : Academic Press.

Jones, H.C.R., Randall, C.J. and Mills, C.P.J. (1978). A survey of mortality in three broiler breeder flocks. *Avian Pathology*, **6** : 149-170.

Julian, R.J. and Willis, N.G. (1969). The nephrosis- nephritis syndrome in chicken caused by Holts strain of infectious bronchitis virus. *Canadian Veterinary Journal,* **10** :18-19.

Kahn, F. (1939). Der Mensch. Bau und Function unseres Körpers allgemeinverständlich dargestellt. 2nd edition: 378, Zürich: Müller, A.

Kaul, L., and Pradhan, H.K. (1991). Immunopathology of Marek's disease in quails: Presence of antinuclear antibody and immune complex. *Veterinary Immunology and Immune-Pathology*. **28** : 1, 89-96.

Khare, M.L., Grun, J. and Adams, E.V. (1975). A transovarian transmission study of Marek's disease in Japanese quail. *Poultry Science*, **54** : 1953-1961.

Kono, M. and Kumagai, S. (1995). In vitro microsome mediated aflatoxin B_1 – DNA binding and its inhibition by cytosol of various organs of the hamster and quail. *Mycopathologia*, **32** : 2, 117-119.

Konstantinov, A. (1970). Morphological changes in the ureters as a cause of gout in chicken A-avitaminosis Compte Rendu de l'. *Academie Bulgare des Sciences*, **23** : 461-464.

Konstantinov, A. (1972). Morphological changes in the ureters of chickens with A-avitaminosis and their role in the development of gout. *Bulletin of the institute for General Pathology, Sofia*, **14** : 253-258.

Kupsh, C.C., Julian, R.J., Vall, V.E.O and Robinson, G. P. (1991). Renal damage induced by uranyl nitrate and oestradiol – 17 beta in Japanese quail and Wistar rats. *Avian Pathology,* **20** : 1, 25-34.

Larcher, M.O. (1884). Etude Sur la Goutte des oiseaux. *Bulletin et Memoires de la Societe Central de Medcin Veterinaire*, **11** : 37-55.

Larochelle, D., Morin, M., and Bernier, G. (1992). Sudden death in turkeys with perirenal haemorrhage: Pathological observations and possible pathogenesis of the disease, *Avian Diseases*, **36** : 114-124.

Lixiamin., Maoxian, D., Ligianyoung, W.J. (1998). Renal pathology of experimental uric acid salt deposition in chickens. *Chinese Veterinary Science*, **18 (4)** : 387-389.

Luna, L.G. (1968). Manual of Histochemical staining method of the Armed forces institute of Pathology, 3rd edition. Mcgraw Hill Book company. New York, Toronto, London.

Martindale, I. (1976). Renal urate synthesis in the fowl (*Gallus domesticus*). *Comparative Biochemistry and Physiology*. **S 3 A** : 389-391.

Maruyama, S., Yamamoto, K and Katsube, Y. (1994). Infectivity of Toxocara canis larvae from Japanese quails in mice. *Journal of Veterinary Medical Science*, **56** : 2, 389-401.

McNabb, F.M., Anne., McNabb, R.A. and Stevens, H.R. (1973). Renal mucoid in pigeons fed high and low protein diets. *Auk.*, **90** : 14 -18.

Minarik, P., Dyml, E and Petr, O. (1967). Infekcni nefritida drubeze. *Veterinarstvi*, **17** : 118-122.

Mishra, A.K. (1995). Pathology of experimental aflatoxicosis, and aspergillotic pneumonia in broiler chicken. M.V.Sc Thesis Deemed University, IVRI, Izatnagar. (U.P.)

Mohanty, P.K. and Verma, P.C. (1982). Japanese Quail-Some of its common diseases. *Poultry Guide*, **19 (11)** : 103-104.

Mollenhauer, H.H., Corrier, D.E., Huff, W.E., Kubena, L.F., Harvey, R.B and Droleskey, R.E. (1989). Ultrastructure of hepatic and renal lesions in chicken fed aflatoxin. *American Journal of Veterinary Research*, **50 (5) :** 771-777.

Moore, T. (1960). The pathology of vitamin-A deficiency. *Vitamins and Hormones*, **18** : 497-514.

Moorthy, A.S., Mahender, M., Rao, P.R. (1986). Pathology of acute experimental aflatoxicosis in chickens. *Indian Journal of Animal Science*, **55 (8)** : 629-632.

Müller, F. (1905). Morbus Brightii. *Verhandlungen der deutschen Gesellschaft für Pathologie*, **9** : 64-99.

Nakamur, K., Tanaka, H., Kodama, Y., Kubo, M. and Shibahara, T. (1998). Systemic amyloidosis in laying Japanese quail. *Avian diseases*, **42** : 1, 209-214.

Neumann, F., Dison, M.S., Klopper, U. and Nobel, T.A. (1973). Sporadic renal haemorrhage in turkeys, *Refuah Veterinarith*, **30** : 59-61.

Newton, L.G. and Simmons, G.C. (1963). Avian nephritis and uraemia. *Australian Veterinary Journal,* **39** : 135-139.

Nilo, L. (1976). The effect of enterotoxin of *Clostridium welchii (perfringens). Research in Veterinary Science*, **20** : 220-226.

Pacs, I. (1959). Visceral gout in fowls on high protein diet. *Mag. Allator Lapja.*, **14** : 44-47. (*Abstract Veterinary Bulletin*, **29** : 574.)

Peterson, D.W., Hamilton, W.H and Lilyblade, A.L. (1971) Hereditary susceptibility to dietary induction of gout in selected lines of chickens. *Journal of Nutrition*, **101 (7)** : 347-354.

Porter, P. (1966). Colloidal properties of urates in relation to calculus formation. *Research in Veterinary Science,* **7** : 128-137.

Pryor, W. and Woo, K.K. (1964). Relationship between protein energy levels and uraemia in chickens. *Australian Veterinary Journal*. **40** : 236-237.

Puette, M. and Crowell, W.A. (1993). Histologic and morphometric examination of Avian glomeruli from normal and swollen kidneys of broilers at slaughter. *Avian Diseases*, **37** : 874-877.

Randall, C.J., Blandford, T.B., Borland, Edith, D., Brooksbanks, N.H and Hall, S.A. (1977). A survey of mortality in 41 caged laying flocks. *Avian Pathology*, **6** : 149-170.

Rao, JR., Sharma, N.N., Iyer, P.K.R. and Sharma, A.K. (1990). Interaction between Eimeria uzura infection and aflatoxicosis in Japanese quail (*Coturnix coturnix japonica*). *Veterinary Parasitology*, **35** : 259-267.

Rhoades, K.R. (1964). The microscopic lesions of acute fowl cholera in mature chickens. *Avian Diseases*, **8** : 658-665.

Rohrer, H. (1946). Die Histopathologie der seit 1940 in Europa herrschenden geflügelpestahnlichen Virusseuche des geflügels. *Monatshefte der Veterinärmedizin*, **1** : 71-81.

Ruff, M.D., Huff, W.E. and Wilkins, G.C. (1992). Characterisation of the toxicity of the mycotoxins, aflatoxin, ochratoxin and T-2 toxin in game birds III. Bobwhite and Japanese quail. *Avian Diseases*, **36** : 1, 34-39.

Sah, R.L., Mall, M.P., Mohanty, G.C. (1983). Septicemic proteus infection in Japanese quail. *Avian Diseases*, **27** : 1, 296-300.

Scott, M.L. (1961). Neuere Untersuchungen auf dem Gebiet des vitamin A in der Geflügelernahrung. *Zentral blatt der Veterinarmedizin*, **8** : 830-832.

Seman, D.H., Catherman, DR., Matsui, T., Mayek, M.G., Batson, D.B. and Cantor, A.H. (1989). Metabolism of decoquinate in chickens and Japanese quail. *Poultry Science*. **68** : 5, 670-675.

Semmer, E. (1892). Uber chroniche interstitielle Nephritis mit Nierenschrumpfung (Morbus Brightü) bei Katzen und akute interstitielle Nephritis mit Nierenschwellung bei Hühnern. *Osterreichische Monatsschrift für Thierheilkunde*, **16** : 193-194.

Sevoian, R.W., Winterfield, R.W and Goldman, C.L. (1958). Avian infections hepatitis I. Clinical and Pathological manifestations. *Avian Diseases*, **2** : 3-39.

Shannon, J.A. (1938). The excretion of uric acid by chicks. *Journal of Cellular and Comparative Physiology*, **11** : 135-147.

Siller, W.G. (1959a). Disease investigation at the Poultry Research Centre. *Esso Farmer*, **10** : 16-19.

Siller, W.G. (1959b). Avian nephritis and visceral gout. *Lab. Investigation*, **8** : 1319-1346.

Siller, W.G (1959c). The pathology of avian glomerulonephritis. *Journal of Pathology and Bacteriology*. **78** :57-65.

Siller, W.G. (1961). Spontaneous atherosclerosis in the fowl. In : Comparative Atherosclerosis edited by Roberts, I.C. and Straus, R. p. 66-76. New York : Hoeber, Medical Division.

Siller, W.G. (1962). Studies on nephritis in the domestic fowl. *Research in Veterinary Science*, **5** : 323-331.

Siller, W.G. (1971). Structure of the kidney. In: Physiology and Biochemistry of the Domestic Fowl, edited by Bell, D.J. and Freeman, B.M. p. 197-231. London: Academic Press.

Singh, H., Singh, B., Roy, K.S. and Singh. Balwant. (1992). Histochemical studies on boiler chicken fed aflatoxin ochratocin inoculated with inclusion body hepatitis virus singly or in concurrence. Compendium on "Problems of emerging poultry diseases". 6-9th Aug, Madras.

Sinha, B. K., Vegad, J. L. and Awadhiya, R. P. (1987). Pathology of concanavalin – A induced cutaneous reaction in the chickens. *Research in Veterinary Science*, **42** : 365-372.

Sinha, B. K. (1985). Pathology of delayed cutaneous reactions in the chicken with special reference to basophil hypersensitivity. Ph.D. Thesis, Jawaharlal Nehru Krishi Vishwa Vidhyalaya, Jabalpur (M.P.).

Soni, J.L. and Cox. H.W. (1974). Pathogenesis of acute avian malaria. I. Immunologic reaction associated with anaemia., splenomegaly, and nephritis of acute Plasmodium gallinaceum infection in chickens. *American Journal of Tropical Medicine and Hygiene*, **23** : 577-585.

Stoewsand, G.S. and Scott, M.L. (1959). Further studies on the etiology of encephalomalacia and its similarity to the ataxia of Vit-A deficiency in chicks. *Poultry Science*, **38** : 1251.

tone, C.L. and Soares, J.H. Jr. (1976). The effect of dietary selenium level on lead toxicity in the Japanese quail. *Poultry Science*, **55** : 1, 341-349.

tone, C.L. Fox, M.R.S., Jones, A.L. and Mahaffey, K.R. (1977). Delta-amino levulenic indicator of lead exposure in Japanese Quail. *Poultry Science*, **56** : 174-181.

uganuma, Y. (1960). Histologic studies on serositis of pullorum disease. *Japanese Journal of Veterinary Science,* **22** : 175-182.

ykes, A.A. (1971). Formation and composition of urine. In: Physiology and Biochemistry of Domestic fowl edited by Bell, D.J. and Freeman, B.M., p. 233. London : Academic Press.

sai, S.S., Chang, T.C., Chang, G.N., Chern, R.S., Chen, M.S., Itakura, C. (1998). Naturally occurring adenovirus associated gastrointestinal lesions in quail. *Avian Pathology,* **27 (6)** : 641-643.

egad, J. L. and Katyar, A. K. (1995). The acute inflammatory response in the chickens. *Veterinary Bulletin*, **65** : 399-409.

ahab, A.M., A.H. (1990). Quail farming a profitable subsidiary occupations for Agriculturists. *Poultry Guide*, **12** : 30-42.

Wilhelm, A.M. (1957). Die Beteiligung der Niere am Krankheitsgeschehen bei verschiedenen Erkrankungen des Huhnes. Vet. Diss. Giessen.

Winterfield, R.W. and Hitchner, S.B. (1962). Etiology of an infectious nephritis-nephrosis syndrome of chickens. *American Journal of Veterinary Research*, **97** : 1273-1279.

Zaky, Z.M., Salem, D.A., El-Ballai, S.S and Meki, A.M. (1998). Effect of *Staphylococus aureus* protein-A and Freund's complete adjuvant on aflatoxin B toxicity in broilers. *Wiener-Tierar-Ztliche Monatsschrift.* **85 (2)** : 432-48.

Zurn, FA (1882). Die Krankheiten des Hausegeflugels, p. 163. Weimer : Voigt.

*****