



Birnaviridae

VMC 605: Systematic Animal Virology

Presented by

Dr Manoj Kumar

Assistant Professor

Department of Veterinary Microbiology

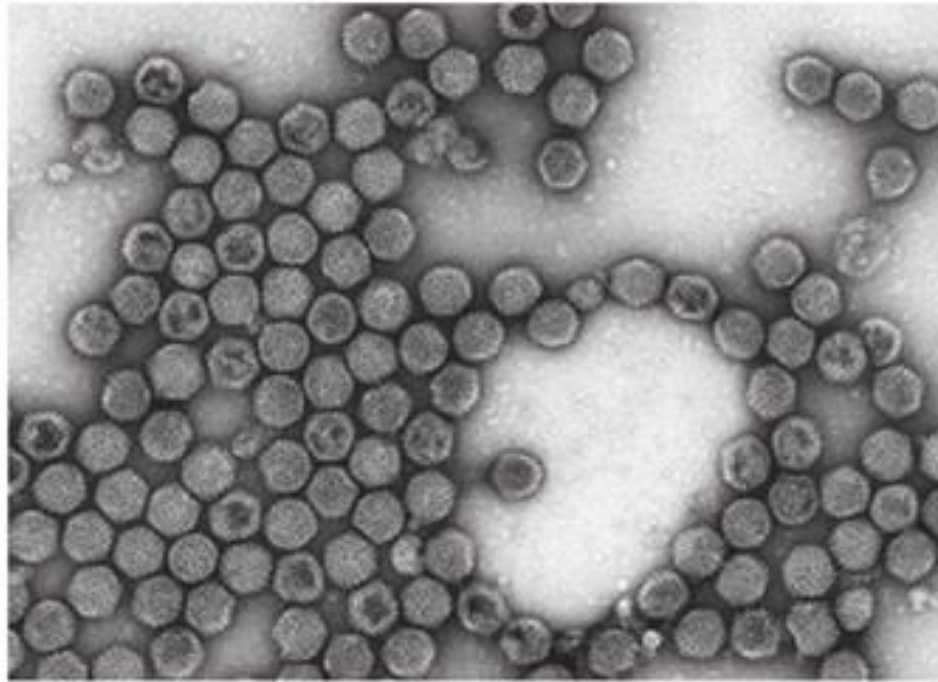
Bihar Veterinary College, Patna

Taxonomy

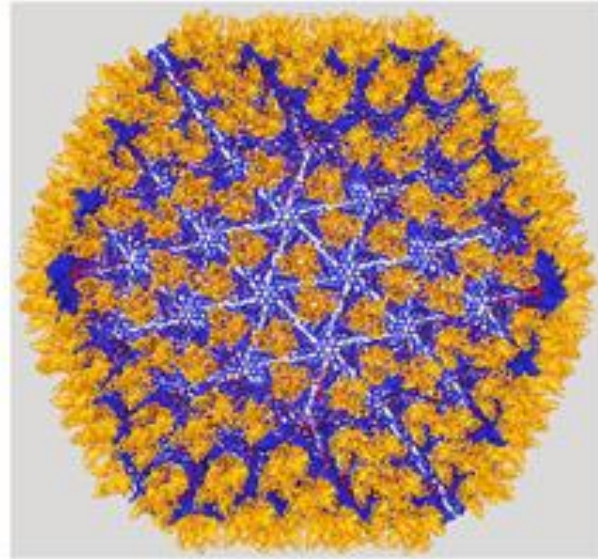
- Family: *Birnaviridae*.
- Genus: *Avibirnavirus*
- Species: *Infectious bursal disease virus*

IBDV

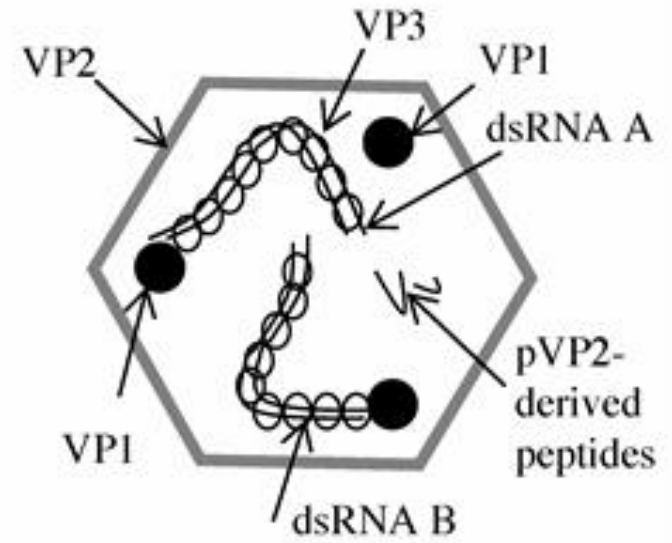
(A)



(B)



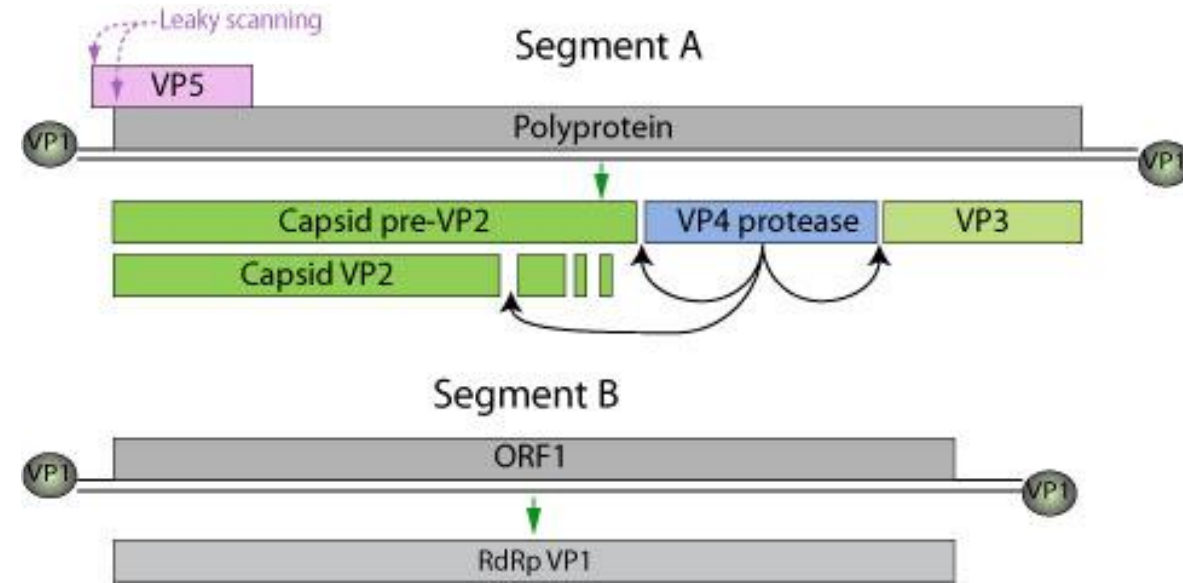
(C)



Family- *Birnaviridae*

• Morphology:

- Shape- Isometric
- Size- 60-70 nm
- Symmetry- Icosahedral; with T513 symmetry
- No. of capsomers- 32
- Genome- Bisegmented (Designated as A & B) , ds RNA; 5-6 kbp in size;
- Envelop – Absent
- Mol. Wt. – 3.82×10^6 dalton

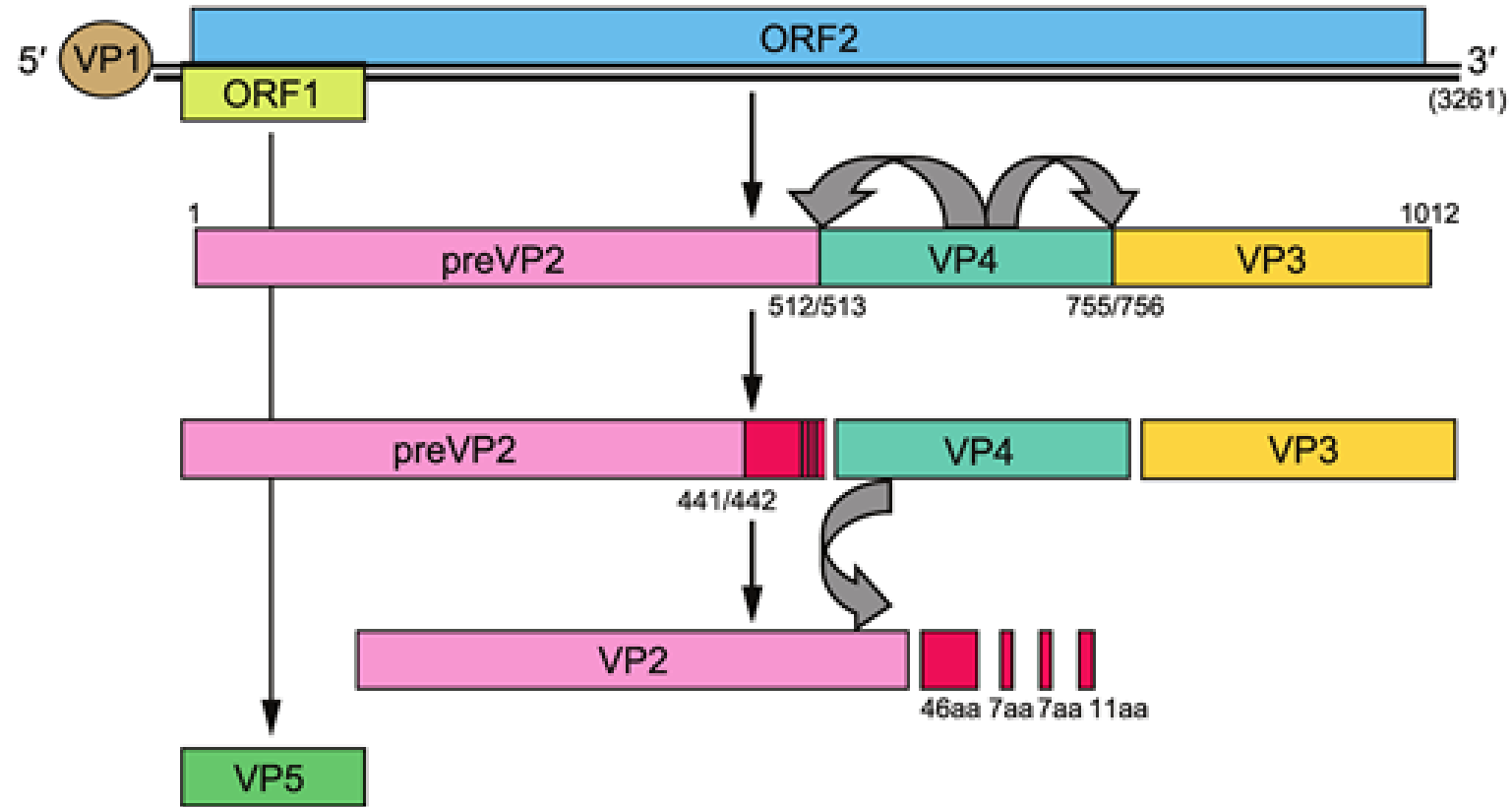


Genome: IBDV

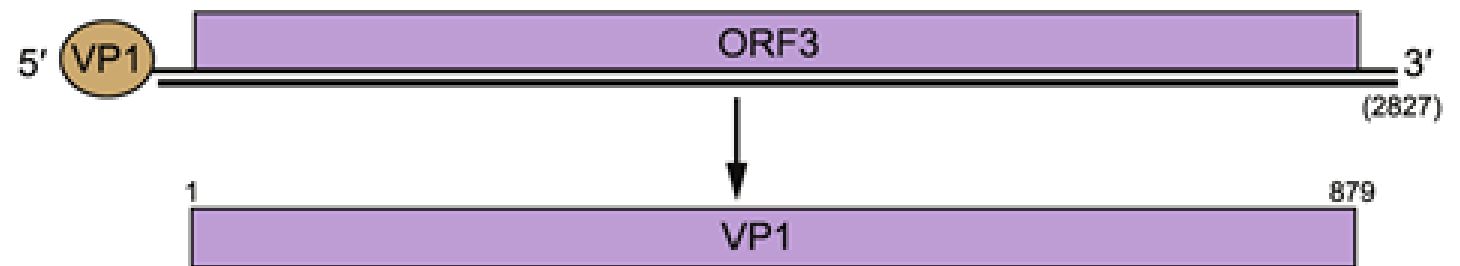
- Bisegmented linear dsRNA genome
- Segments are designated A and B and range from 2800 to 3400 kbp; encode for 5-6 proteins.
- Genome total size is about 6 kb.
- VP1 is found in a free form and covalently attached at the 5' genomic RNA end (VPg).

Infectious bursal disease virus, IBDV

Segment A



Segment B



Composition

- Five viral protein viz. VP1, VP2, VP3, VP4 & VP5
 - VP1- RNA dependent RNA polymerase; plays key role in encapsidation
 - VP2- Host protective antigen
 - VP3- Group specific antigen
 - VP4- Non structural polypeptide ,involves in auto processing
 - VP5 –Regulatory function of release & dissemination

Classification of IBDV

- **Strain classification:** Two serotypes are differentiated by virus neutralization test
 - a) Serotype 1 – infects chicken
 - b) Serotype 2 – infects turkey
- **Pathotypes:**
 - classical virulent IBDV (cvIBDV)
 - very virulent IBDV (vvIBDV)
 - antigenic variant IBDV (avIBDV)
 - attenuated IBDV (atIBDV)

Resistance:

- IBDV is resistant to
- heat & UV radiation
- Ether
- Chloroform
- phenol
- chloramines ,formaldehyde or glutaraldehyde is, however, effective against virus.
- survives at pH range of 2-13.

Replication:


- a) After oral infection or inhalation, the virus replicates primarily in lymphocytes and macrophages of gut associated tissues.
- b) Then virus travels to the bursa via the blood stream, where replication occurs
- c) A second and pronounced viraemia occurs with secondary replication in other


The Disease

- IBDV causes infectious bursal disease
- Viruses in the genus thus far infect only birds.
- IBDV causes an immunosuppressive disease in chickens by destruction of B lymphocytes in the bursa of Fabricius.

IBD was first reported by Albert S. Cosgrove in 1962 Gumboro County, USA, and thus eponym “Gumboro Disease” was given. He called the disease “Avian nephrosis” due to prominent kidney lesion

“Infectious bursal disease is an acute, highly contagious, infectious disease of poultry, characterized by sudden onset of depression in susceptible flock, prostration, ruffled feather, frequently watery or white diarrhoea and death”.

- 
- **Susceptibility** : Chicken up to 3- weeks of age are susceptible
 - **Carrier**: Recovered birds
 - **Transmission**: Highly contagious; virus survives in water, feed, & droppings up to 52 days.
 - Infection is through oro-faecal route.
 - **Pathogenicity**: IBDV is immunosuppressive in nature that causes damage through necrosis apoptosis & erosion of B-lymphocyte in bursa, resulting in suppression of humoral immune response

- 
- Incubation period: 4-days
 - Clinical sign:
 1. Sudden onset of depression in susceptible flock
 2. Ruffled feathers and trembling
 3. Frequently watery or white diarrhoea, soiled vent
 4. Reluctant to move, prostration & death

Diagnosis:

1. Clinical signs and symptoms

2. Post mortem examination:-

- a) Bursa of Fabricius appears turgid , oedematous, sometimes haemorrhagic and turns atrophic within 7 to 10 days.
- b) Splashed haemorrhages in breast & thigh muscle
- c) Dehydration & nephrosis with swollen kidney
- d) Ecchymotic haemorrhages on mucosa of proventriculus

3. Isolation and identification of virus

Specimen for virus isolation:

From live birds- Post slaughter sample of Bursa & spleen

From dead birds- Bursa & spleen are the tissues of choice, however, bursa is preferred

Procedure of isolation and identification of IBDV

- **Isolation in chicken embryo**

- Suspected sample may be inoculated into SPF/antibody free embryonated chicken egg (9-11 day old) via chorio allantoic membrane(CAM) – death of embryo occurs in 3-5 days, splenomegaly and liver necrosis of embryo is observed

- **Pathogenicity in chicken embryo**

- Embryos that die after this time are examined for lesions.
 - Serotype 1 IBDV produces dwarfing of the embryo, subcutaneous oedema, congestion and subcutaneous or intracranial haemorrhages
 - Serotype 2 IBDV does not induce subcutaneous oedema or haemorrhages in the infected embryos, but embryos are of a smaller size with a pale yellowish discolouration.

Procedure of isolation and identification of IBDV

BGM-70 infected cell

- Primary cell culture in
 - Chicken embryo fibroblast(CEF) chicken embryo kidneys (CK), and chicken embryo bursas(CEB) and Madin Darby Bovine Kidney(MDBK)
 - Baby Grivet Monkey (BGM-70), Vero, Baby Hamster Kidney (BHK-21) cell line can also be employed for isolation of virus



4. Demonstration of viral antigen in clinical specimen

- Agar Gel Immunodiffusion (AGID) test
- Immunofluorescence test (IFT)
- Indirect Immunofluorescence Assays (IFA)
- Indirect Immunoperoxidase Assay (IPA)
- Enzyme linked immunosorbent assay (ELISA)



5. Demonstration of antibody in convalescent sera

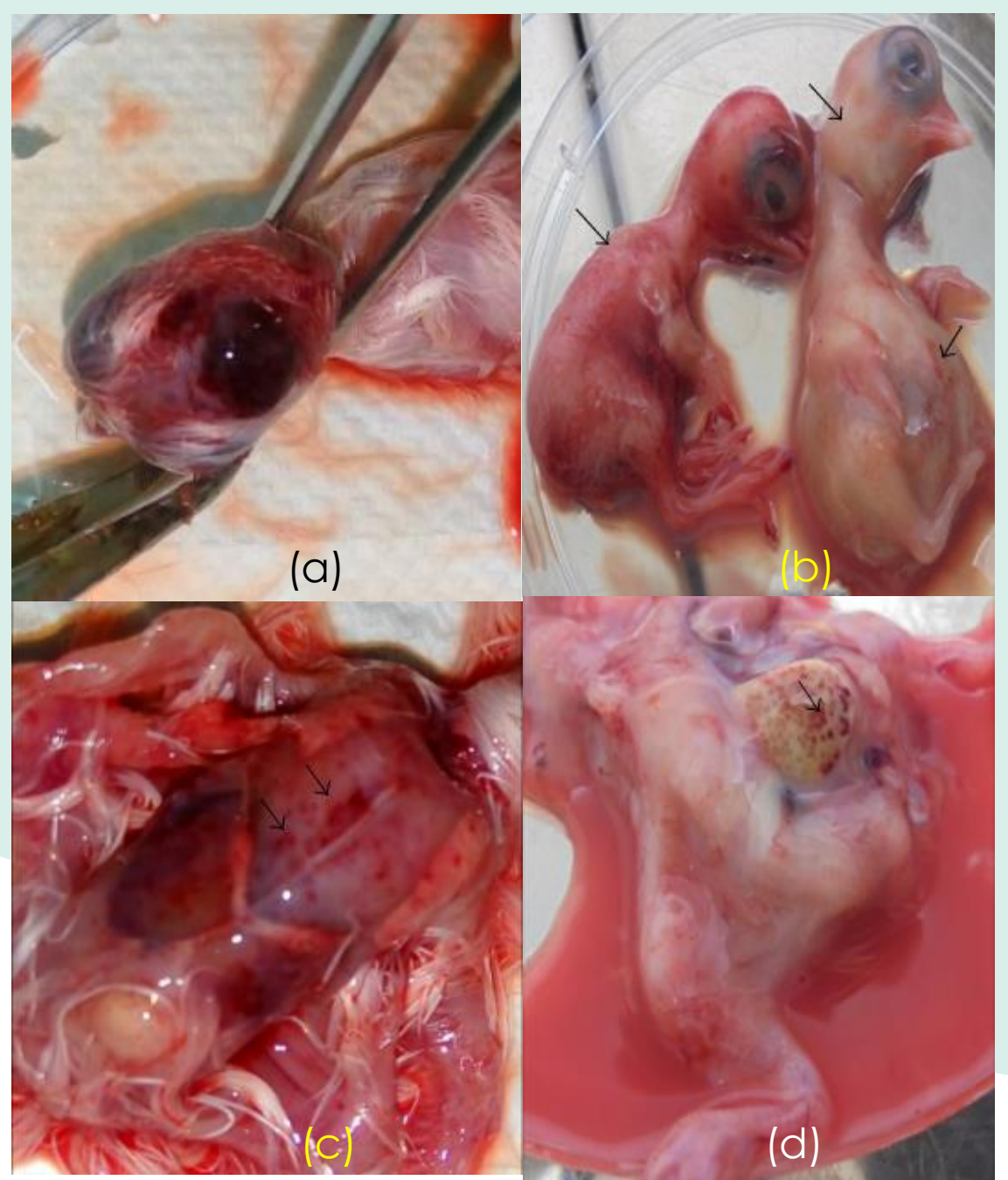
- Agar Gel Immunodiffusion (AGID) test
- Enzyme linked immunosorbent assay (ELISA)
- Virus neutralization test (VNT)

6. Detection of viral nucleic acid

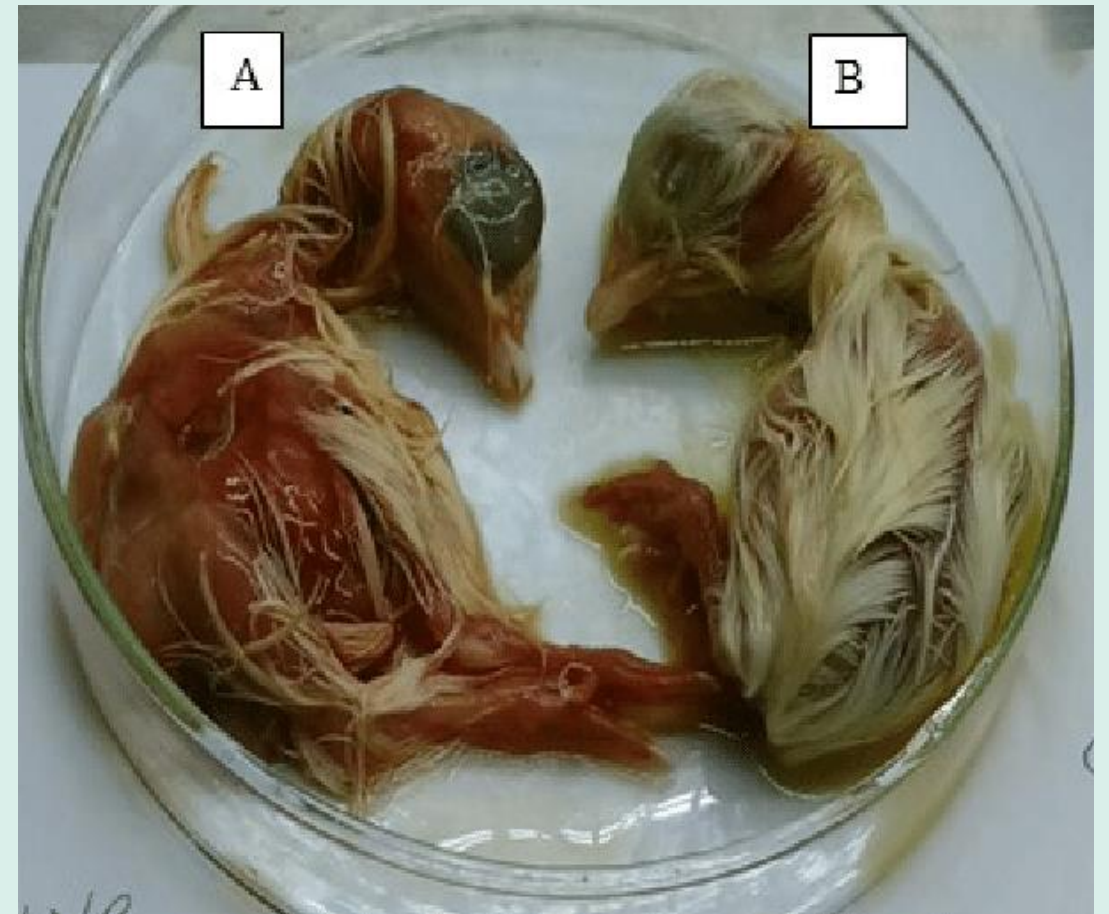
- Dot blot hybridization(with labelled gene probes)
- Reverse Transcriptase -Polymerase Chain Reaction (RT-PCR)
- *VP2* gene sequence Analysis

***IBDV* infected *SPF* embryos**

- (a) intracranial hemorrhage
- (b) hyperemia, abdominal distention, and subcutaneous edema
- (c) petechial hemorrhages on the breast muscle
- (d) mottled




***IBDV* infected *SPF* embryos**



- A. (IBDV inoculated with infected bursal homogenate showing haemorrhagic and oedematous embryo
- B. Normal embryo.


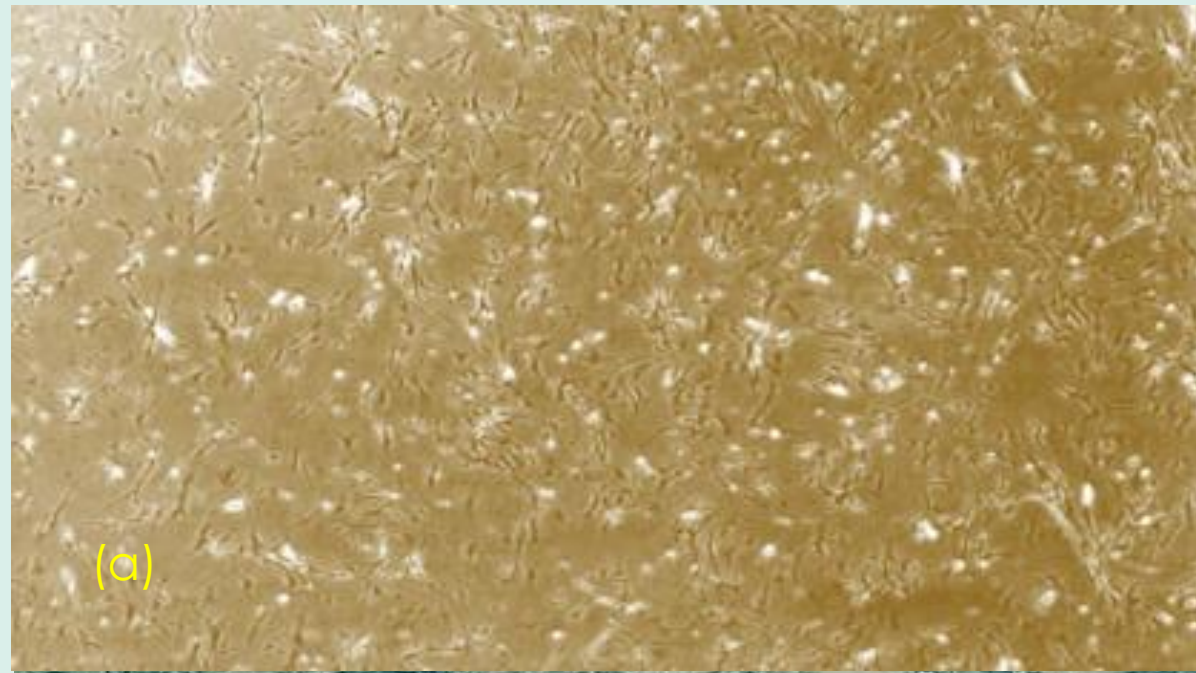
CPE on BGM-70 Cell Line

- (a) A normal confluent monolayer of BGM-70 cells
- (b) induced CPE on BGM-70 infected cells including small refractive cells, cytoplasmic granulation, cell rounding, and detachment
- (c) BGM-70 cells infected with IBDV
- (d) little CPE compared with
- (e) uninfected cells



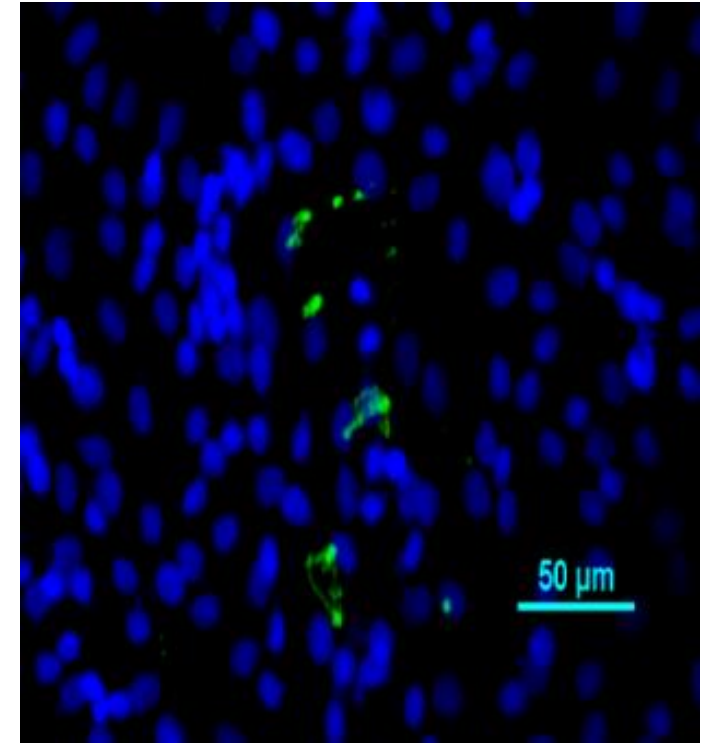
CPE on CEF

- (a) A normal confluent monolayer of CEF cell.
- (b) induced CPE on CEF infected cells including small refractive cells, cytoplasmic granulation, cell rounding, and detachment



Immunofluorescence test (IFT)

- Fluorescent antibody detection of IBDV in fresh bursal tissue impression smears is also a reliable method of detection

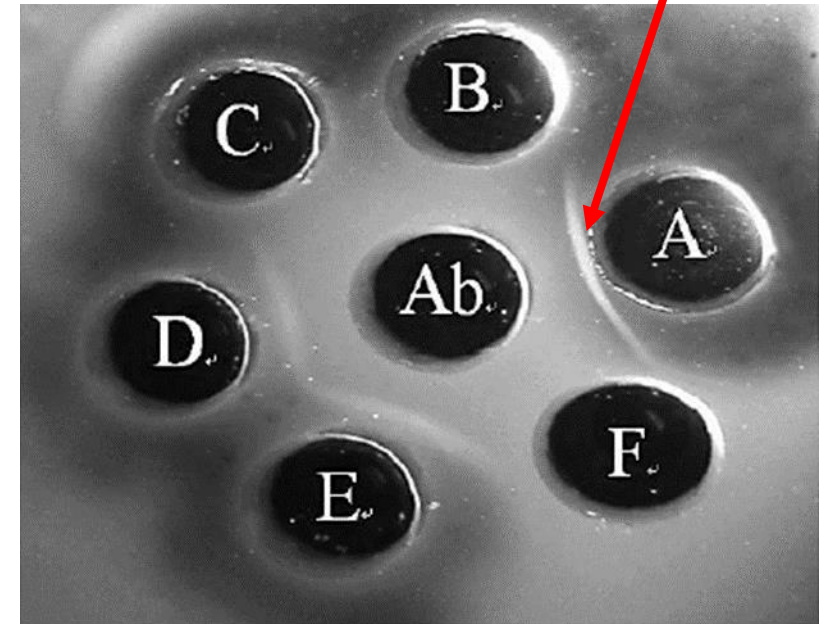


IBDV infected BGM-70 cells showing (a) blue fluorescence when stained with DAPI (b) green fluorescence when stained with FITC-labeled anti-chicken antibody indicating the presence of VP2 antigen

AGPT for diagnosis of IBDV

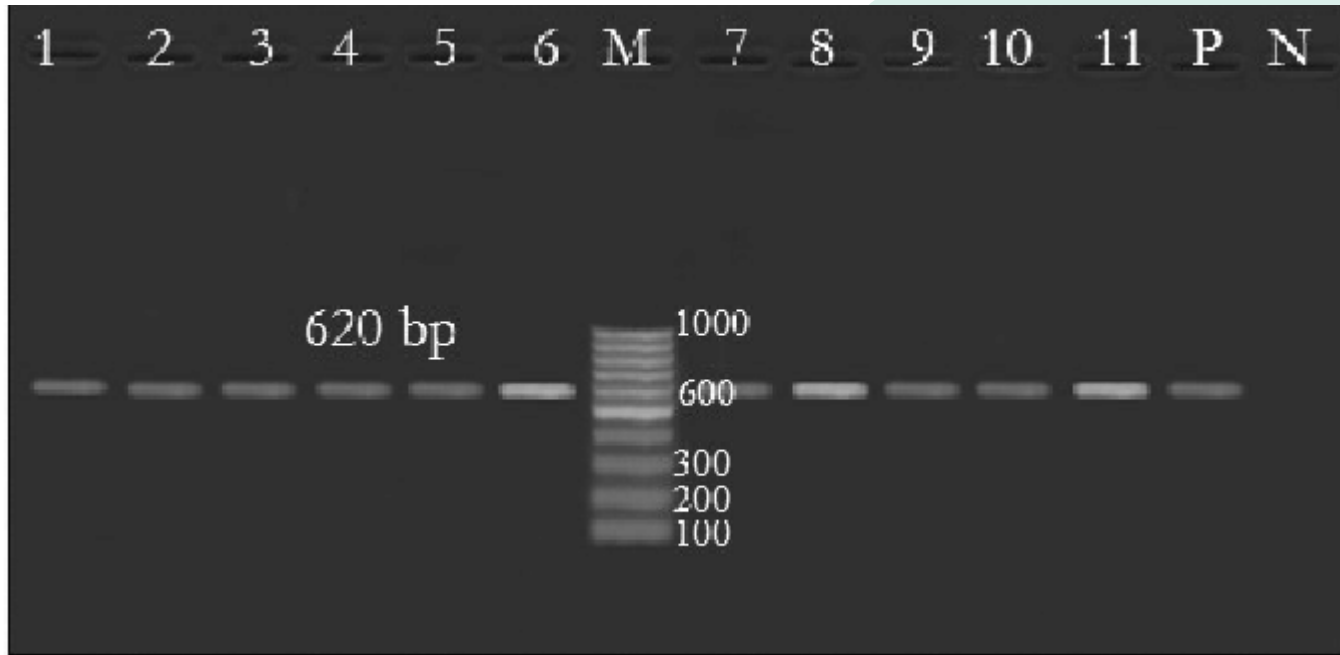
- Precipitation of antigen-antibody complexes from solution is basic principle for AGPT.
- Agar gel precipitation test (AGPT) or Agar gel diffusion test (AGDT) or Agar gel immunodiffusion (AGID) is the most common and simple test used for detection of IBDV specific antibodies in serum, or viral antigen in bursal tissue.

Precipitin band infers IBDV positive sample

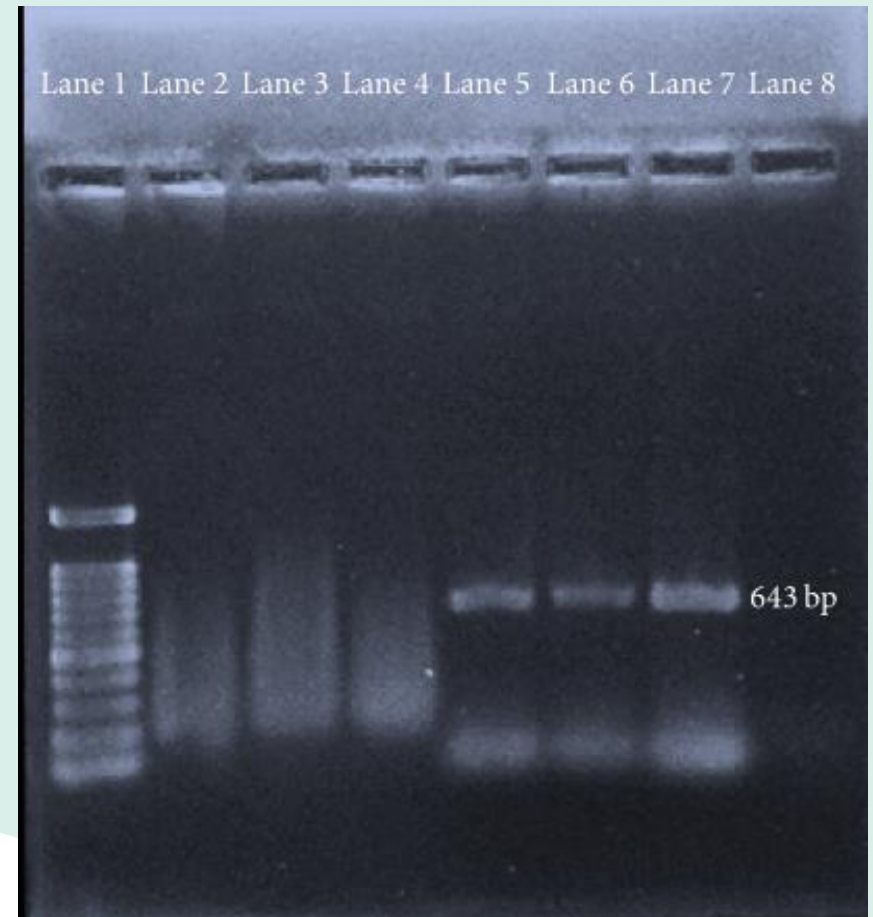


AGPT of bursal homogenates

RT-PCR for diagnosis of IBDV



Agarose gel electrophoresis of the 620 bp RT-PCR product of the eleven isolates: lanes 1-11: the selected samples; M: DNA marker; P: positive control; N: negative control.



RT-PCR products of the BGM-70 cell culture

- 100 bp molecular ladder (Lane 1)
- Nontemplate control (lanes 2 and 3)
- Negative sample (lane 4)
- Positive sample (Lane 5, Lane 6 and Lane 7)

Prevention

1. Vaccination -
 - a. with intermediate or intermediate plus/hot vaccines for broilers at 14-21 days.
 - b. With killed –virus vaccines in oil adjuvant in breeders as booster at 16-18 weeks.
2. Disease awareness, early detection, proper disposal of affected birds, timely notification.
3. Strict biosecurity, isolation, zoning, quarantine.

Acknowledgement

- Content and images have been taken from www.google.com.
- The content taken from website is for academic purpose and has no commercial use.
- The contributors are duly acknowledged.

Further reading

Infectious bursal disease virus, Chapter 16. *Birnaviridae and Picobirnaviridae*, Fenner's **Veterinary Virology**, Fifth Edition.

Infectious bursal disease of chicken, Chapter 25, *Birnaviridae*, **Veterinary Virology**, Third Edition, Academic Press.



Thanks