



Surgical Management of Upward Fixation of Patella (UFP)/Stringhalt in Large Animals

Unit 6: Fourth Year Professional

Dr. Ramesh Tiwary
Assistant Professor
Deptt. of Veterinary Surgery and Radiology

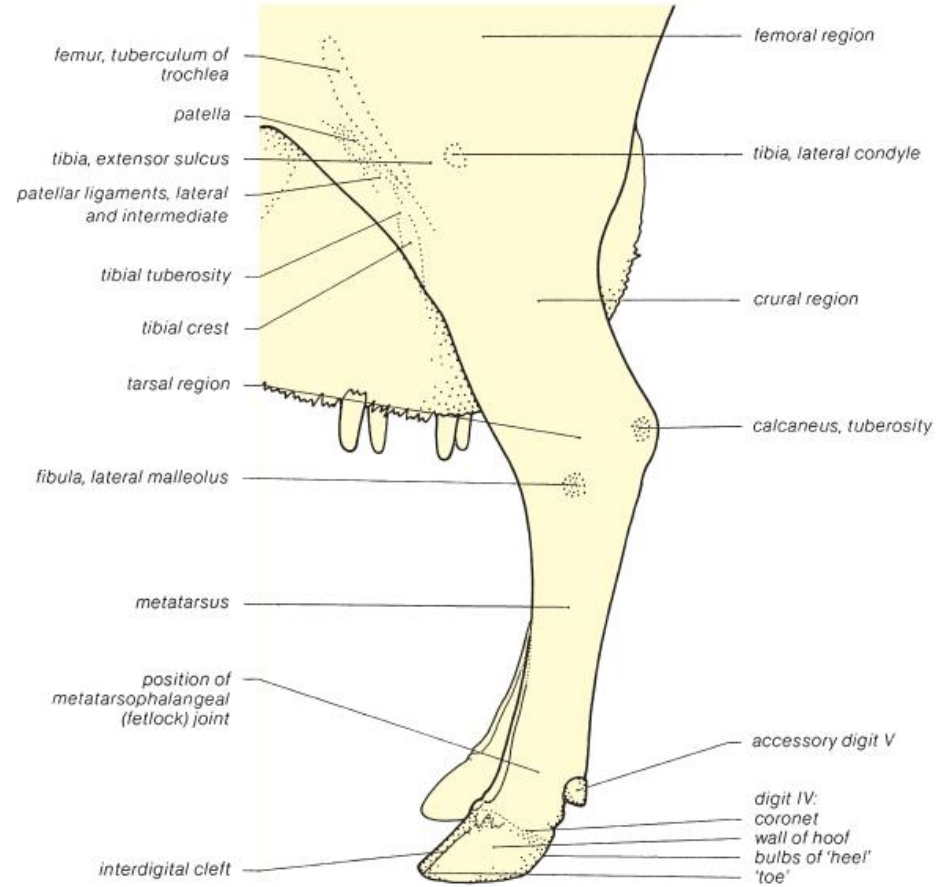
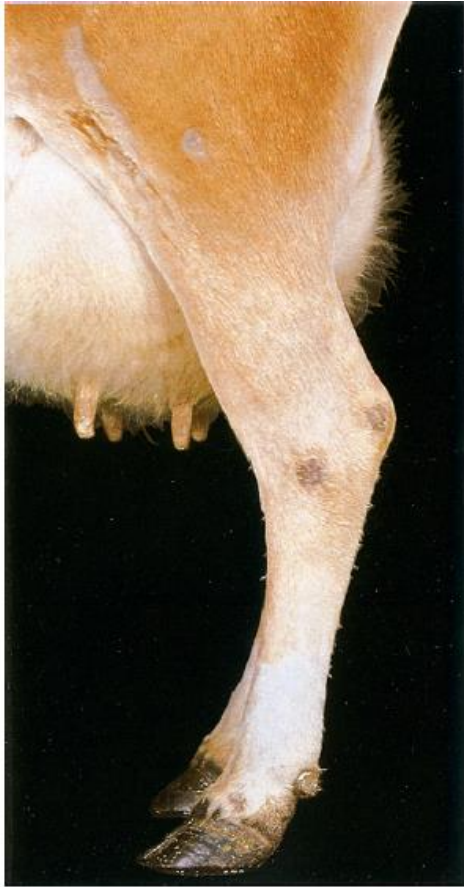Clinical Sign



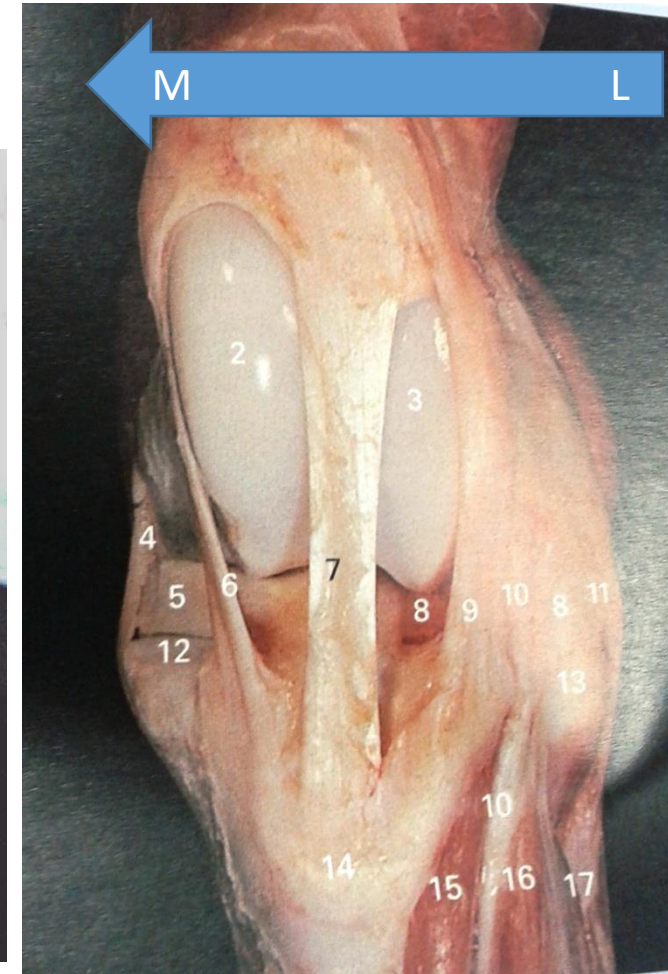
Predisposing Causes

- Occupational Trauma
- Laxity of Ligament
- Climate Condition
- Pregnancy

- The patella get fixed between the trochlear ridges by hooking the medial fibrocartilage of patella over medial trochlear ridge of femur.



How to locate the MPL



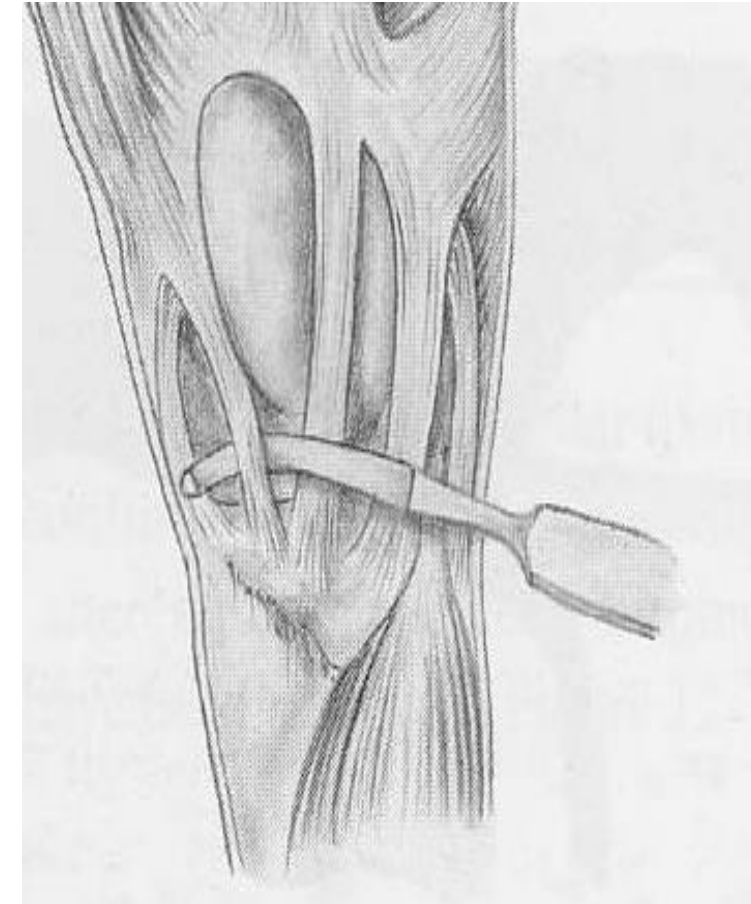
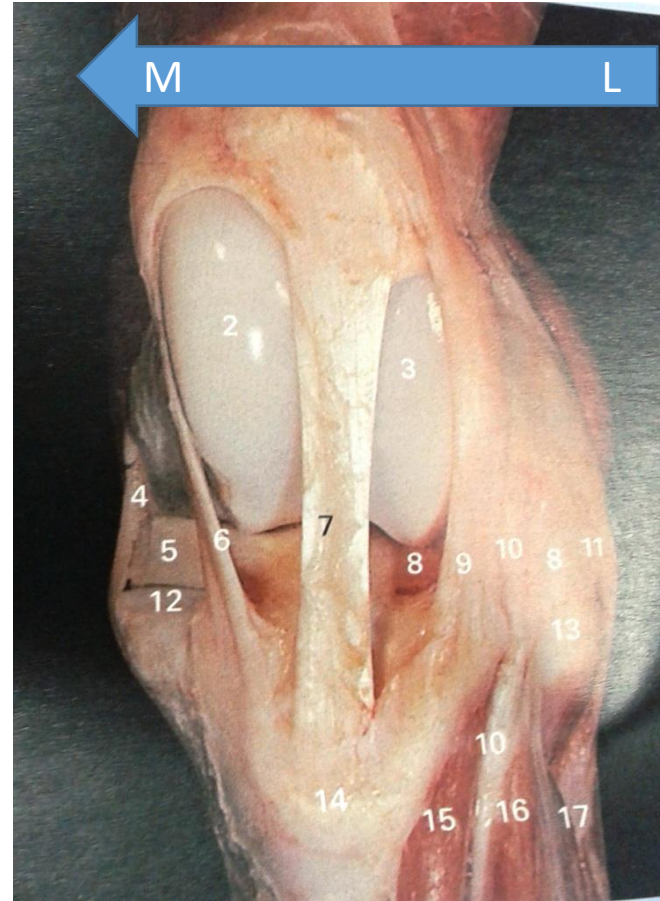
Restraining/Positioning



Inj. Xylazine 5 mg IV /COW/Buffalo
Inj. Butorphanol 2 mg IV/COW/Buffalo



Surgical Correction



Depression at the location of medial patellar ligament, Cessation of crunching sound and immediate relief of the characteristic jerk flexions during progression indicates successful surgery.

Medial Patellar Desmotomy



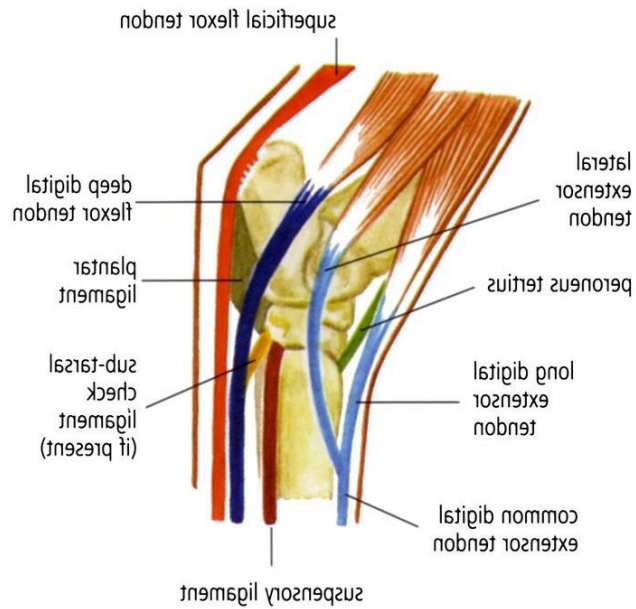
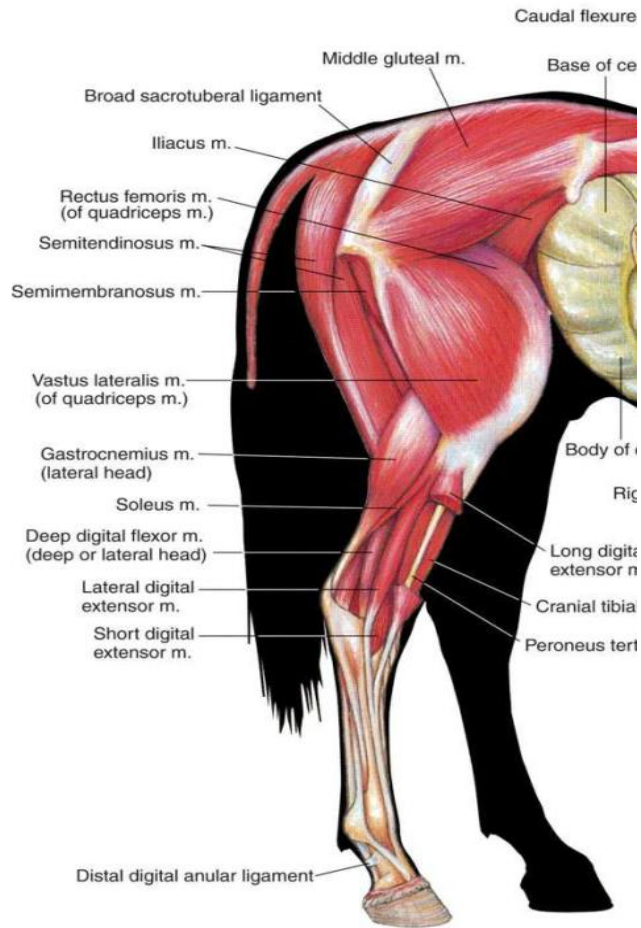
Buffalo Post Surgery.xspf1.xspf



Stringhalt in Horses



Boccar's operation/ Peroneal tenotomy



Lateral Digital Extensor Tenotomy