

RADIOLOGY-2

Fourth Professional(NEW)

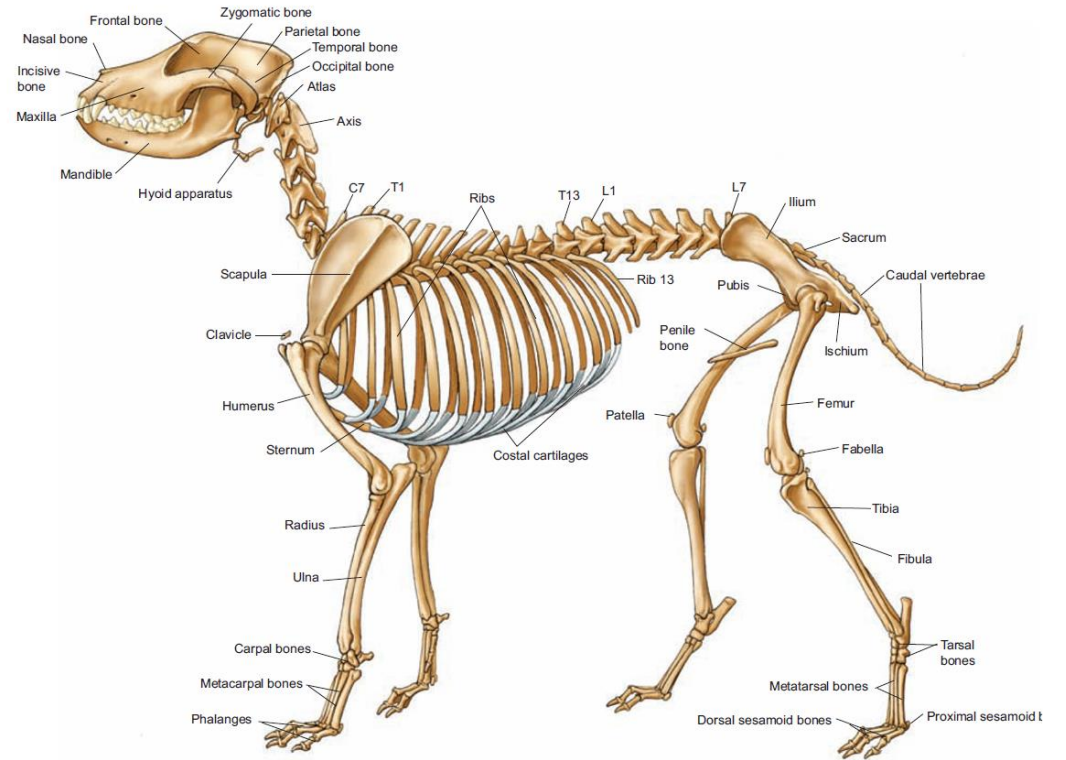
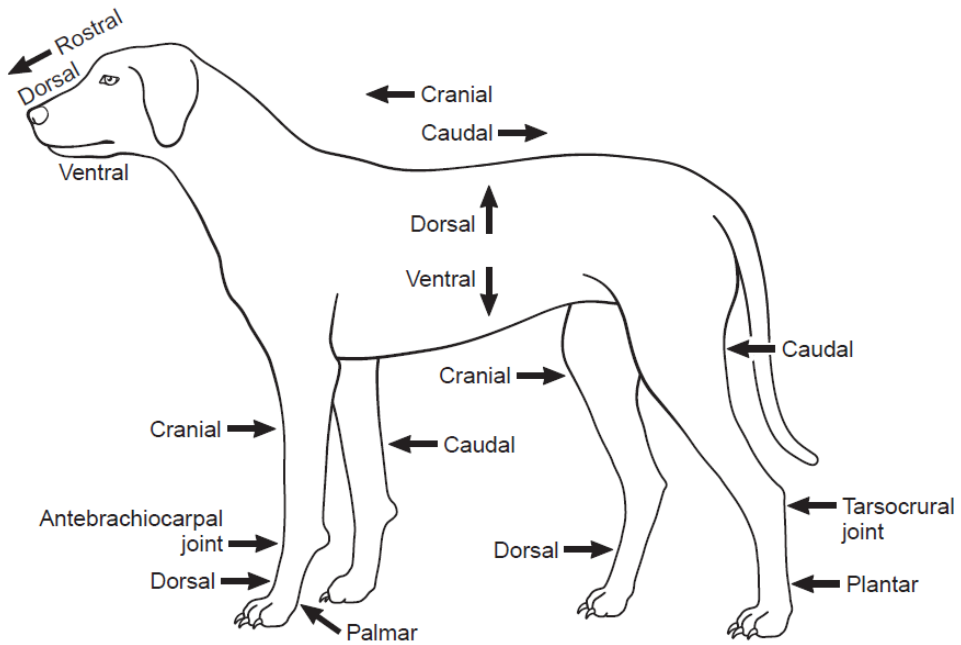
Dr. RAMESH TIWARY

ASSITANT PROFESSOR

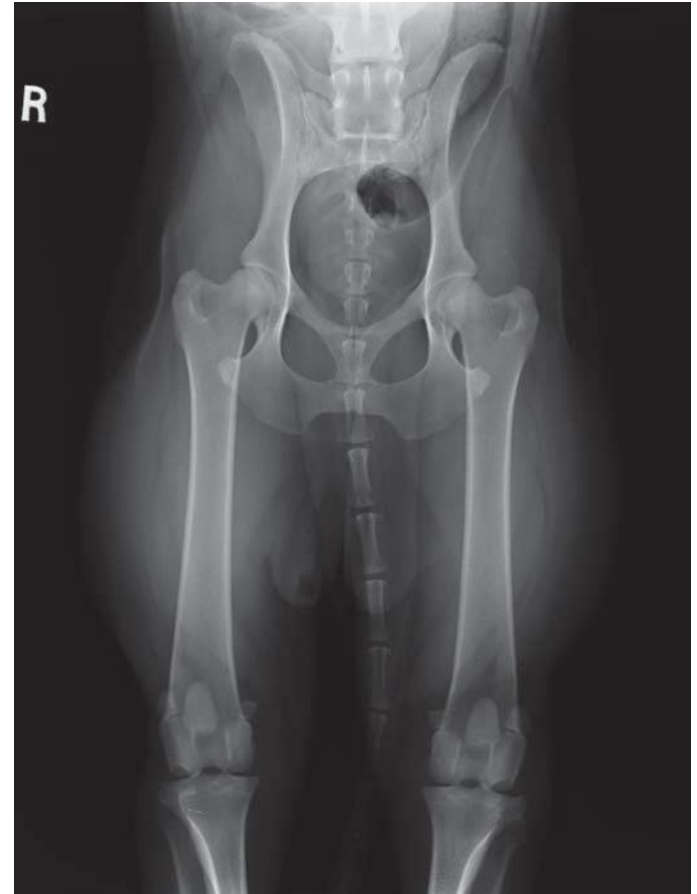
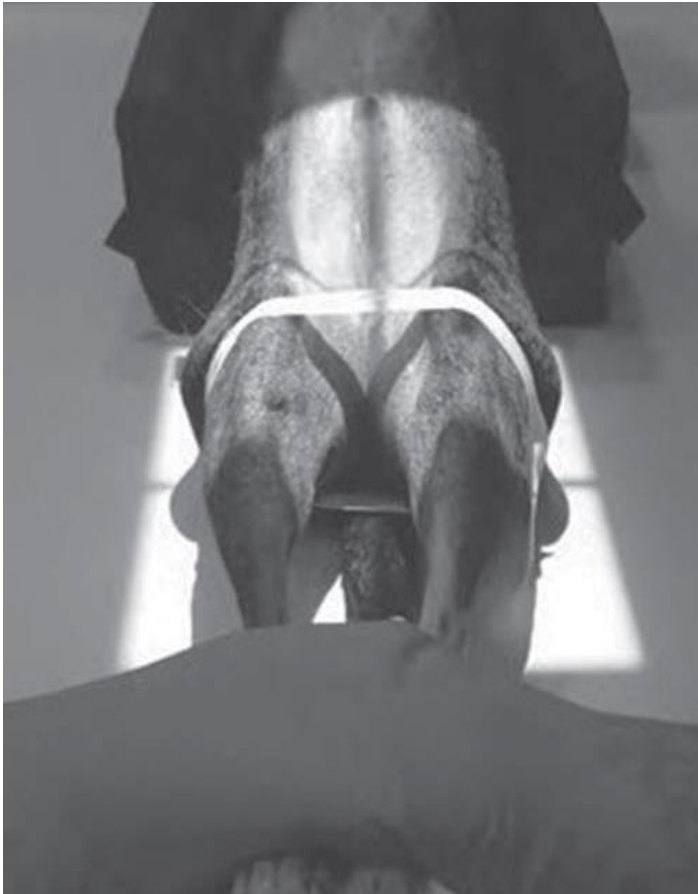Department of Veterinary Surgery & Radiology

BVC, PATNA-14

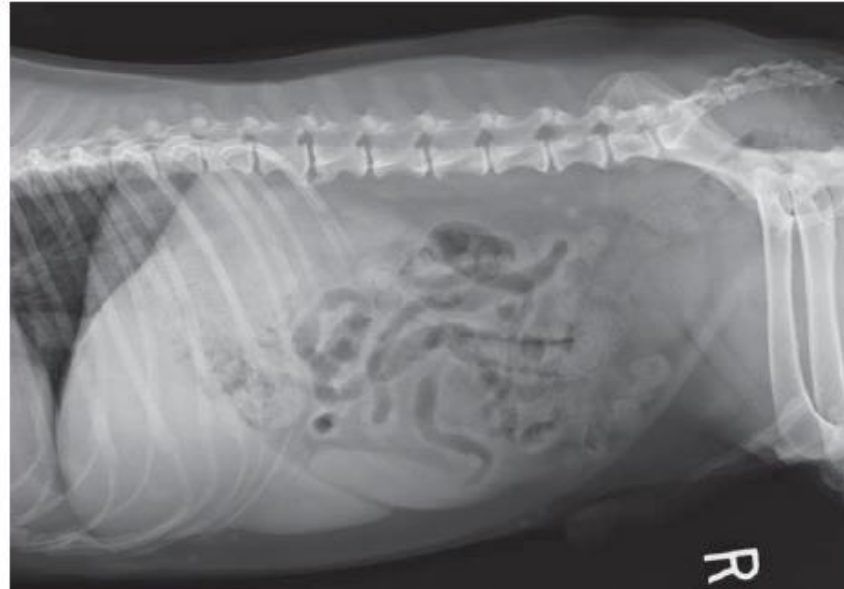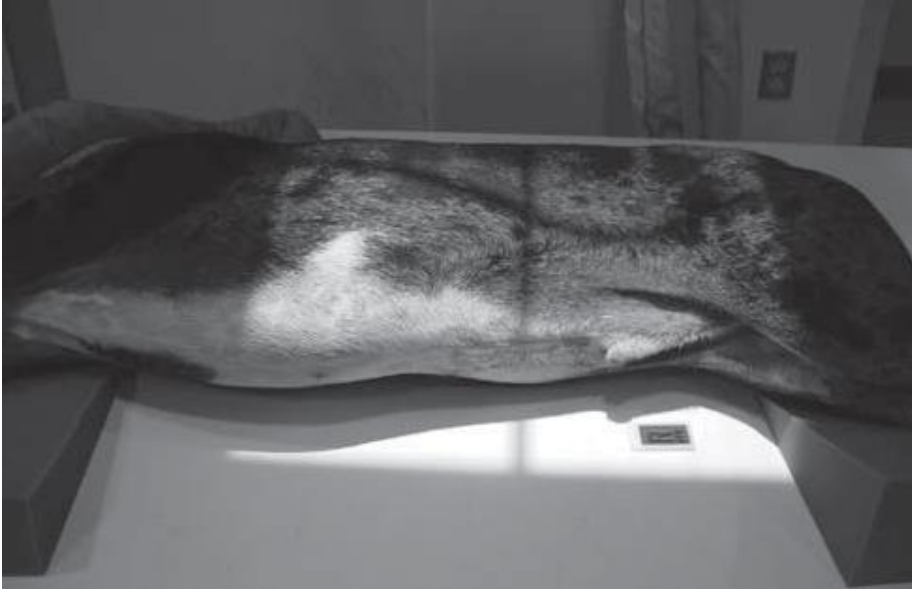Directional Term



VD/DV

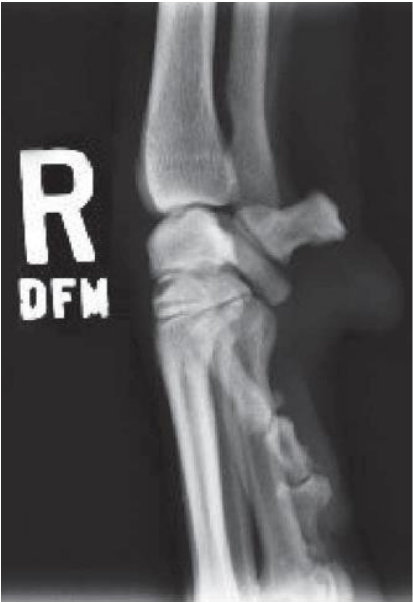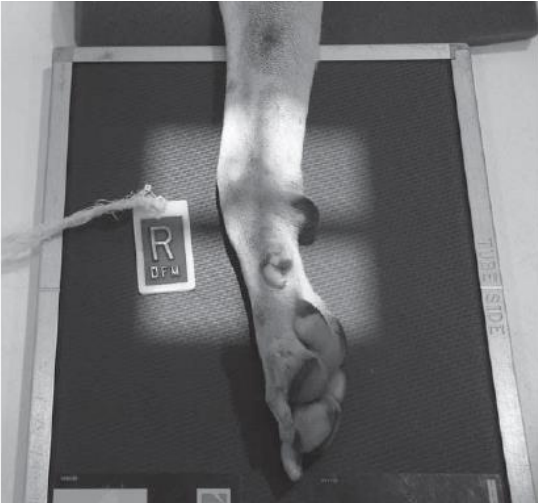

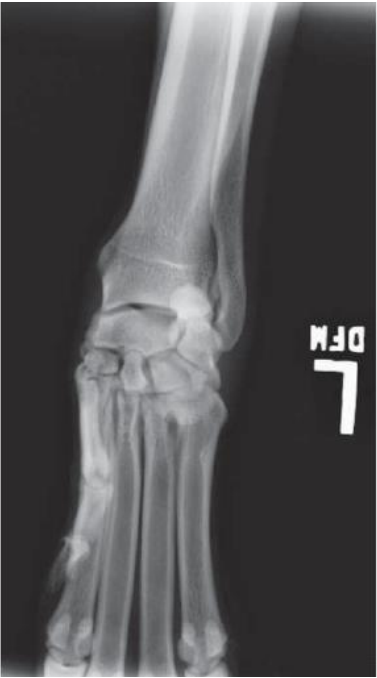
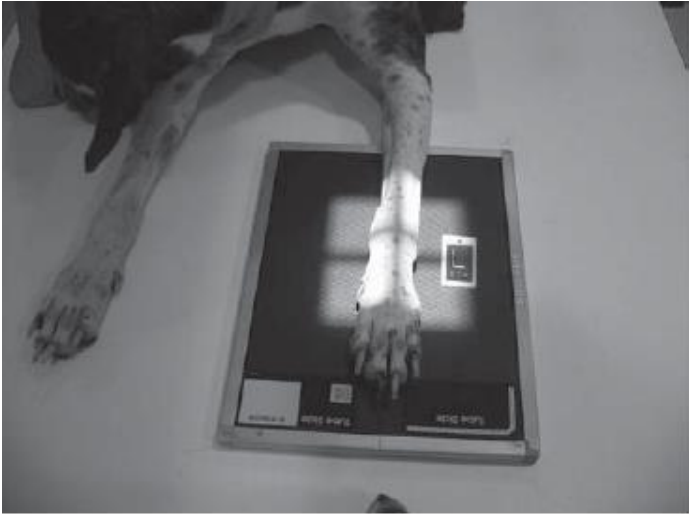
RL/LL

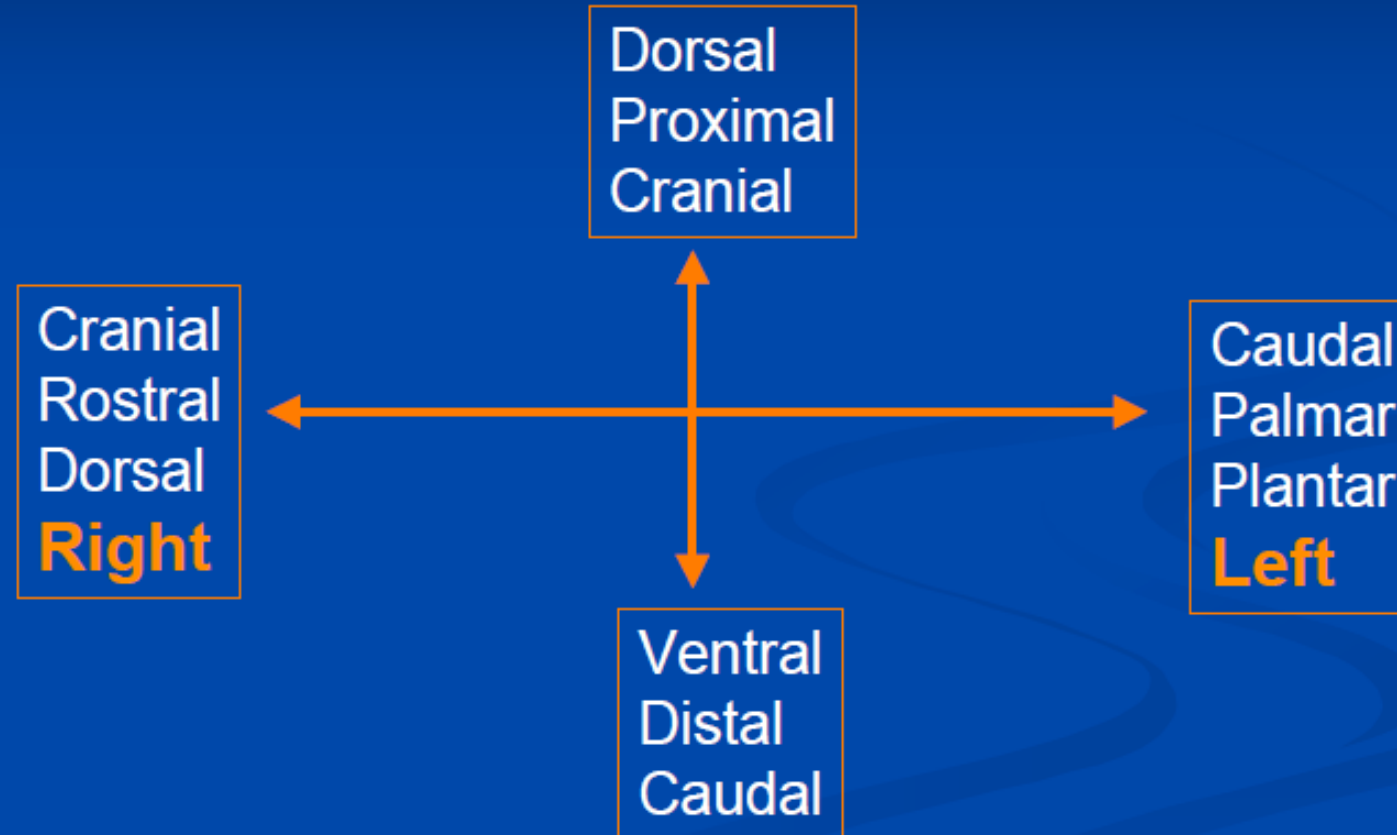


© Delmar/Cengage Learning

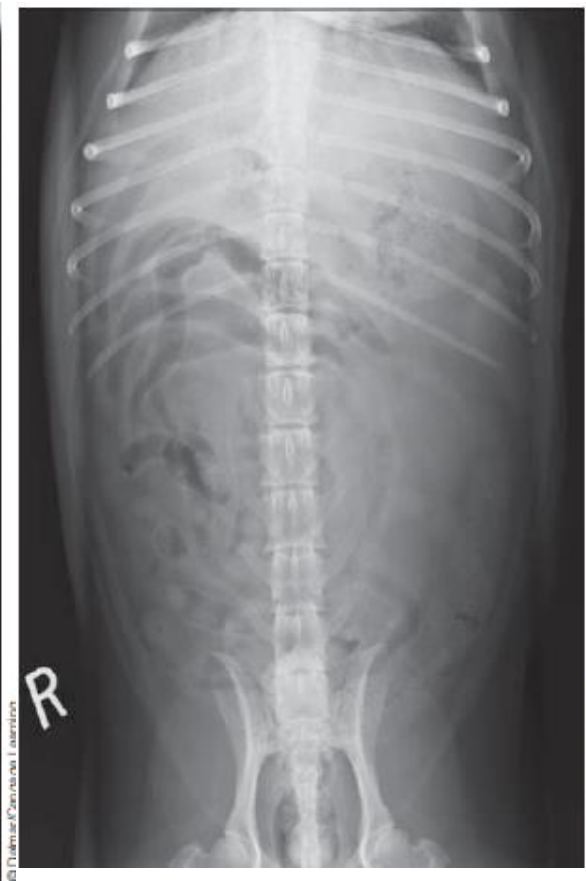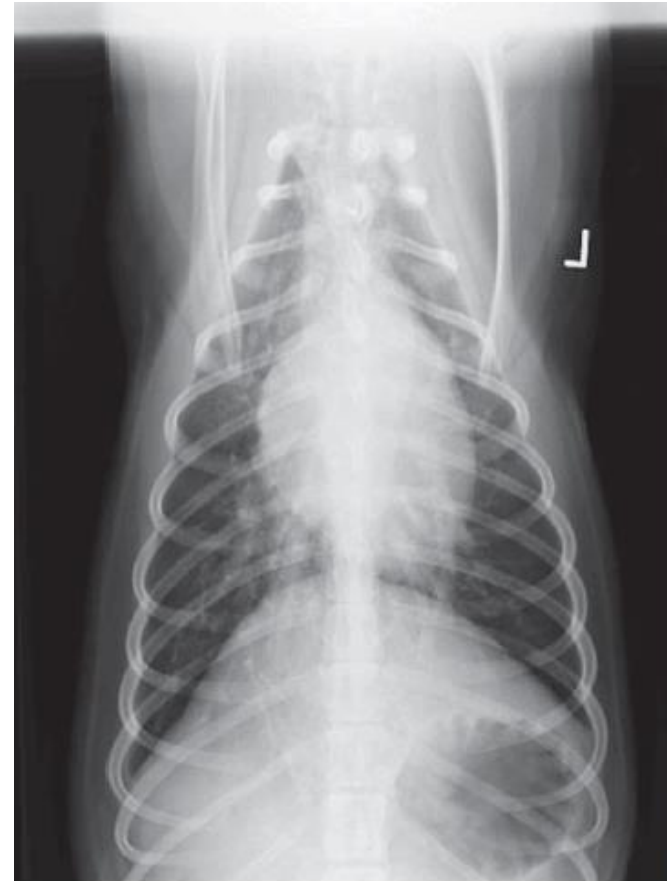
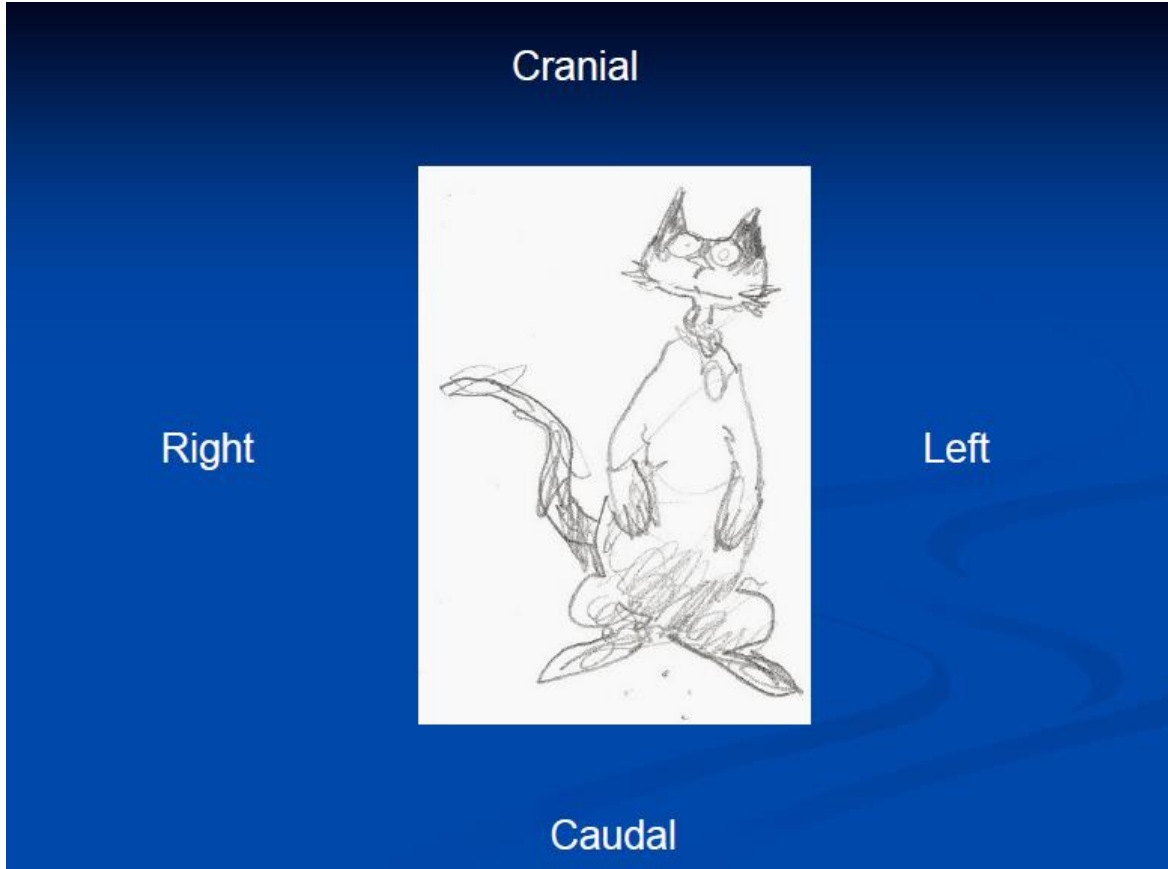
AP/ML



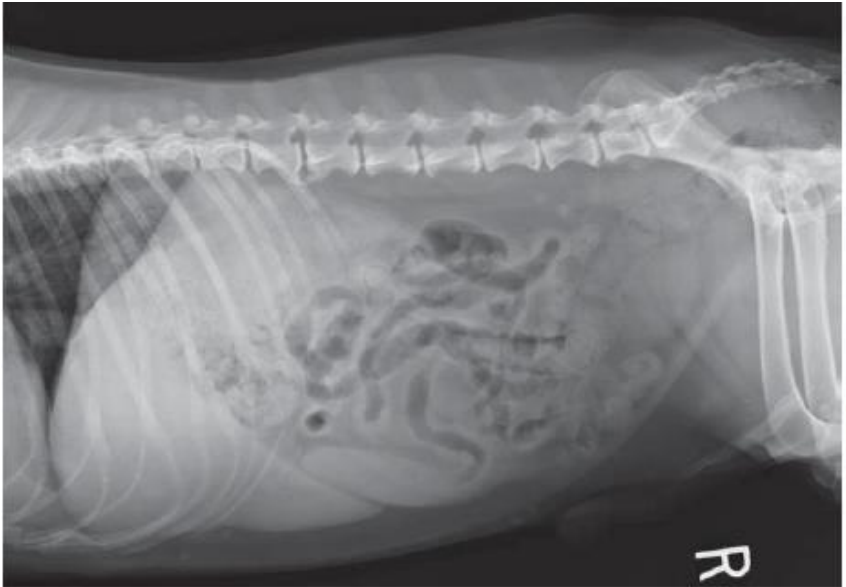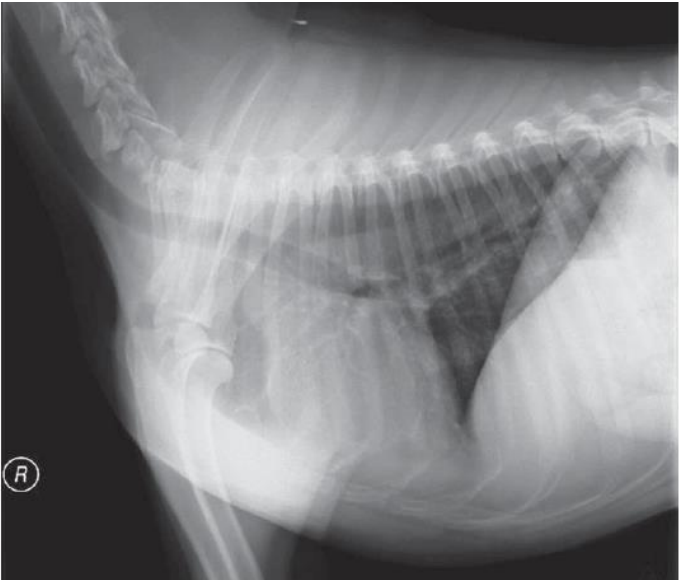
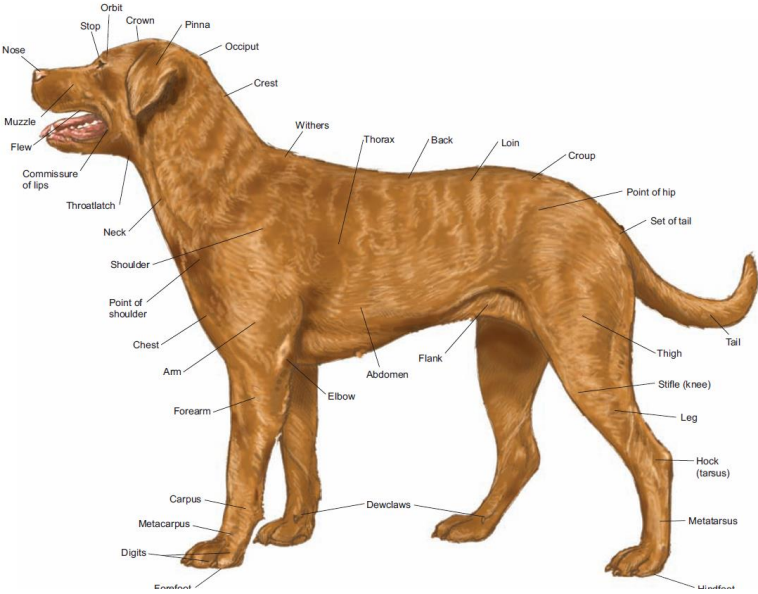
Standard radiographic direction when viewing



Positioning of Radiographs for Interpretation

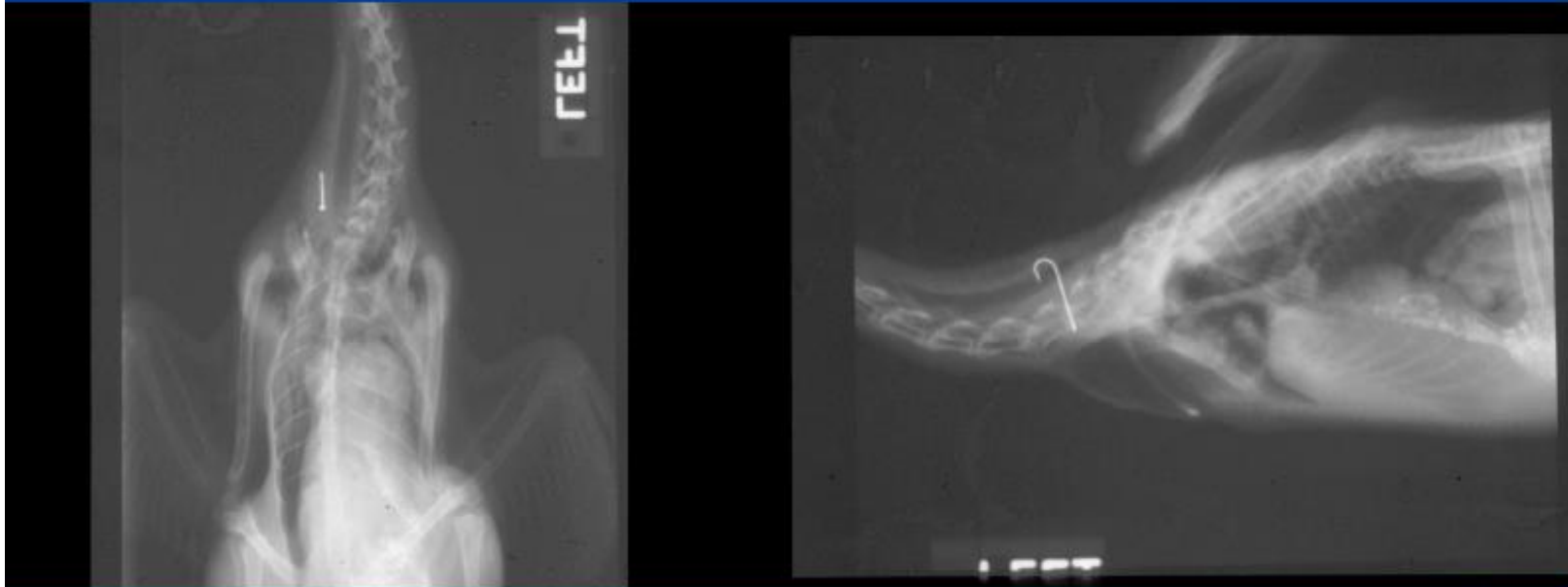


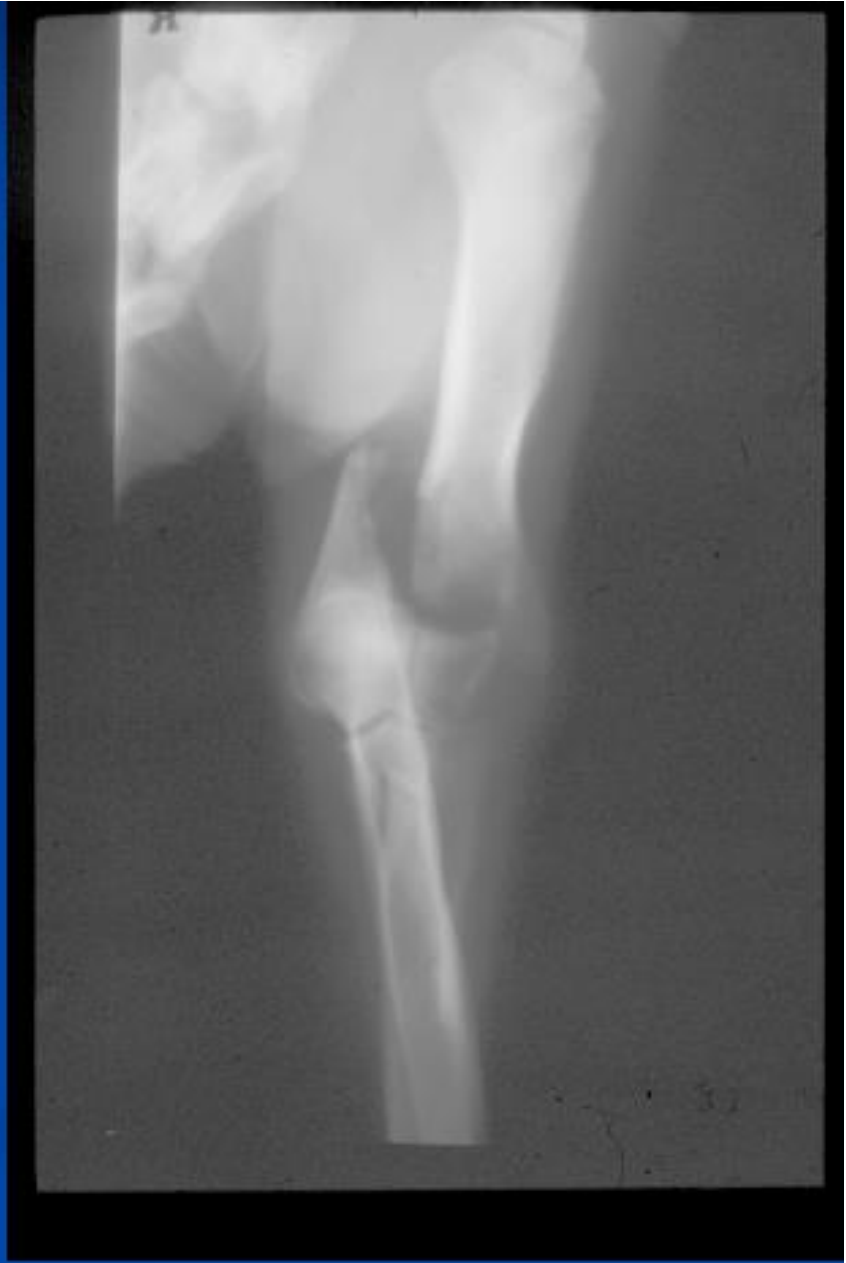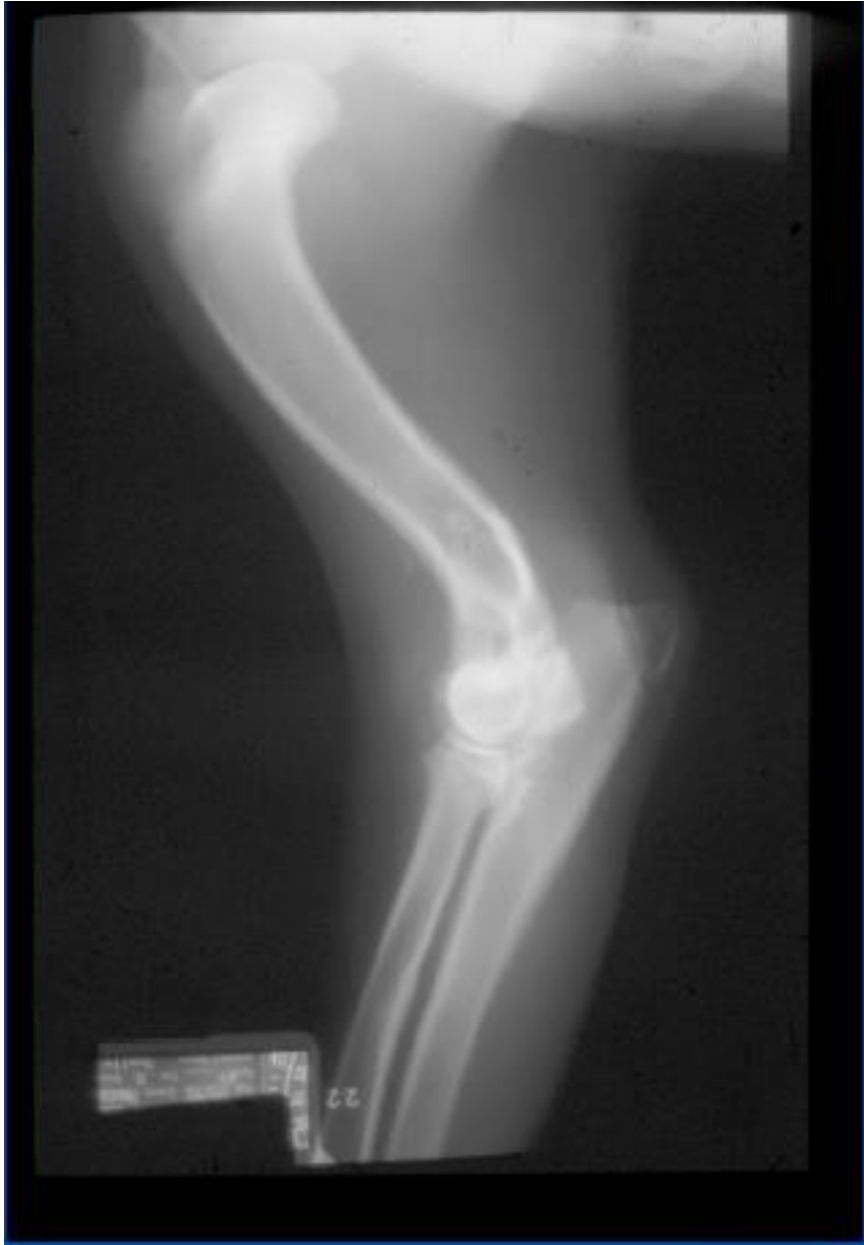Lateral View



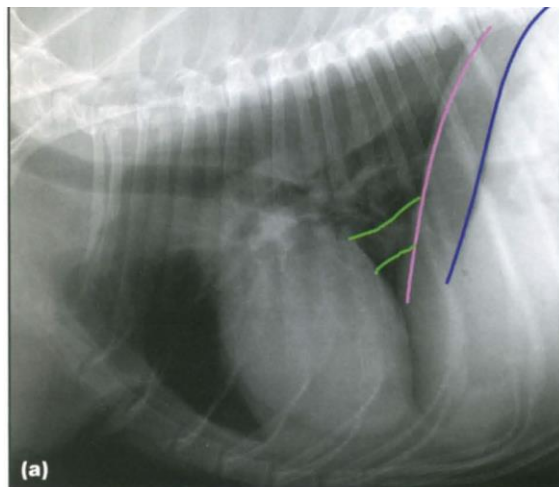
Minimum Take Two View

What is it?

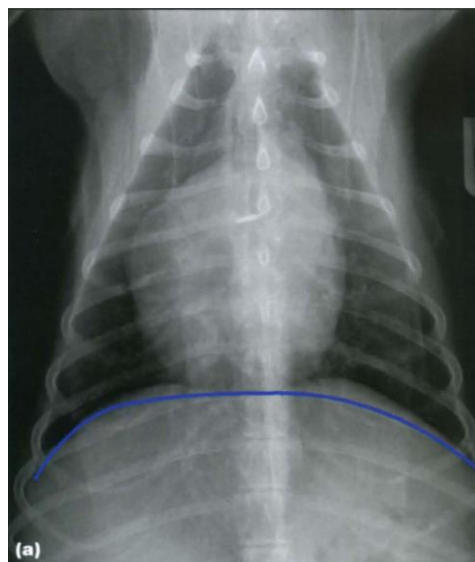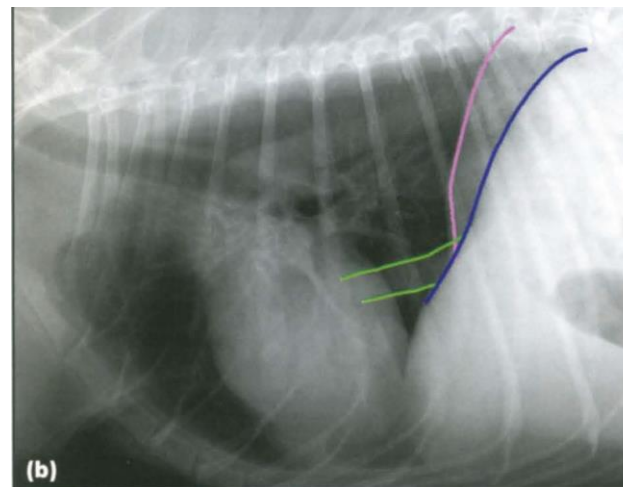




Three View for Thoracic Radiographs



• RL/LL



DV/VD

