



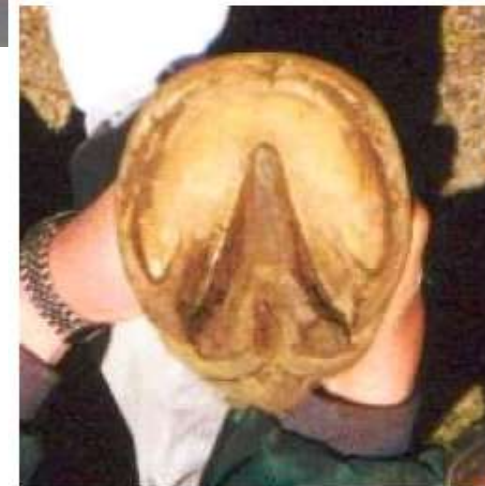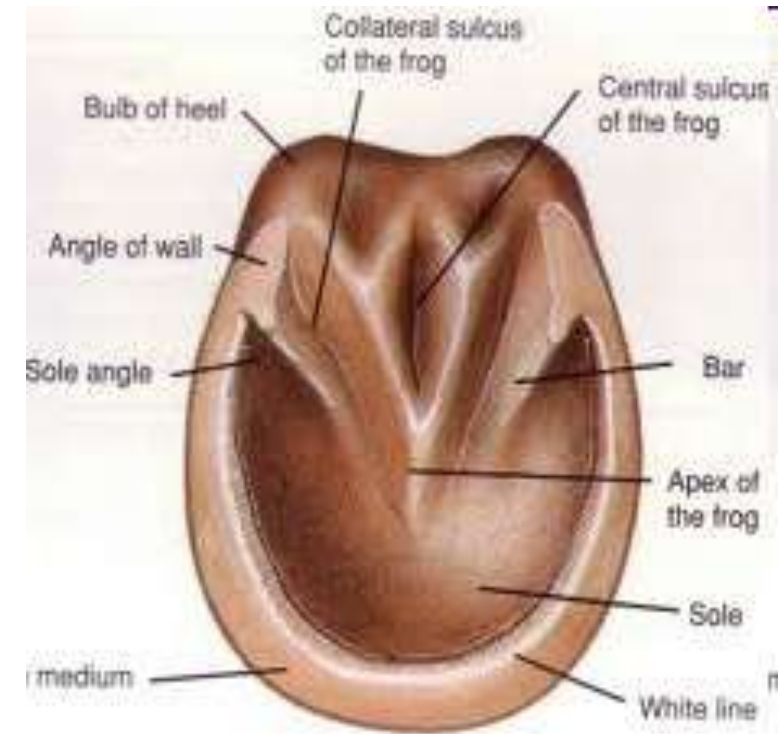
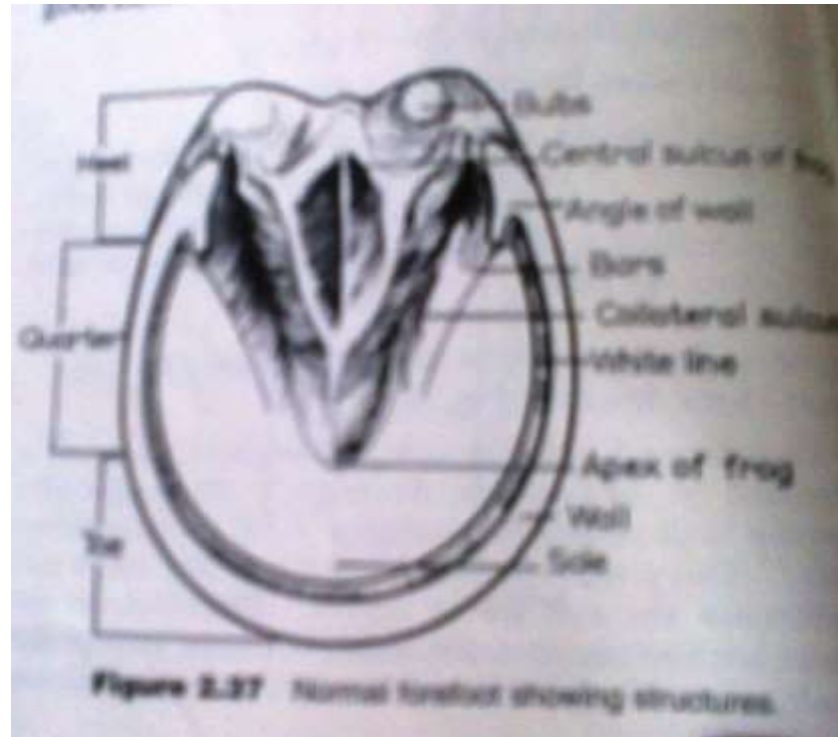
Equine Foot Affections- I

FOURTH PROFESSIONAL UNIT-9

Dr. Ramesh Tiwary
Assistant Professor
Deptt. of Veterinary Surgery and Radiology

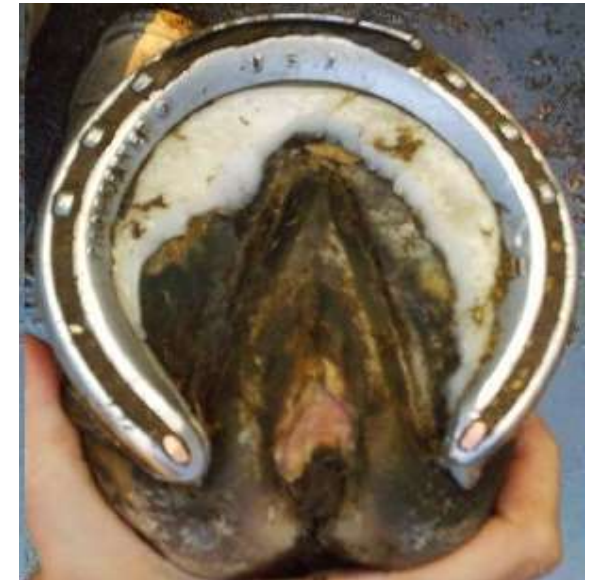NORMAL HORSE FOOT

- The fore feet are usually larger, rounder, and wider at the heels and have flatter soles
- Hind feet are commonly one shoe size smaller, are more pointed at the toe, and have a more concave sole and higher hoof angle.



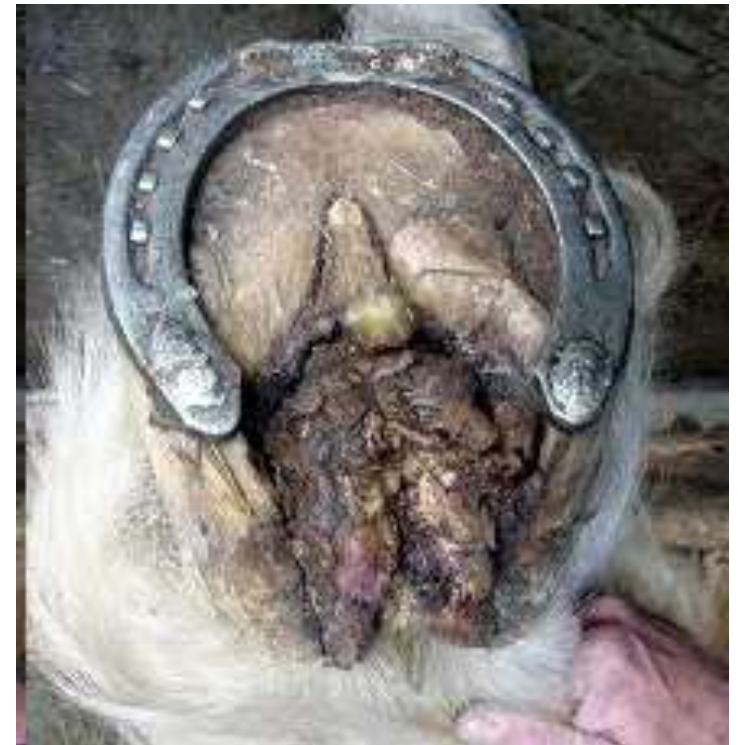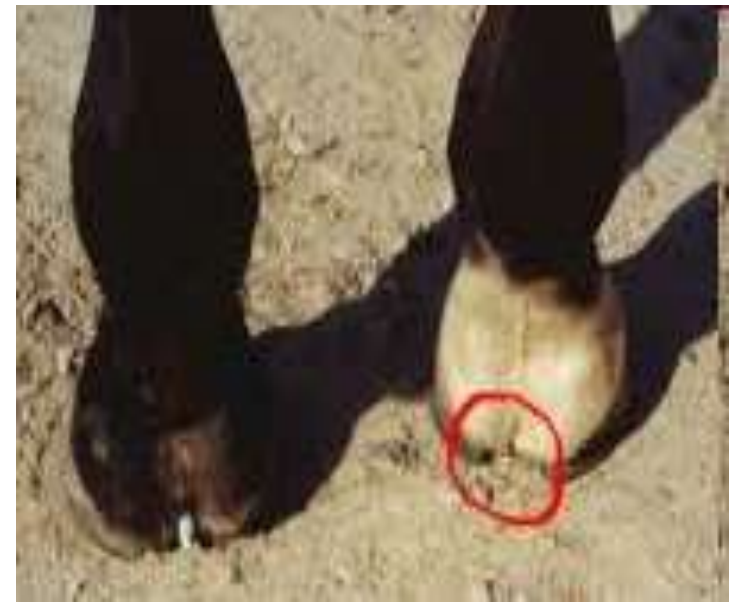CANKER

- ❖ Chronic, hypertrophic, moist, eczematous, dermatitis (CHMED) of foot in which frog, sole and wall are affected.
- ❖ Moist unhygienic conditions saprophytic infection- Fusobacterium, Bacteroides
- ❖ Debride-Trimming
- ❖ Penicillin, tetracycline, Metronidazole locally, Antifungal (Ketokonazole)
- ❖ Adopt preventive measures



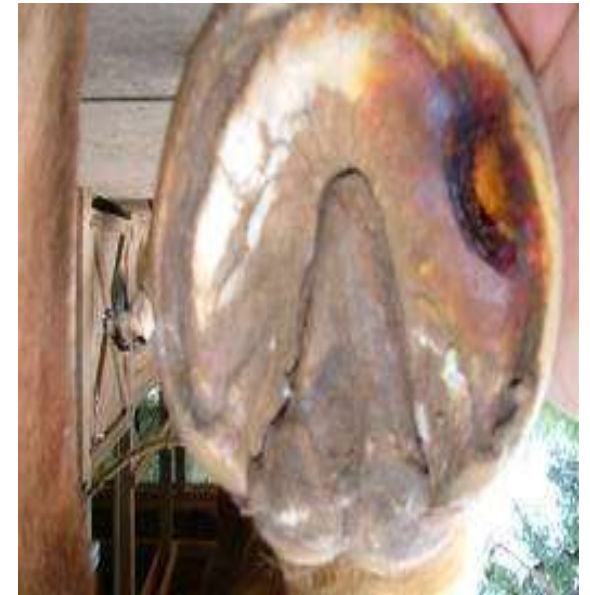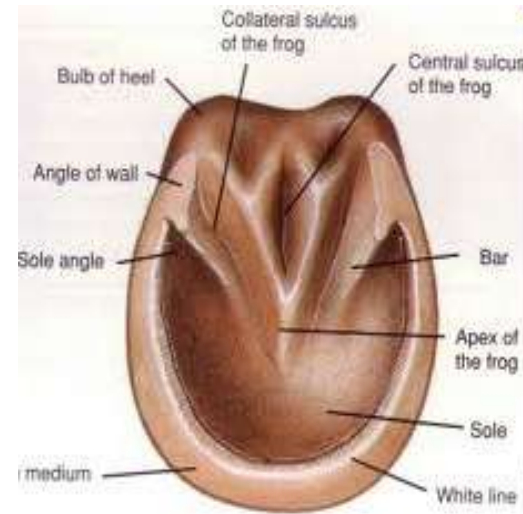THRUSH

- Degenerative condition of frog involves lateral and medial sulci, off smelling with necrotic material
- Moist and unhygienic conditions
Saprophytic infection
- Poor hoof care and lack of exercise



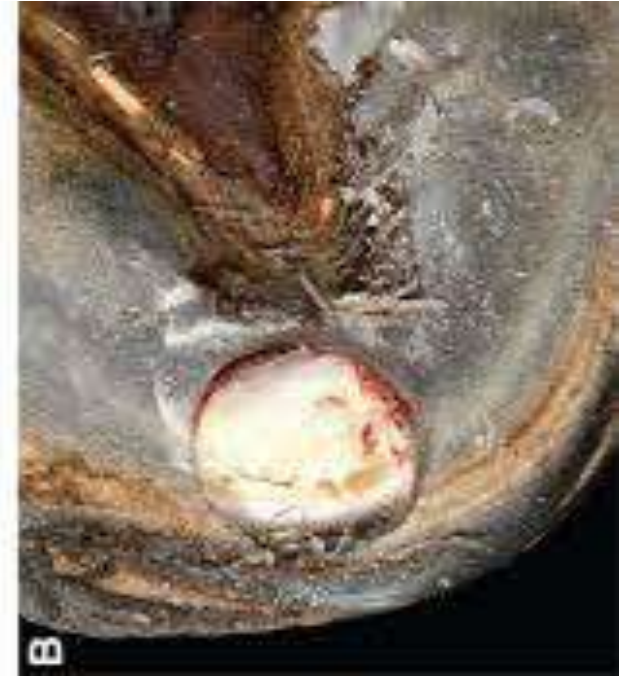CORN

- Contusion of the sensitive laminae at the angle formed between the wall and the bars of the hoof-Seat of Corn.
- Contusion at Sole: Bruised Sole
- Frog: Bruised frog
- Most Common at Inner aspect of fore limb.



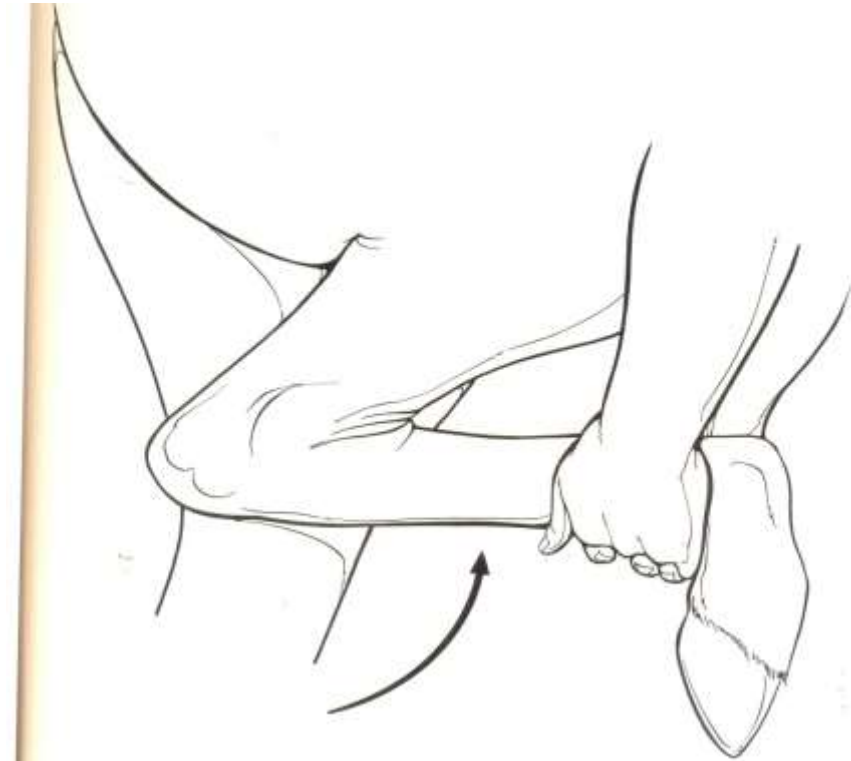
Keratoma

- Tumour consisting of horny tissue growing from the inner aspect of the wall of the hoof.



SPAVIN

- **Spavin**:- Osteoperiostitis and chronic arthritis in the hock region below the level of the tibio-tarsal articulation is known as spavin.
- **Spavin test** :- Lift the affected limb and keep it holding with the hock flexed for about two minutes. Then release the limb immediately and trot the animal.



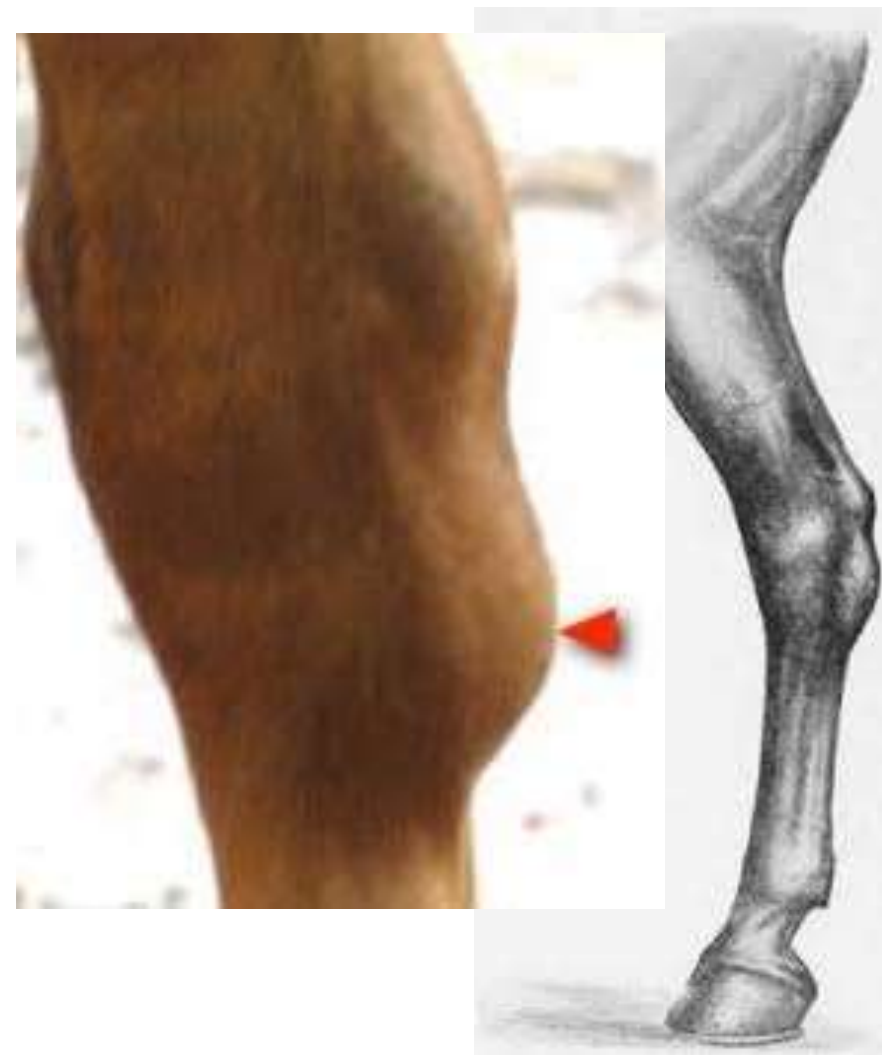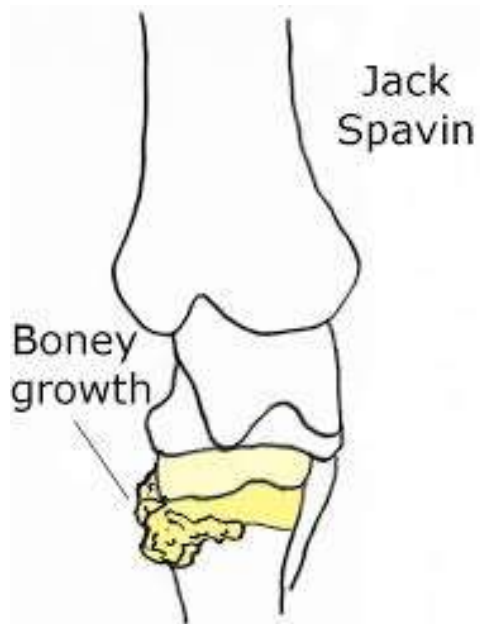
BOG SPAVIN

- Distension of tibio-tarsal joint capsule at supero-antero-internal aspect of hock joint.
- Constant hard work & Deformities of hock
- Aspiration and injection of corticosteroid irritants solution
- **Blood spavin:** Varicose condition of internal saphenous vein.



BONE SPAVIN

- Osteoperiostitis and chronic arthritis of hock joint.
- Exostosis mainly seen at postero-infero-internal aspect of hock joint in front of chest nut: Seat of spavin
- Large exostosis-Jack spavin
- Local Ankylosis
- Cuneal tenotomy or Anterior and posterior tibial neurectomy.



THOROUGHPIN

- Distension of the tarsal sheath of the deep digital flexor tendon just above the hock due to chronic synovitis.
- C/b plantar fluid-filled swellings visible on both medial and lateral sides proximal to the tibio-tarsal joint.
- It is usually unilateral and varies in size.
- Treatment is by withdrawal of the fluid and injection of hyaluronic acid or a long-acting corticosteroid, which may need to be repeated until the swelling does not recur.

