

Genus : *Ancylostoma*

Dr R. K. Sharma

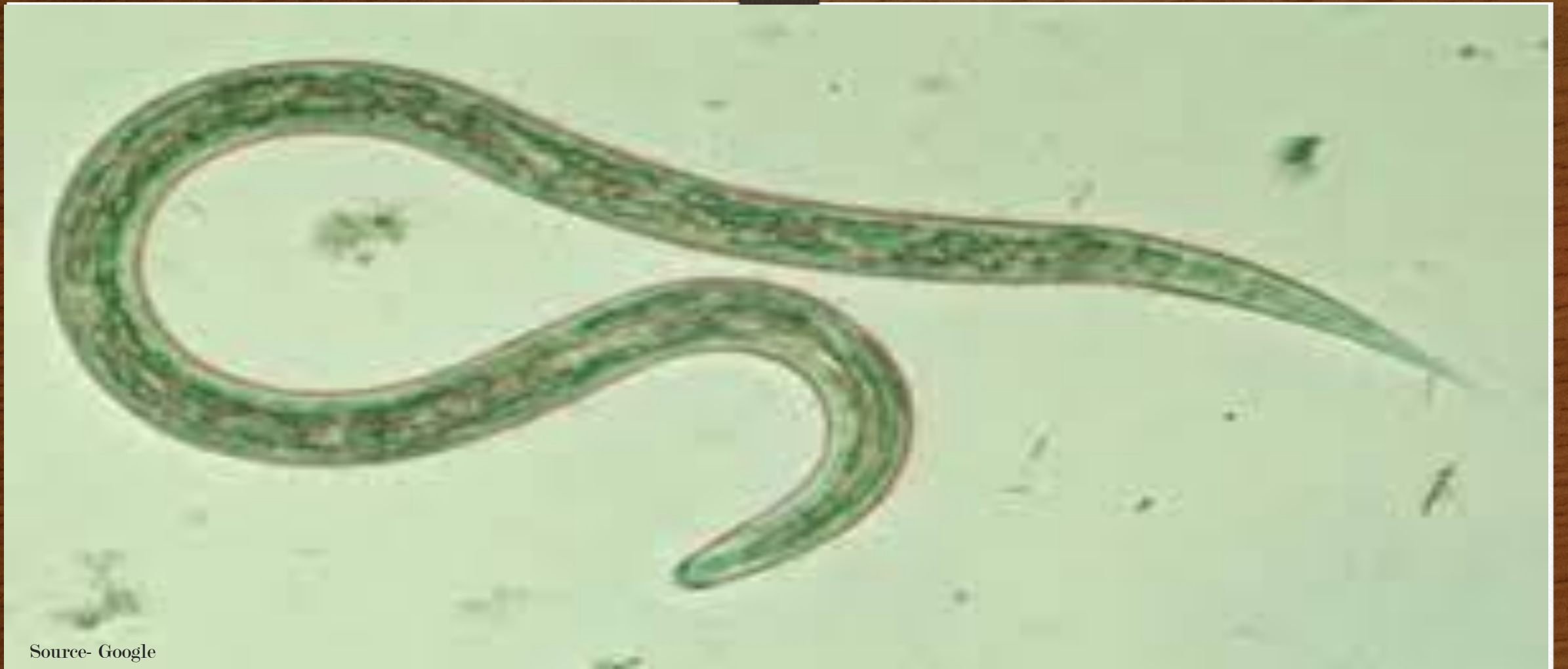Asstt. Professor

Deptt. of Veterinary Parasitology

Bihar veterinary College Patna

Ancylostoma : morphology

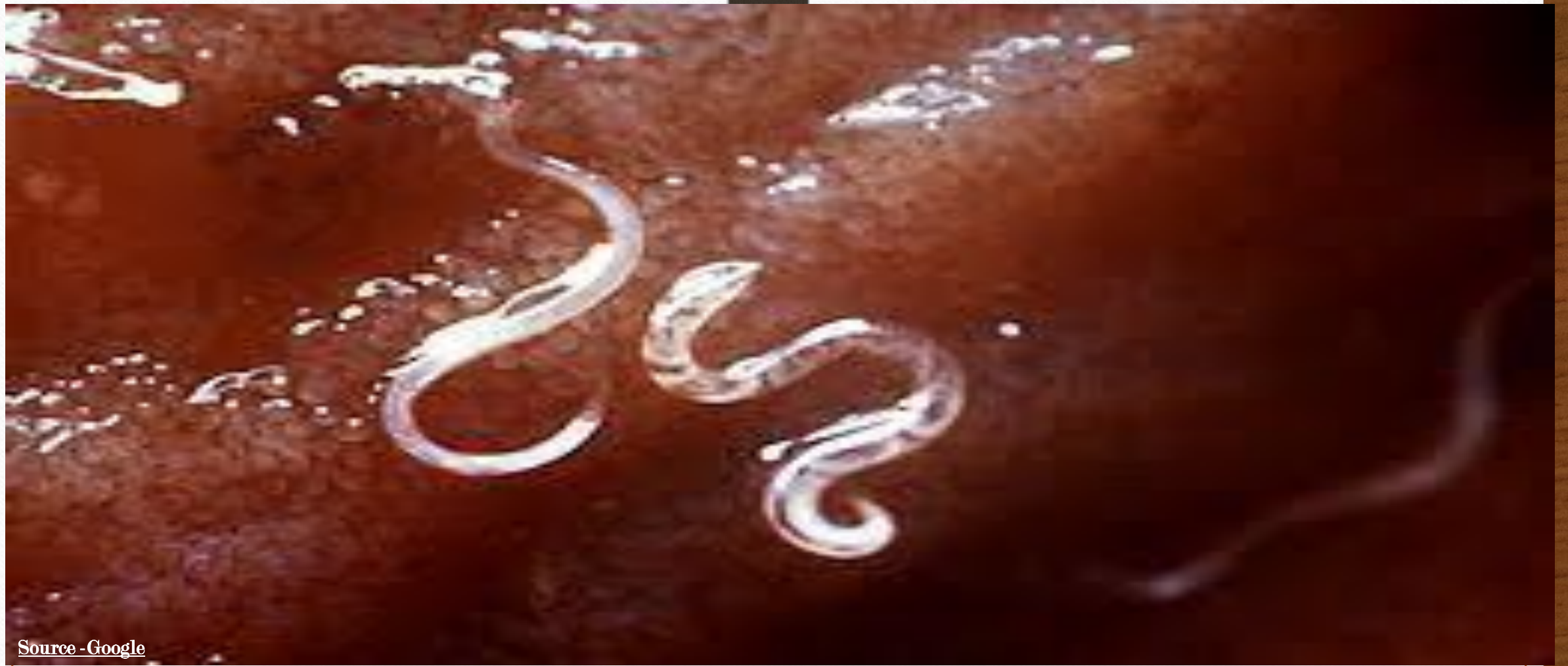- The parasite is commonly known as the Old World hookworm.
- It lives in the small intestine of hosts such as cats and dogs and humans.
- It is small, cylindrical worm, greyish-white in color.
- It has two ventral plates on the anterior margin of the buccal capsule.
- Each of them has two large teeth that are fused at their bases.
- A pair of small teeth can be found in the depths of the buccal capsule.
- Males are 8–11 mm long with a copulatory bursa at the posterior end.
- Females are 10–13 mm long, with the vulva located at the posterior end.



Source- Google

Ancylostoma

Dr. R.K. Sharma



Source - Google

Ancylostoma

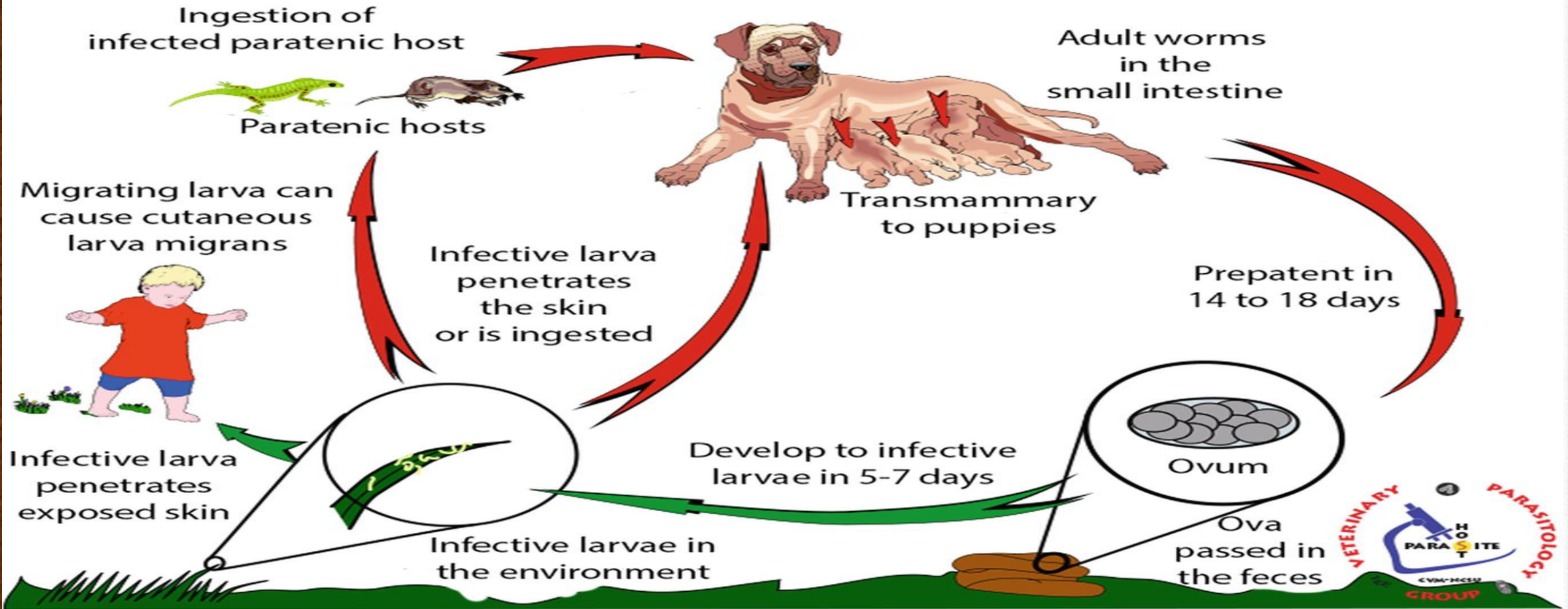
Dr. R.K.Sharma

Ancylostoma : Life cycle

- The infective L3 larva penetrates the skin, most commonly through the feet.
- The larva enters the systemic circulation.
- It is then carried to the lungs, breaks into alveoli, ascends the bronchi and trachea.
- Then coughed up and swallowed back into the small intestine, where it matures.
- The larva later matures into an adult in the small intestine mainly jejunum.

- Where they attach to the villi and female worms can lay massive number of eggs per day.
- These eggs are released into the feces and reside on soil and hatches after 1 to 2 days.
- These larva moults twice and becomes third-stage infective larva within 5–10 days.
- The larvae can then penetrate the exposed skin of another organism and begin a new cycle of infection.

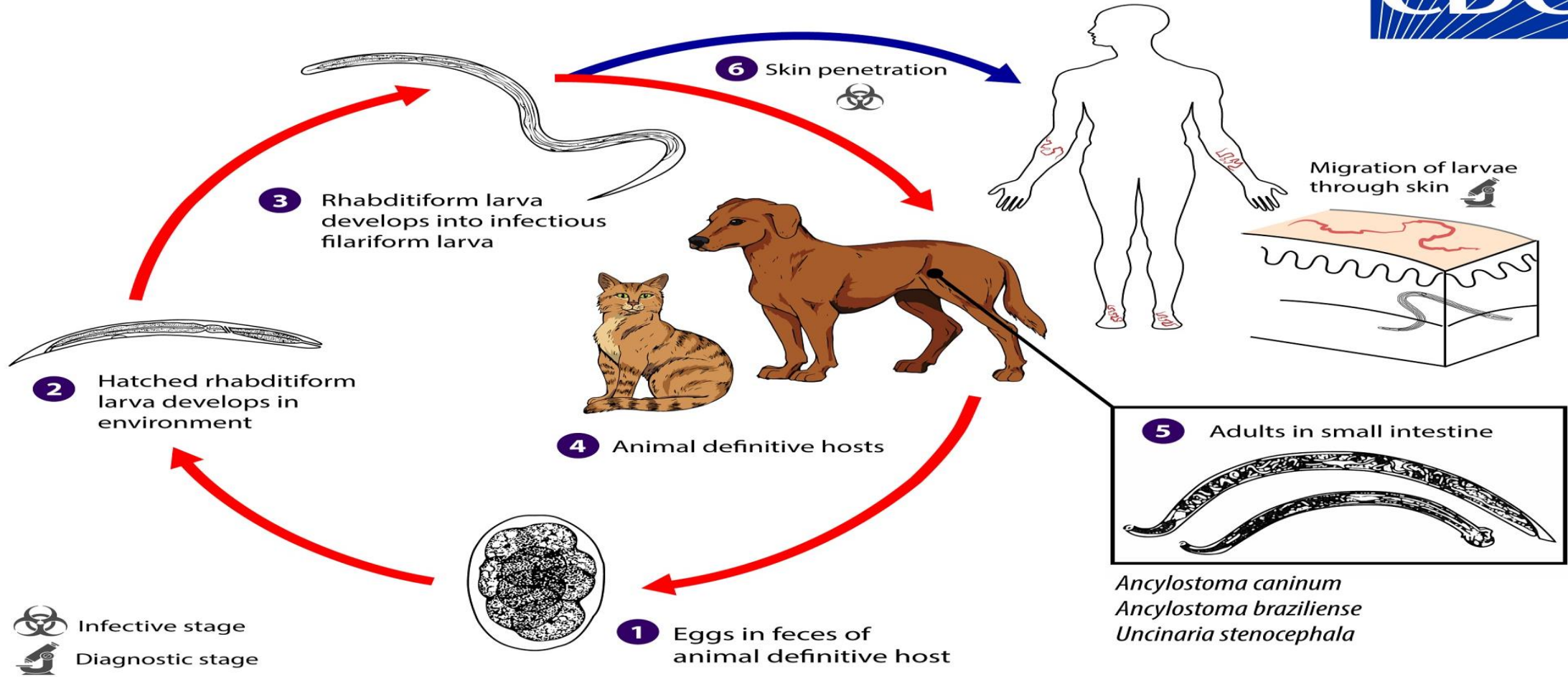
Ancylostoma caninum



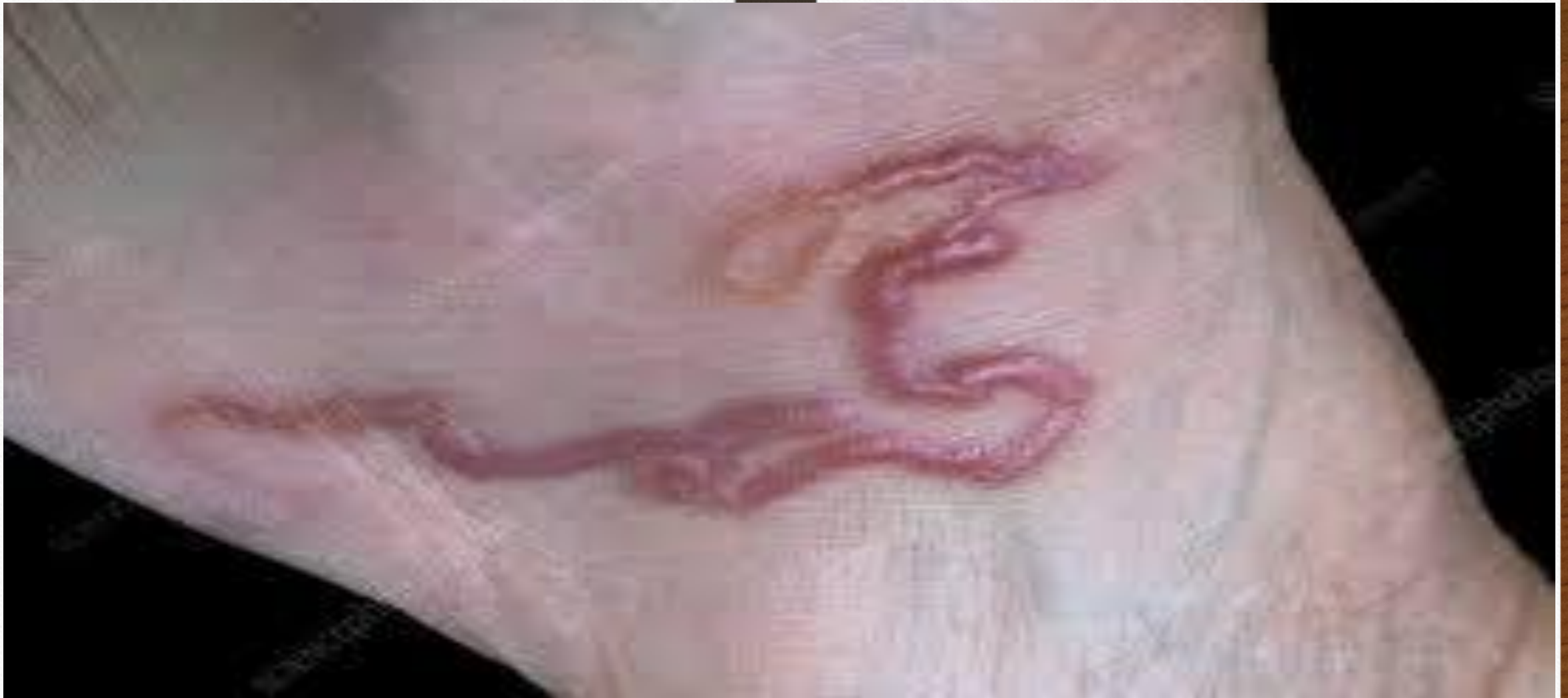Source - Google

Ancylostoma : Life cycle in dog

Dr. R.K.Sharma



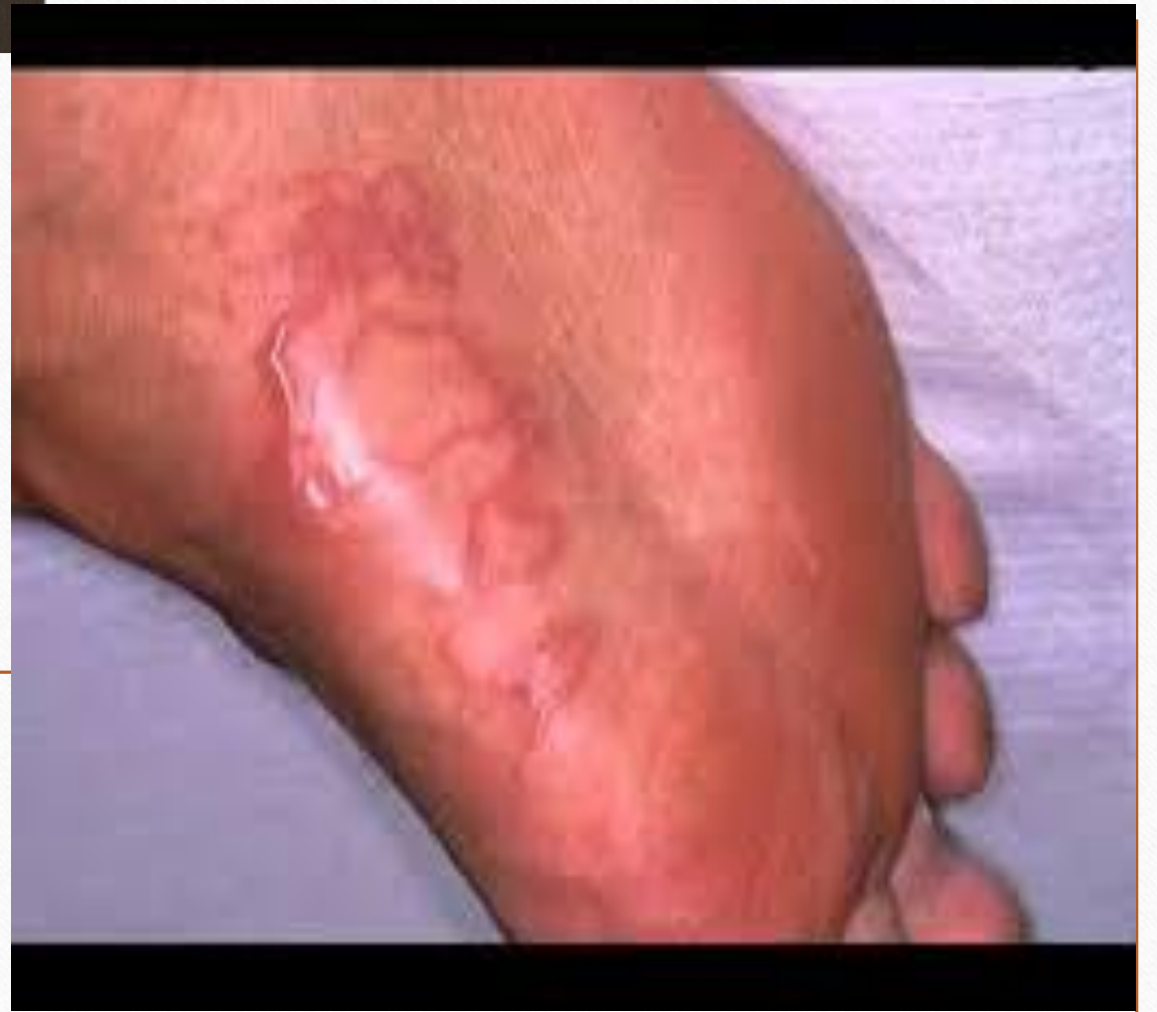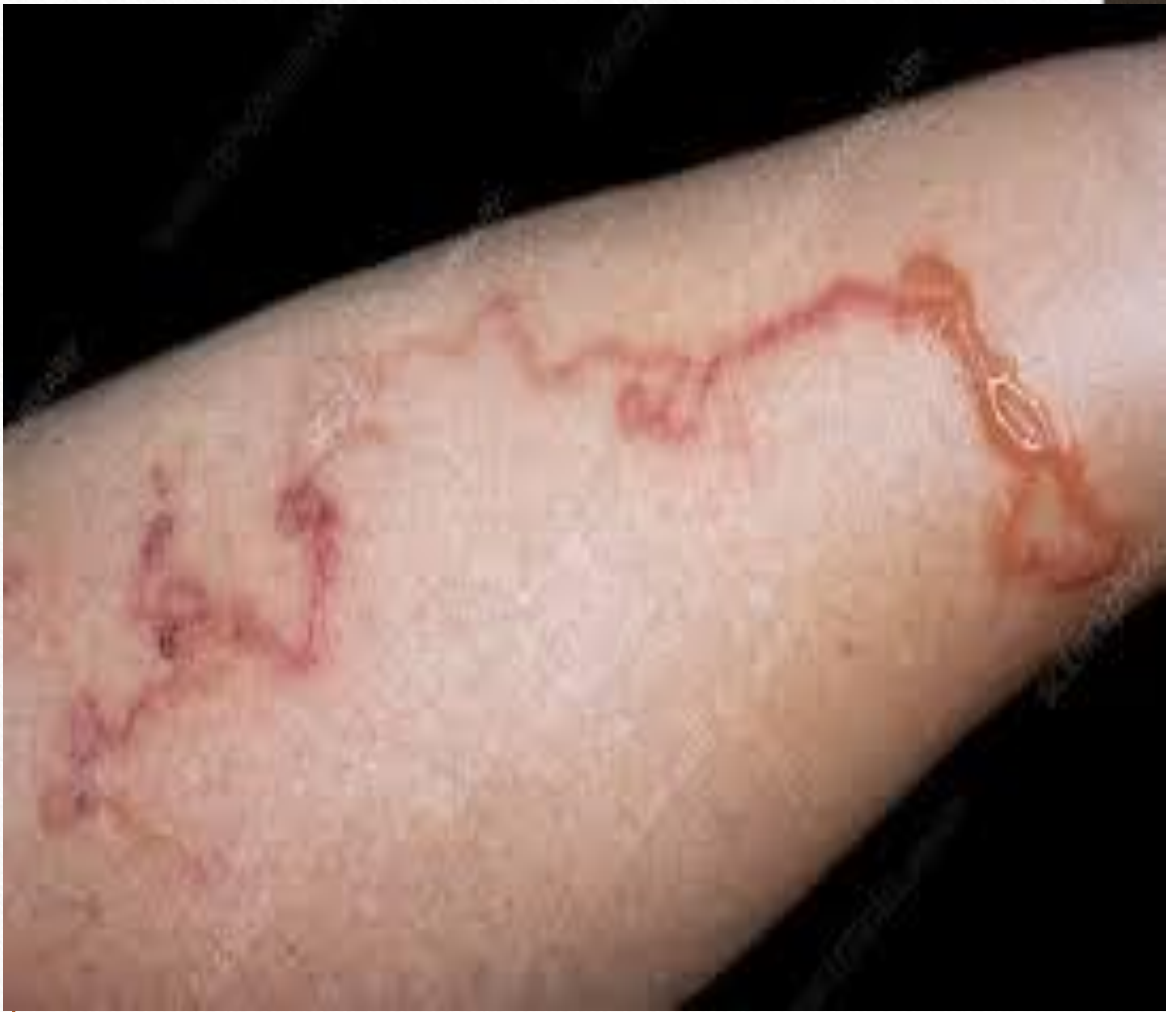Cutaneous Larval Migrans



Source -Google

Cutaneous Larval Migrans

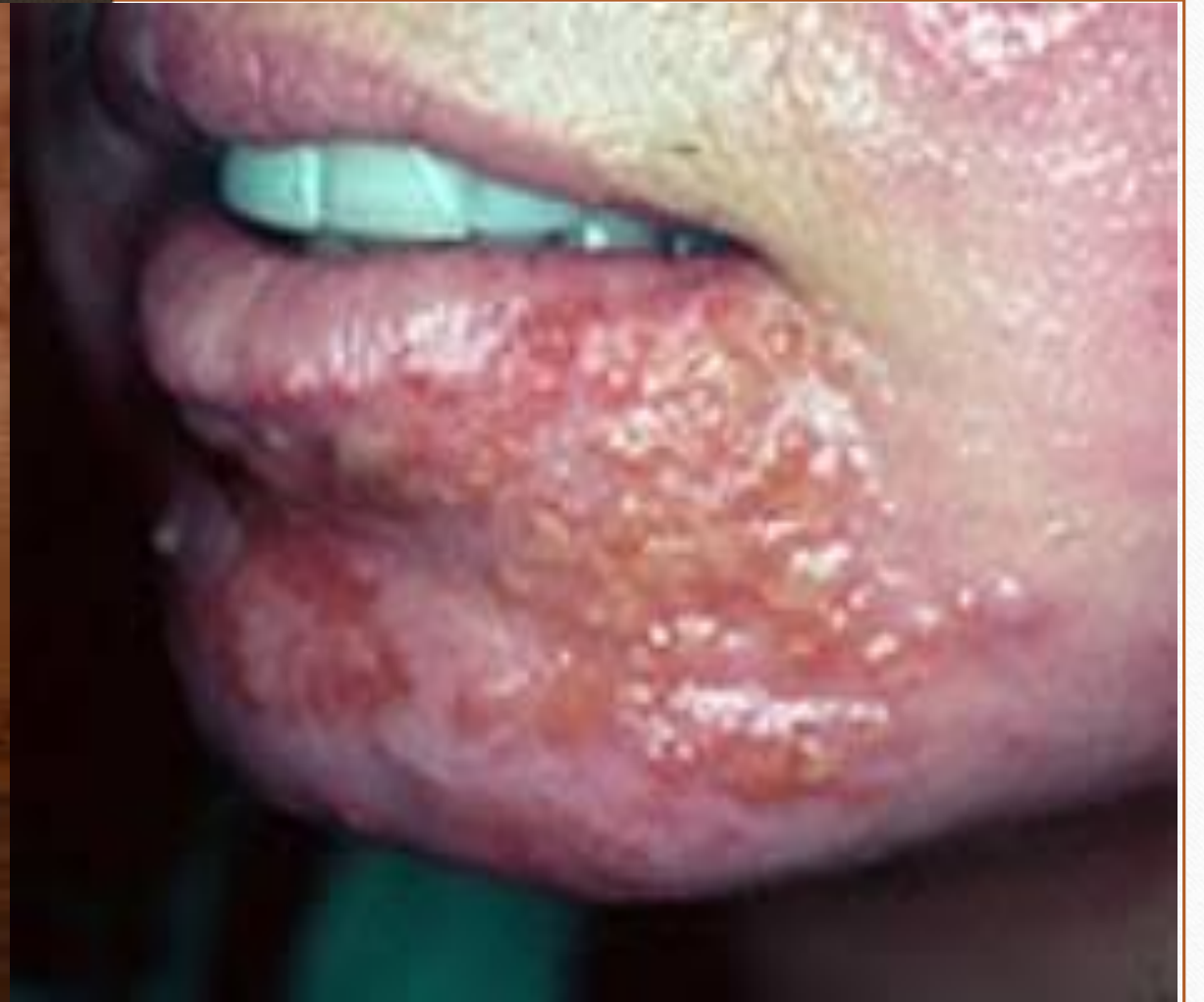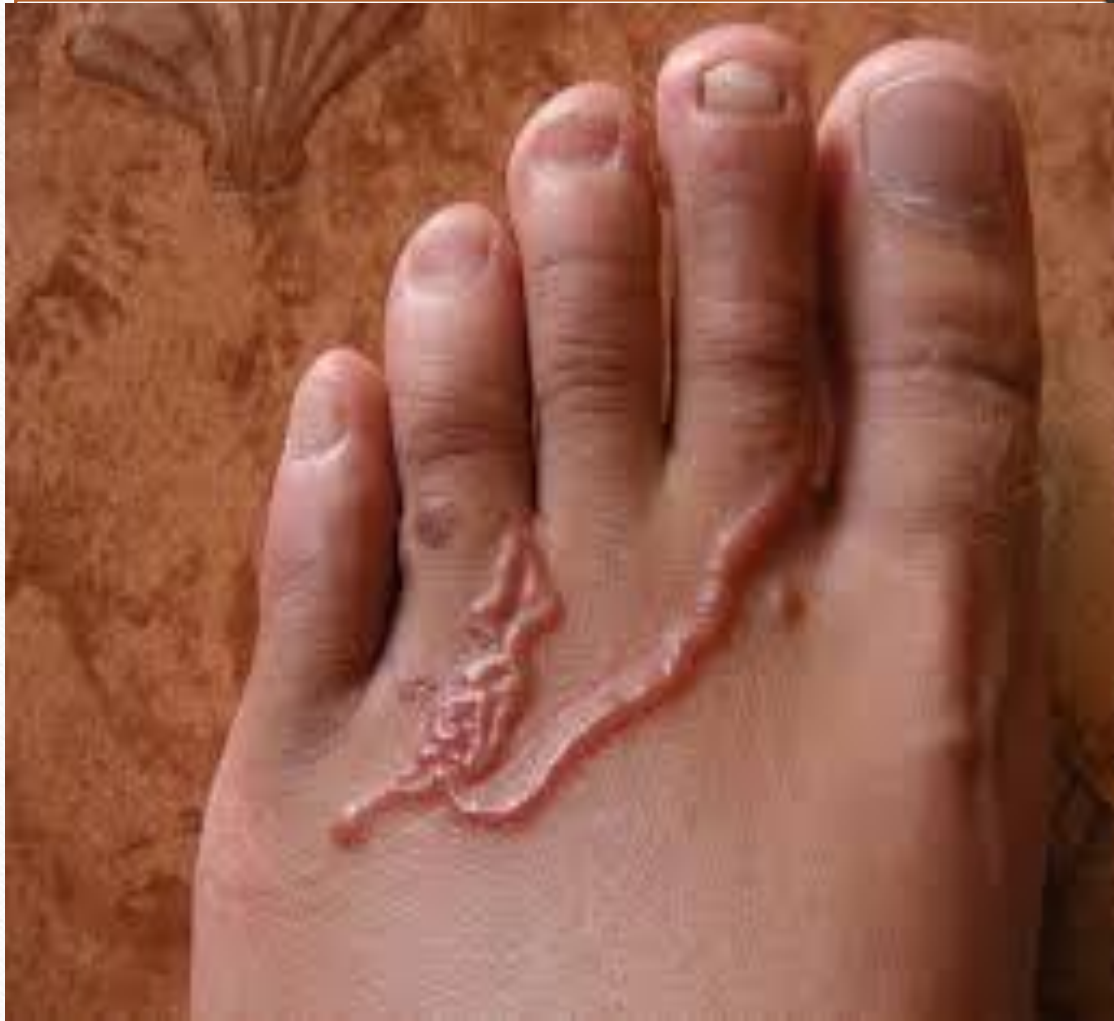Dr. R.K.Sharma



Source -Google

Cutaneous Larval Migrans

Dr. R.K.Sharma



Source -Google

Cutaneous Larval Migrans

Dr. R.K.Sharma

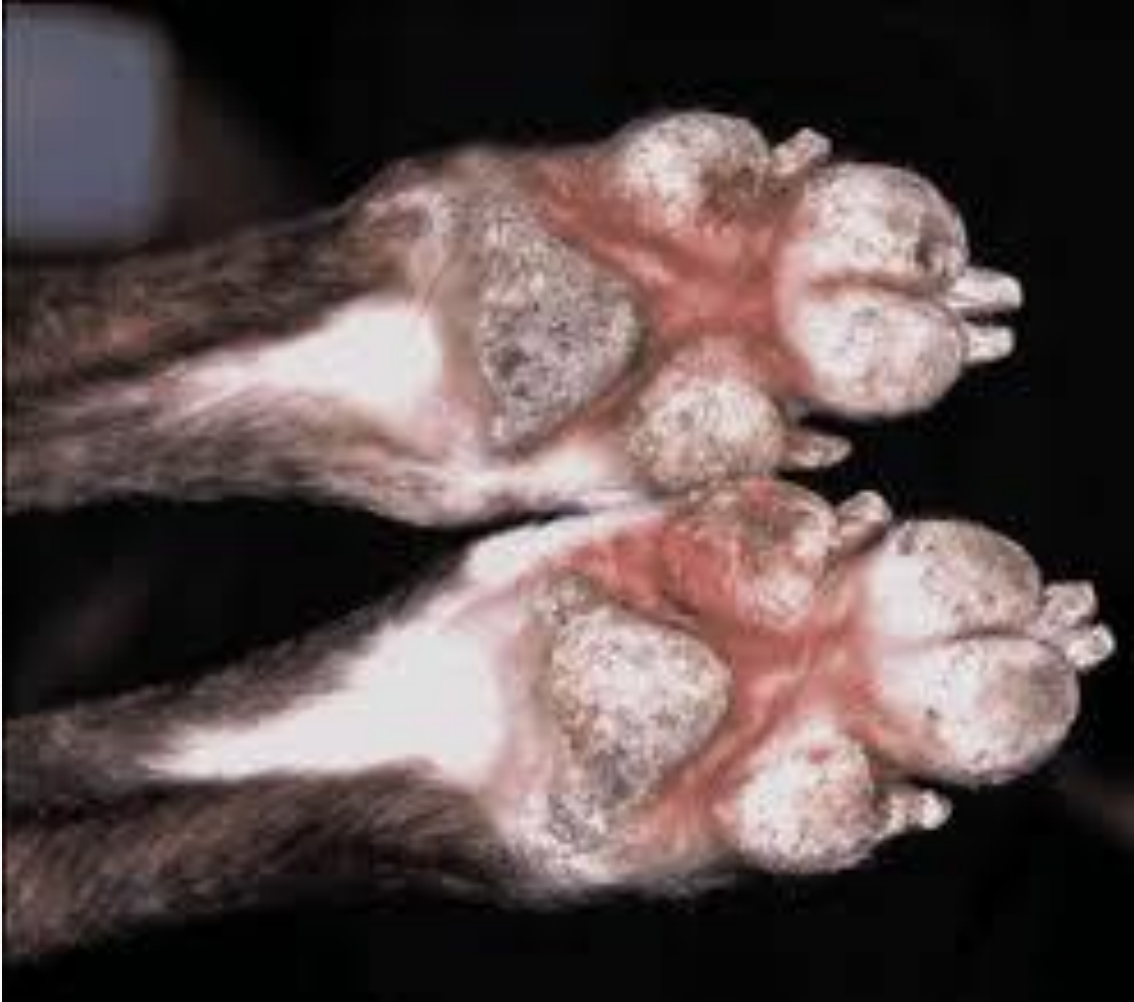Ancylostoma : Clinical signs

- Abdominal pain.
- Colic, or cramping and excessive crying in human infants.
- Intestinal cramps.
- Nausea.

- A fever.
- Blood and mucus in faeces .
- A loss of appetite.
- Itchy rash

Ancylostoma : Pathogenesis

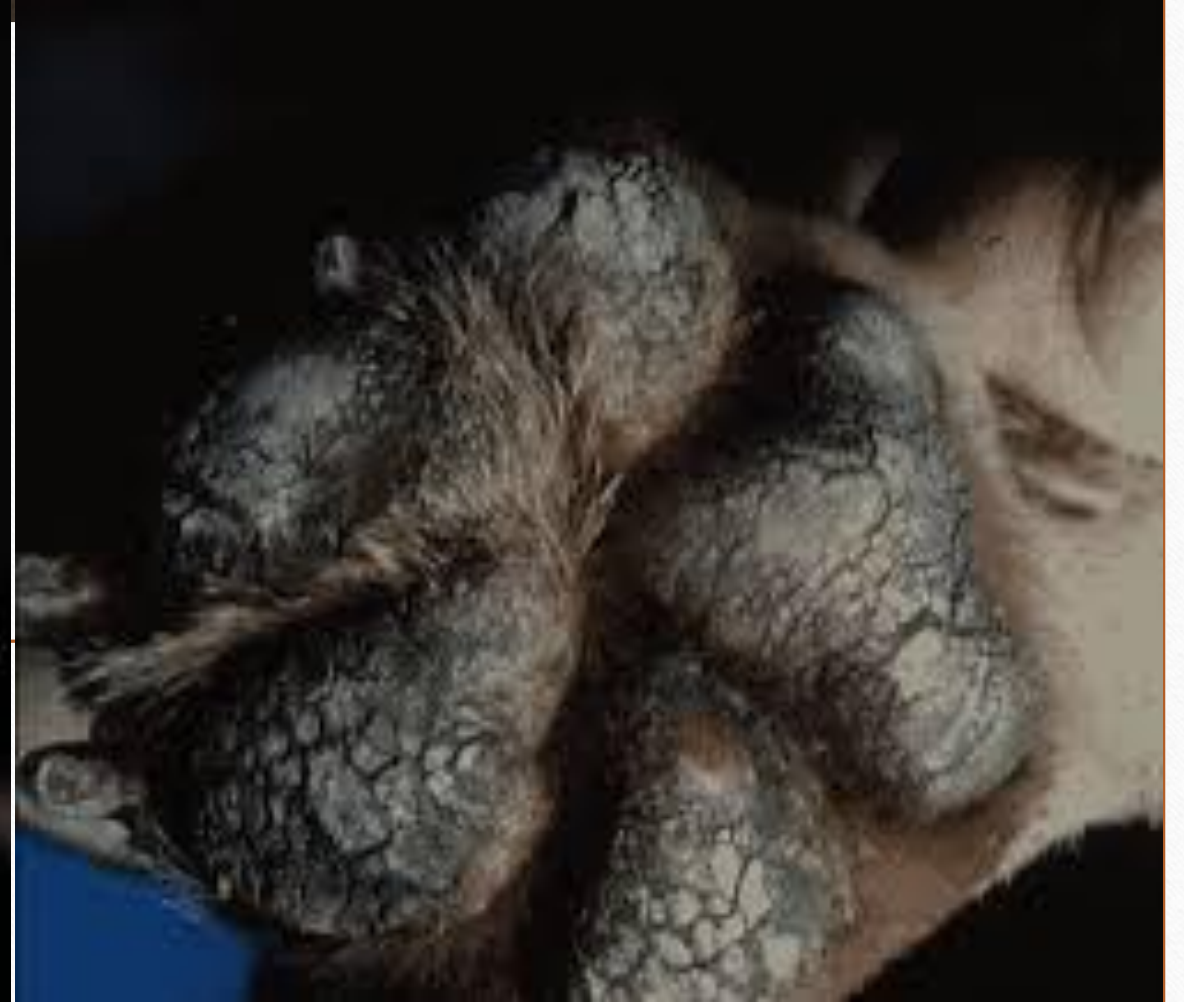- A light infection causes abdominal pain, loss of appetite, and geophagy.
- Heavy infection causes severe protein deficiency or iron-deficiency anemia.
- Protein deficiency may lead to dry skin, edema, and abdominal distension from ~~edema (potbelly)~~. while iron-deficiency anemia might result in mental dullness and heart failure.
- In pregnant women the parasite infect the foetus and can cause complications such as low birth weight, maternal anemia, and infant mortality.
- ~~In severe cases there is anemia.~~

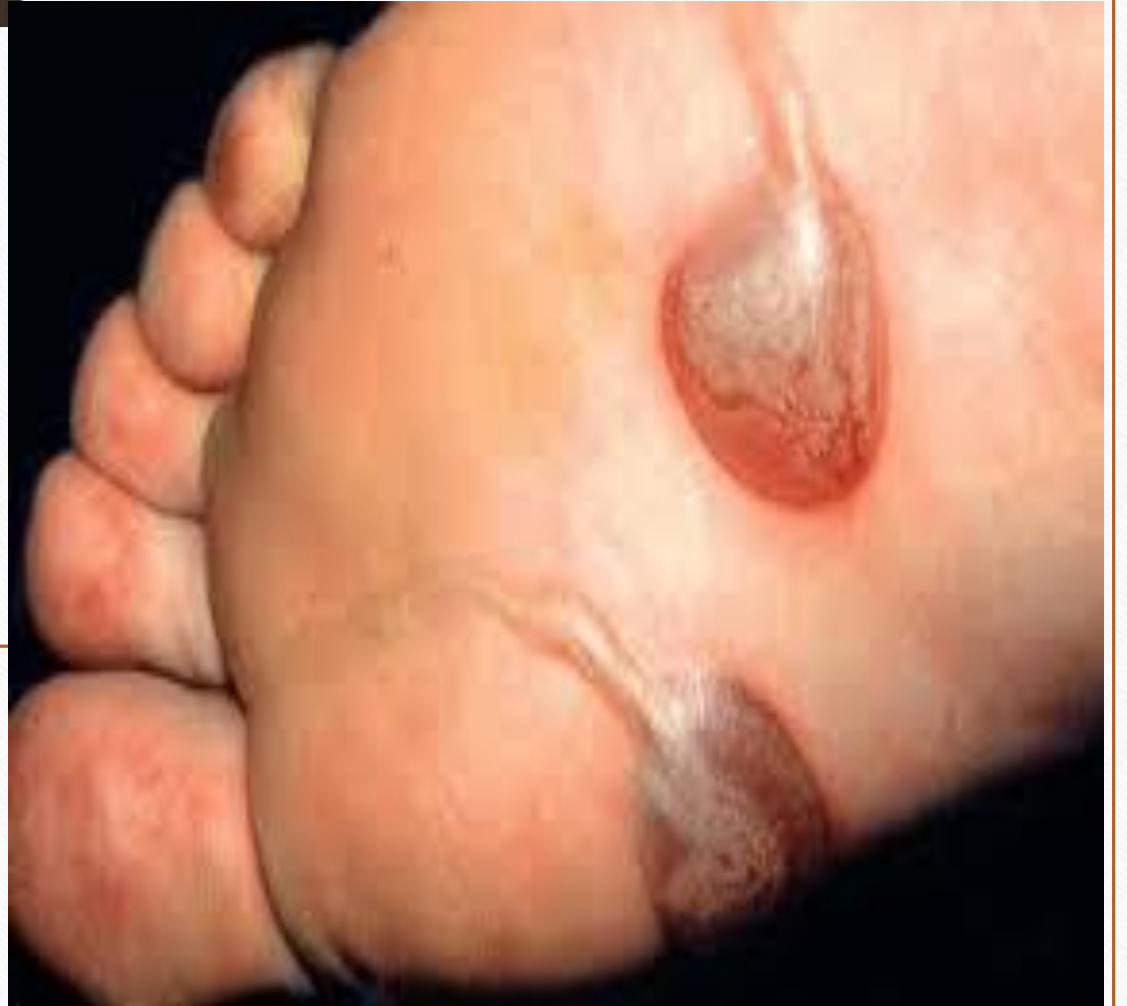
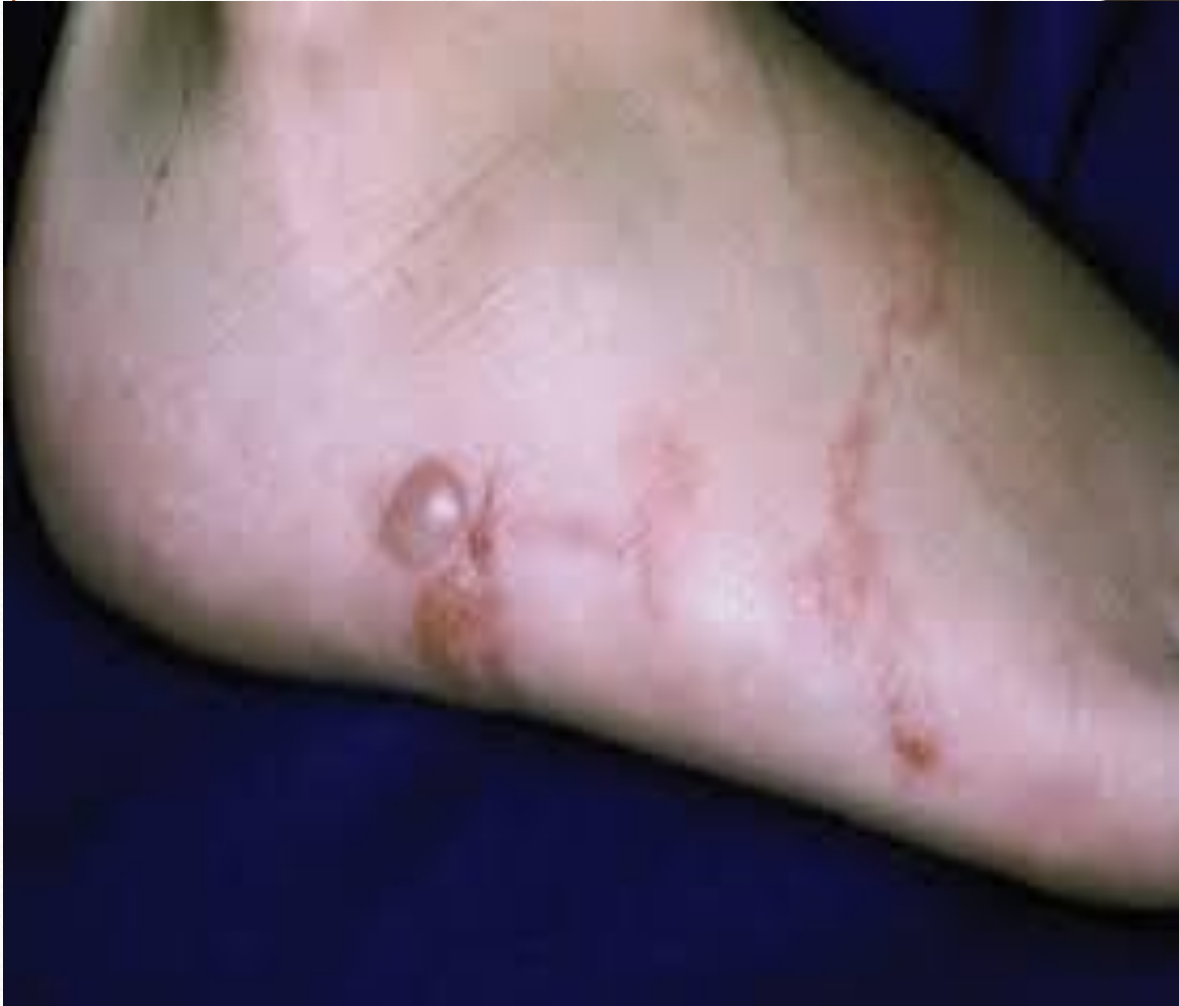
Source -Google

Canine hookworm dermatitis

Dr. R.K.Sharma





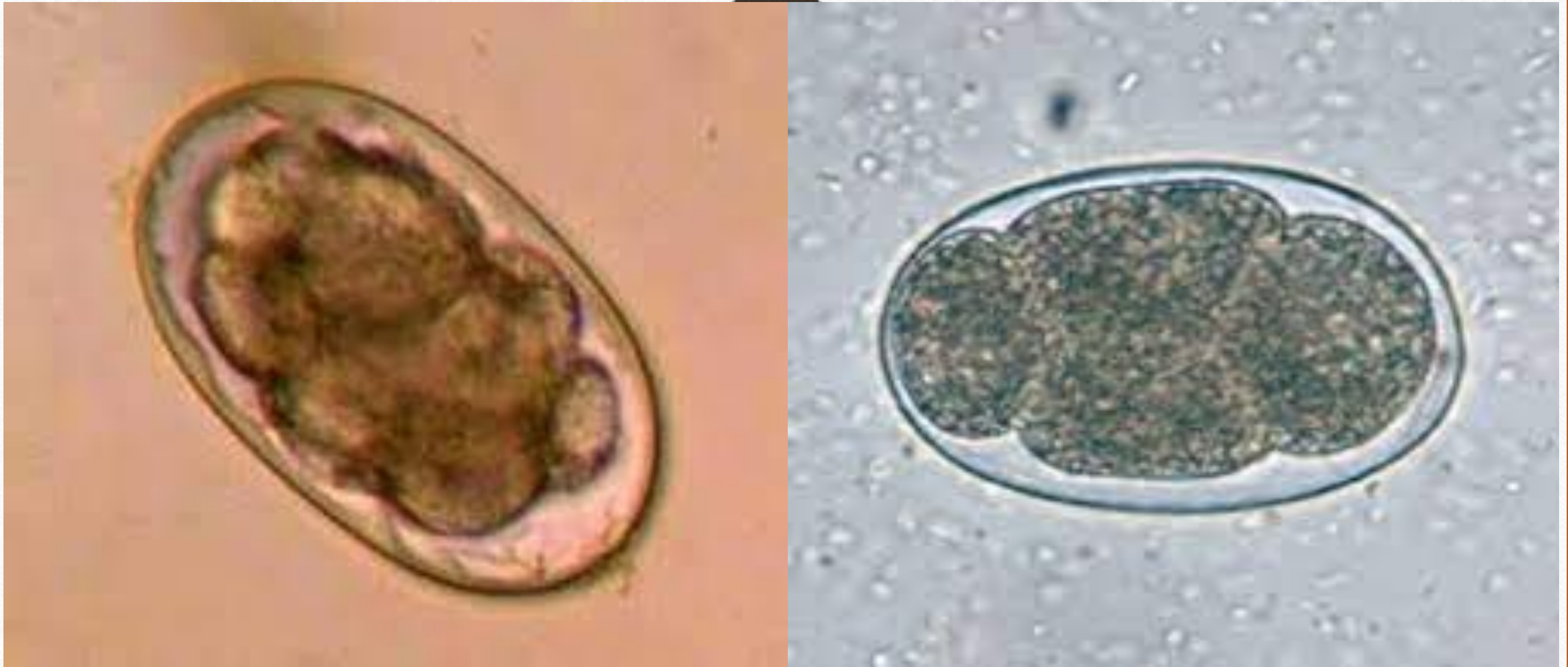C L M in leg region

Source -Google

Dr. R.K.Sharma

Ancylostoma : Diagnosis

- The standard method for diagnosing the presence of hookworm is by identifying hookworm eggs in a faecal sample using a microscope.
- A concentration procedure is recommended, because eggs may be difficult to find in light infections.



Source -Google

Eggs of *Ancylostoma* spp.

Dr. R.K.Sharma

Ancylostoma : Prevention & control

- Education, improved sanitation, and controlled disposal of human feces are important.
- Wearing shoes in endemic areas can reduce the prevalence of infection, and minimize the chance of 'Water itch' or 'Ground itch'.

- *A. duodenale* can be treated with albendazole, mebendazole, and benzimidazoles. Pyrantel pamoate is an alternative.
- In severe cases of anemia, blood transfusion may be necessary.