

**Veterinary Anatomy
(Unit – 1)**

Topic

**Movements of Diarthrodial Joints And Introduction To
Myology**

by

Dr.Nirbhay Kumar Singh

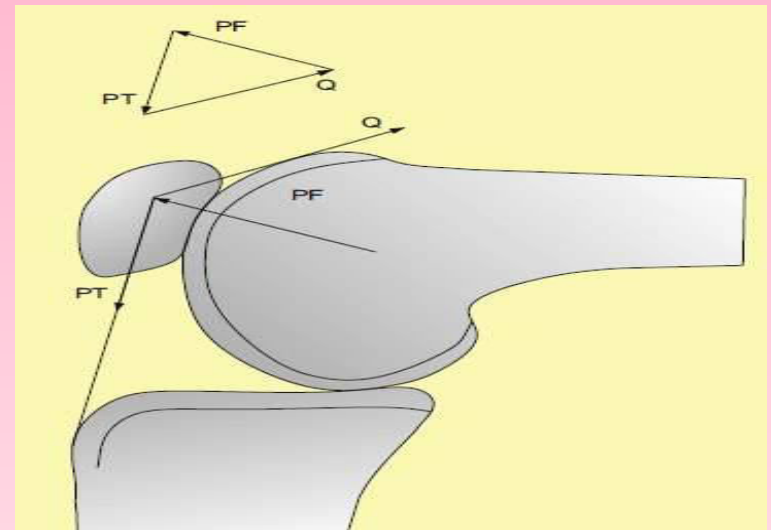
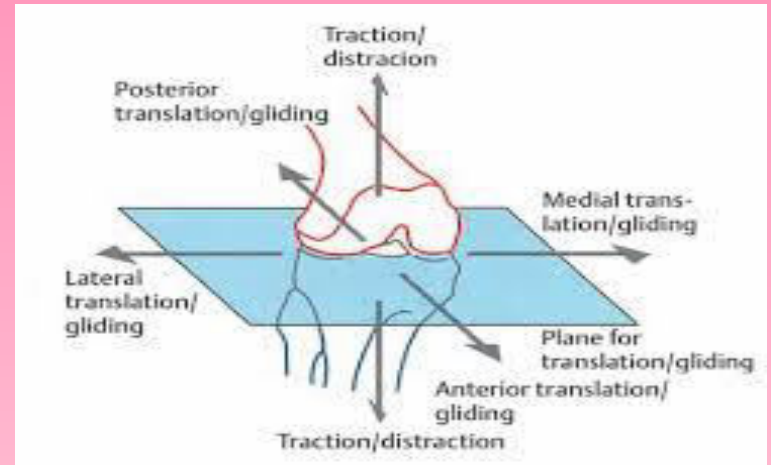
**Assistant Professor
Department of Veterinary Anatomy
Bihar veterinary College Patna
Dated 15/02/2021**

Movements of Synovial Joints

- ❑ **Translation or Gliding**
- ❑ **Angular Movements**
- ❑ **Circumduction**
- ❑ **Rotation**
- ❑ **Uniaxial**
- ❑ **Biaxial**
- ❑ **Multiaxial**

Translation or gliding

When one surface of the bones slides/glides over other surface of the bone eg. Bones involved in the formation of knee joint (Carpometacarpal articulation)



Angular Movement

The angle between the two bones involved in the formation of true joint changes.

Depending upon the angular movement they are classified into

- ❑ Flexion
- ❑ Extension
- ❑ Abduction
- ❑ Adduction

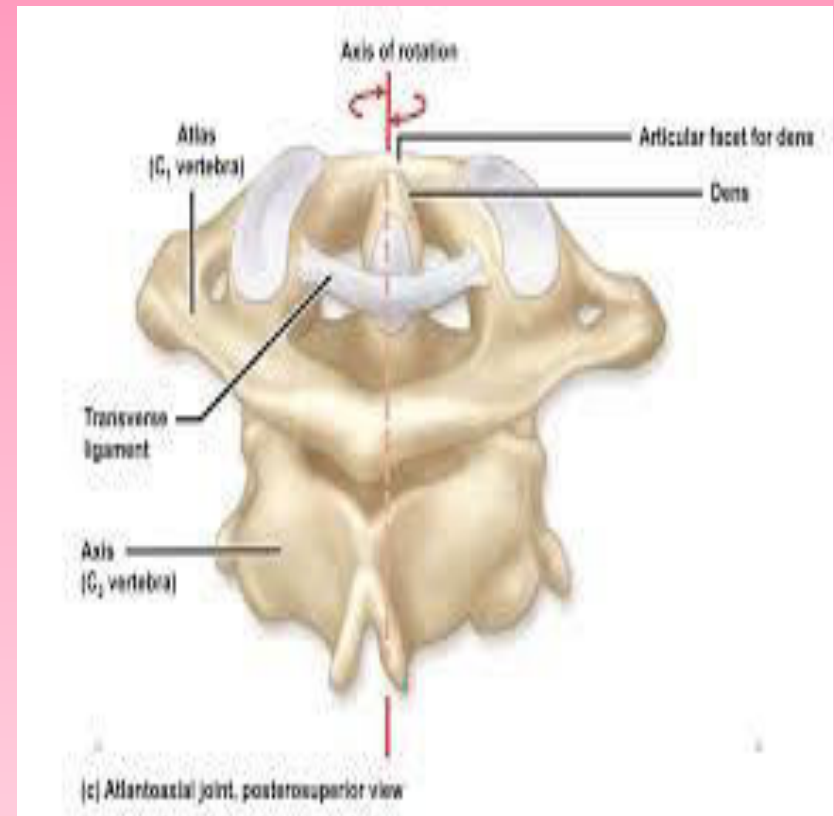
□ **Circumduction**

The distal end of a bone circumscribes a conical space. This type of movement is observed in shoulder of hip joint.



□ Rotation

One bone rotates around the longitudinal axis of other bone. This type of movement is observed in atlanto-axial articulation

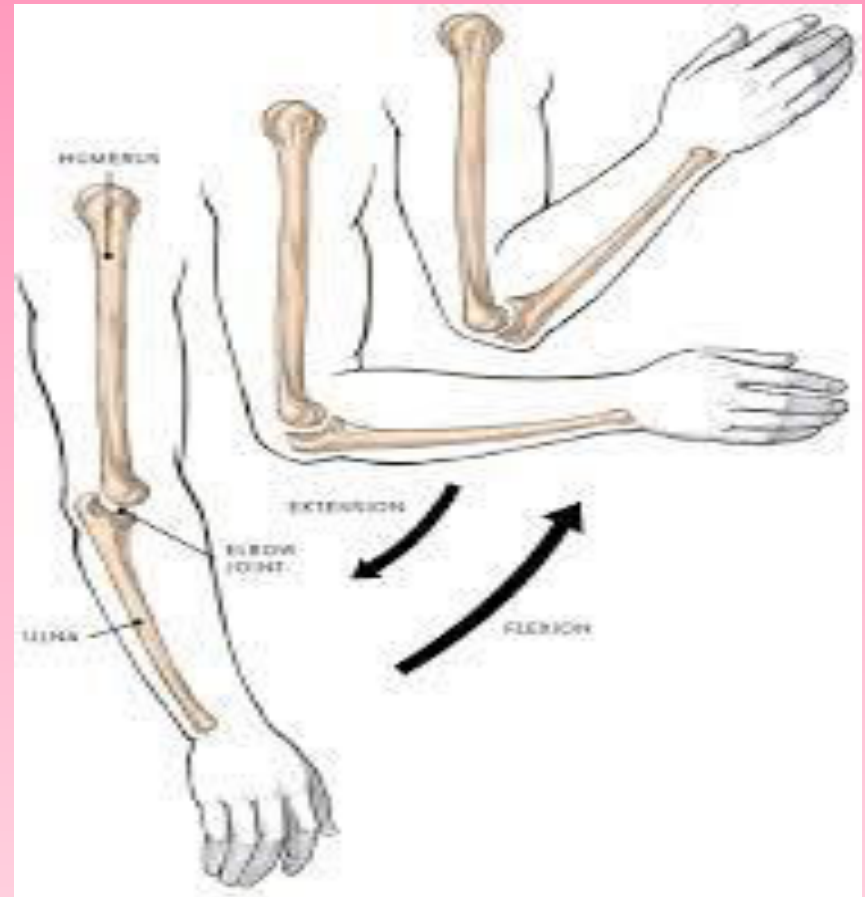


□ Flexion

The angle between the two bones reduces and come close together

□ Extension

The angle between the two bones increases and the segments become straight

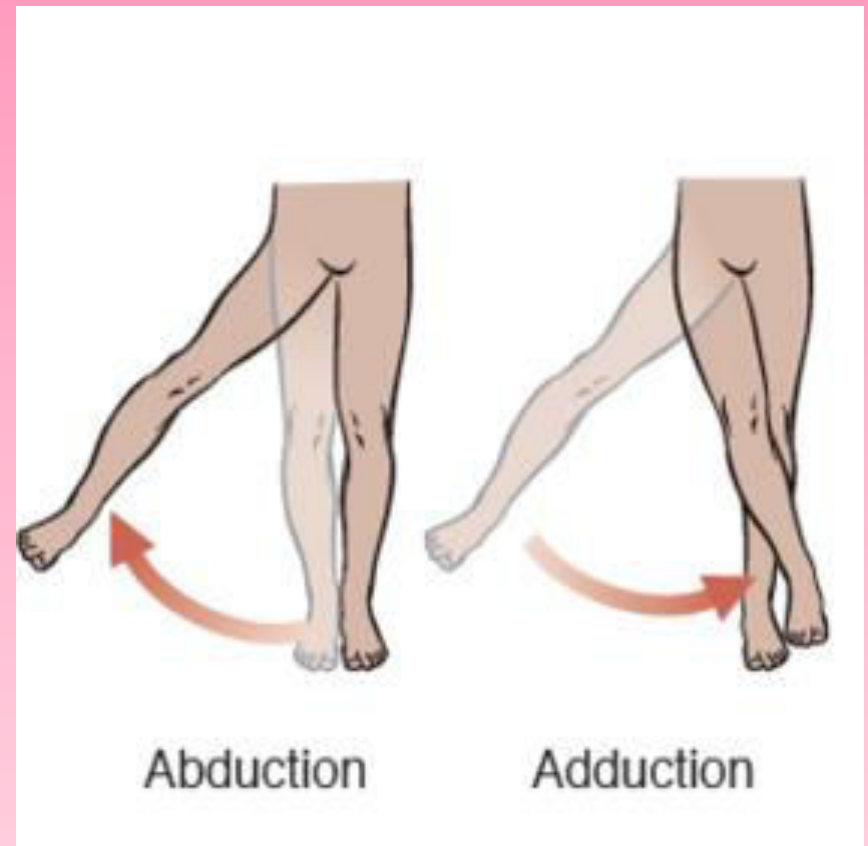


□ Abduction

Movement of bones away from the central axis

□ Adduction

Movement of bones towards the central axis



□ **Uniaxial**

Movement occurs around one axis, hence only one plane is involved eg. Elbow joint

□ **Biaxial**

Movement occurs around two axis that are right angle to each other hence two planes are involved eg. Metacarpophalangeal joint

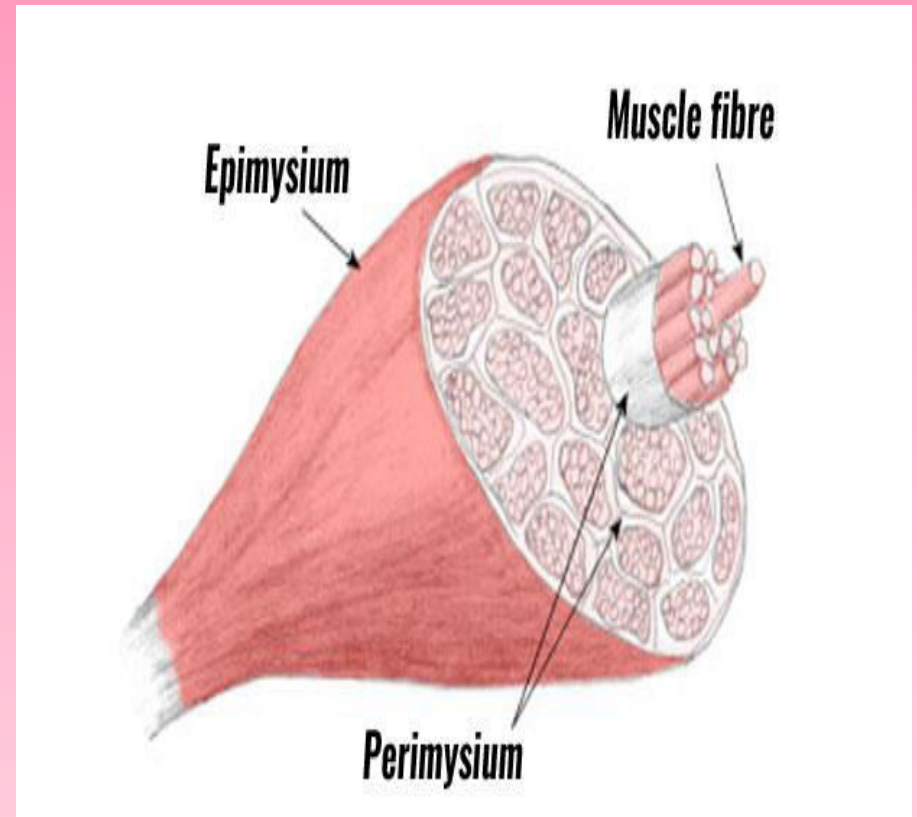
□ **Multiaxial**

Movement occurs around several axis hence more than two planes are involved eg. Hip joint

Introduction to myology

- ❑ **Formed by bundles of muscle cells which are derived from mesenchymal cells and are arranged in form of fibers which contracts on stimulation**
- ❑ **The fibers are grouped into bundles known as fasciculi**
- ❑ **The cytoplasm of the muscle fiber is known as sarcoplasm**
- ❑ **The muscle fibers are covered by a delicate tissue called endomysium**

- ❑ The bundle of muscle fibers are covered by a layer of connective tissue termed perimysium
- ❑ The entire muscle is covered by a layer of connective tissue called epimysium



Three types of muscles

□ Skeletal

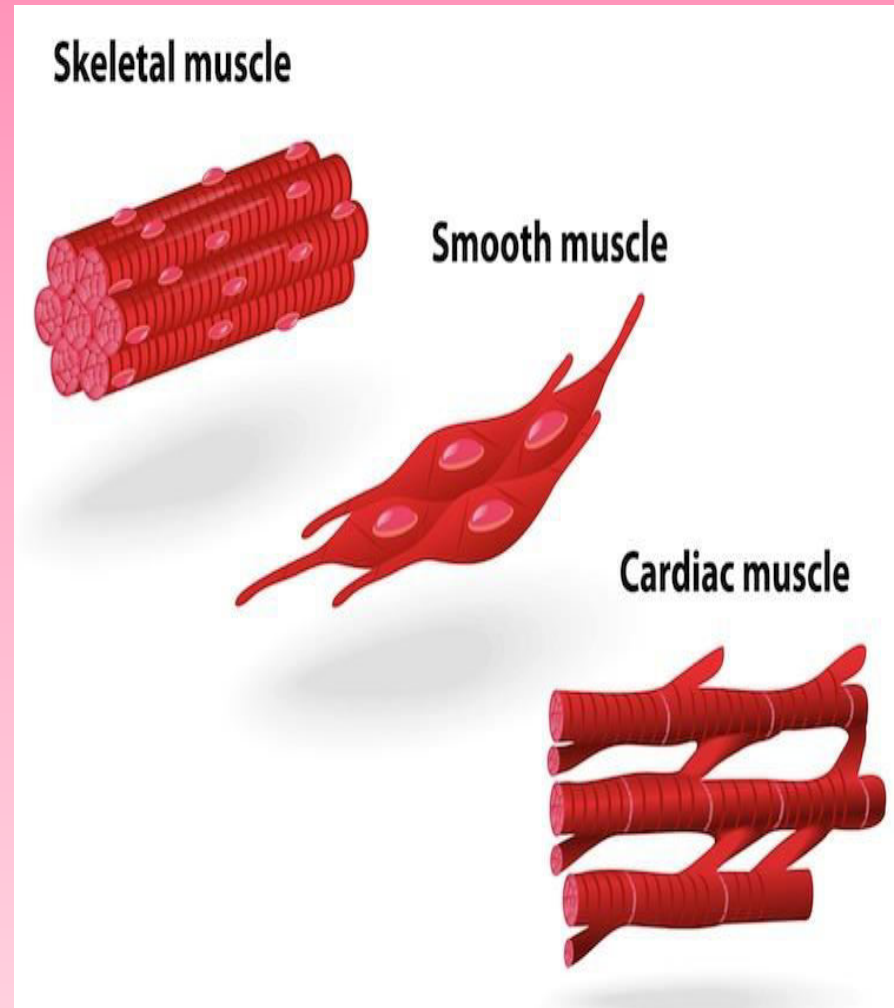
Striated in appearance
and voluntary

□ Smooth

Fusiform or Spindle
Shape with centrally
placed nucleus

□ Cardiac

Centrally placed
nucleus, cross striation
and side branches



Types of voluntary muscle

- ❑ Red muscle
- ❑ White muscle
- ❑ Parallel muscle
- ❑ Pennate muscle
 - Unipennate
 - Bipennate
 - Multipennate

Red muscle

They are red in colour due to large amount of myohaemoglobin and are situated in deeper aspect of the body

White muscle

Less red in colour and contains abundant sarcoplasmic reticulum and are placed superficially

Parallel muscle

Fibers are long and are placed parallel to the line of pull

Pennate muscle

Fibers are short and oblique to the line of pull

Unipennate

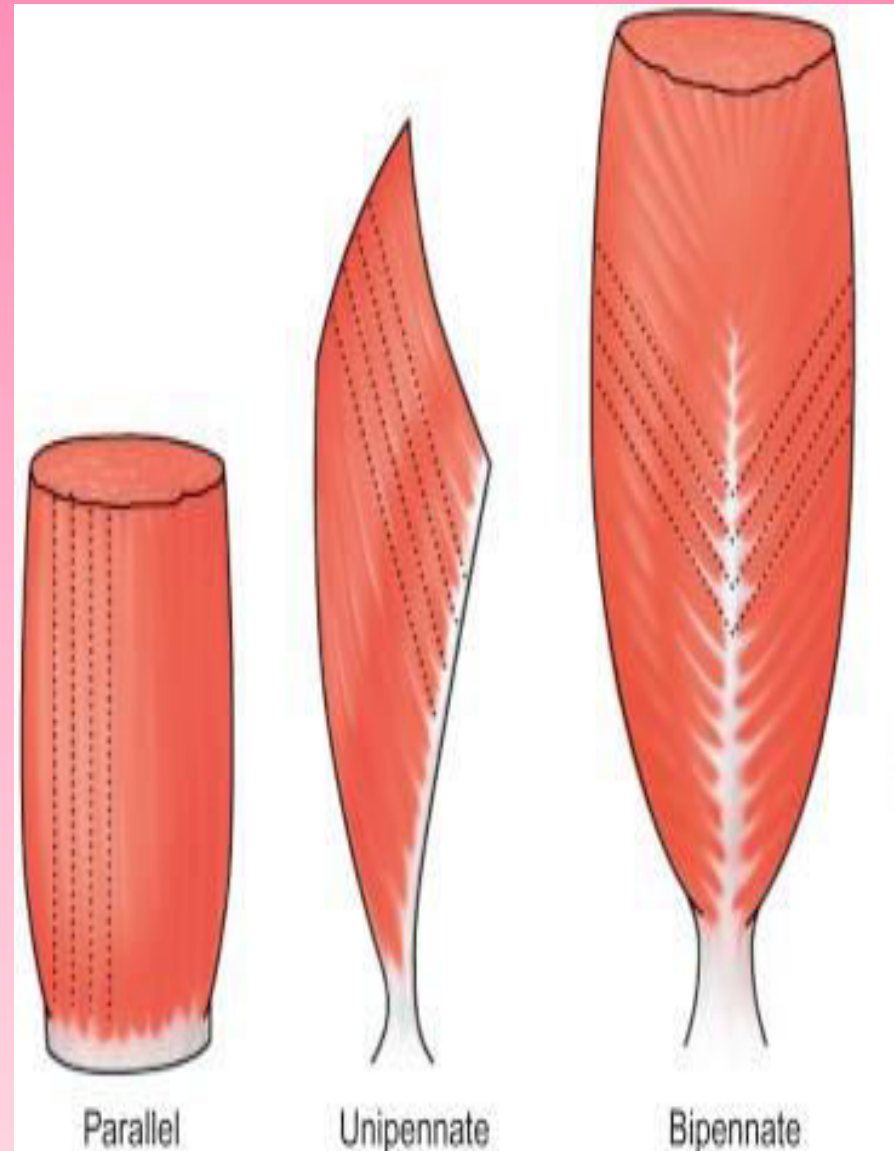
The fibers are directed on one side of the tendon (p.tertius)

Bipennate

The fibers are directed on two sides of the centrally placed tendon (R.femoris)

Multipennate

Formed by a series of bipennate muscle (Deltoid)



Cutaneous muscle

They are striated muscle placed below the skin. They produces twitches in the skin and are attached to the fascia covering the superficial muscle



THANKS